

Diagnosis and Management of a Patient with Wallenberg Syndrome

I Putu Eka Widyadharma¹, Ismail Setyopranoto²

¹Department of Neurology, Udayana University / Sanglah General Hospital, Bali, Indonesia

²Department of Neurology, Universitas Gadjah Mada / Dr. Sardjito Hospital, Yogyakarta, Indonesia

Abstract: *We report an old man who has main complaint suddenly first onset of central type vertigo and imbalance with tendency to fall to left side, hearing loss on left ear, numbness of left face and right side of his body, weakness in the left face, dysphagia with nausea and vomitus, dysphonic, tachycardia and difficulties of breath ness with sudden onset. Physical examination found horizontal nystagmus, ptosis and miosis in left eye (Horner syndrome), tachycardia and dyspnea, multicranial nerve palsies in left side, thermanesthesia in right side of body. From all examination, this patient diagnosed as Wallenberg Syndrome. With a proper conservative treatment, patient was discharged from hospital with minimum disabilities*

Keywords: vertigo, stroke, horner syndrome, wallenberg syndrome

1. Introduction

Stroke is a clinical syndrome defined by acute neurologic deficits in the setting of focal disruption of the cerebral circulation. There are a number of subtypes, including arterothrombotic, cardioembolic, lacunar and hemorrhagic strokes. Rather than representing diagnostic closure, a stroke should prompt the search for an etiologic explanation. [1] Stroke was defined as rapidly developing clinical symptoms and/or sign of focal and sometime loss of cerebral function with the symptom lasting more than 24 hours or leading to death with no apparent cause other than that of vascular. [2]

The vertebrobasilar arterial system perfuse the medulla, cerebellum, pons, midbrain, thalamus, and occipital cortex. Occlusion of large vessels in this system usually leads to major disability or death; however, many lesions arise from small vessel disease and are correspondingly small and discrete. The clinical correlates of these smaller lesions consist of a variety of focal neurological deficits, depending on their location within the brainstem. [3]

In the territory of the basilar artery, the signs of infarction are frequently bilateral and occur in conjunction with cranial nerve palsies and other segmental brainstem and cerebellar signs; quadriplegia, hemiparesis, and/or unilateral or bilateral sensory impairment are typical, coupled with diplopia, dysarthria, and vertigo in various combinations.[4]

A characteristic feature of medullary lesions is the occurrence, in many instances, of a crossed sensory disturbance, i.e., a loss of pain and temperature sensation on one side of the face and on the opposite side of the body. This is accounted for by involvement of the descending trigeminal tract or its nucleus and the crossed lateral spinothalamic tract on one side of the brainstem and is nearly always caused by a lateral medullary infarction (Wallenberg syndrome). In the upper medulla, pons, and midbrain, the crossed trigeminothalamic and lateral spinothalamic tracts run together; a lesion at these levels causes loss of pain and temperature sense on the opposite half of the face and body.

There are no tactile paresthesias, only thermal or painful dysesthesias. In the upper brainstem, the spinothalamic tract and the medial lemniscus become confluent, so that an appropriately placed lesion causes a contralateral loss of all superficial and deep sensation. Cranial nerve palsies, cerebellar ataxia, and motor paralysis are almost invariably associated, as indicated in the discussion of strokes in this region. In other words, a lesion in the brainstem at any level is unlikely to cause an isolated sensory disturbance.[4]

2. Case

A 75- year old man had the main complaint suddenly first onset of central type vertigo and imbalance with tendency to fall to left side, hearing loss on left ear, numbness of left face and right side of his body, weakness in the left face, dysphagia with nausea and vomitus, dysphonic, tachycardia and difficulties of breath ness with sudden onset. The complaint occurred when he was not doing any activity. The symptom was not accompanied by headache and seizure. There is no decrease of consciousness. No preceding history of infection, head injury, used medication for long time or malignancy was found. Patient had a history of uncontrolled hypertension.

Result of anamnesis there were central type vertigo, Ataxia with tendency to fall to left side, tachycardia and difficulties of breath ness, hearing loss of left ear, numbness of left face and right side of his body, weakness in the left face, dysphagia with nausea and vomitus, dysphonia with sudden onset.

From physical examination, general condition: weak with normal nutrition, consciousness: compos mentis (GCS:E₄,V₅,M₆), blood pressure: 140/100 mm Hg, pulse: 112 times/minute regular, respiratory rate: 32 times/minute, temperature: not febril. pupil: unisocor, diameter 4mm/2mm. Found horizontal nystagmus, ptosis and miosis in left eye (Horner syndrome), tachycardia and dyspnea, multicranial nerve palsies in left side, thermanesthesia in right side of body.

Volume 6 Issue 4, April 2017

www.ijsr.net

Licensed Under Creative Commons Attribution CC BY

Vegetatif Function : Within normal limit
 ROMBERG TEST : (+) TENDENCY TO FALL TO LEFT SIDE
 TENDEM GAIT : (+) TENDENCY TO FALL TO LEFT SIDE
 Dismetri : (+) on left side
 Disdiadokokinesia : (+) on left side

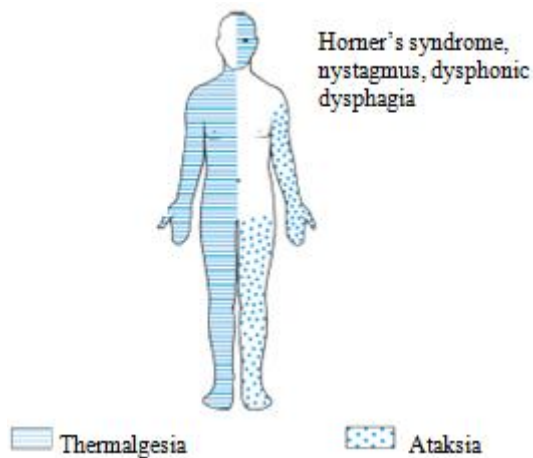


Figure 1: Resume of physical examination (modified from 5)

From Laboratory examination (Blood routine, liver function test, blood sugar, renal function test, electrolyte, uric acid and lipid profile) there are within normal limit. Result of chest X ray showed there was a cardiomegaly, and consulting to the cardiology department there was a Hypertensive Heart Disease. Result of direct laryngoscopy showed there was no mass on oropharynx or larynx.

The result of Head CT scan examination was bilateral calcification of basal ganglia. There is no infarct or bleeding in head CT scan (Figure 2).

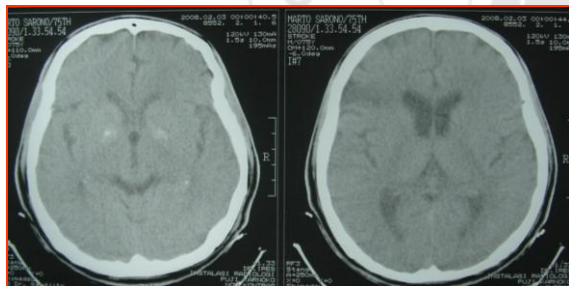


Figure 2: Head CT Scan result

From Brain Evoked Respon Auditory (BERA) examination found block conduction of 8th nerve tract in left pons, congruent with hemilesia of left side brainstem.

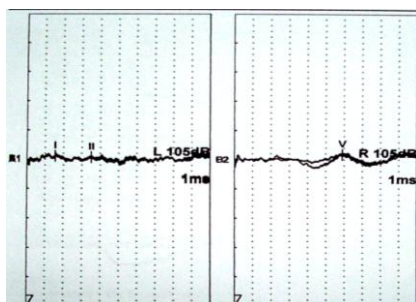


Figure 3: BERA Result

3. Discussion

Result of anamnesis there were central type vertigo, Ataxia with tendency to fall to left side, tachycardia and difficulties of breath ness, hearing loss of left ear, numbness of left face and right side of his body, weakness in the left face, dysphagia with nausea and vomitus, dysphonia with sudden onset. From physical examination, found horizontal nystagmus, ptosis and miosis in left eye (Horner syndrome), tachycardia and dyspnea, multicranial nerve palsies in left side, thermanesthesia in right side of body. Patient has hypertension.

Result of chest X ray showed there was a cardiomegaly, and consulting to the cardiology department there was a Hypertensive Heart Disease. The result of Head CT scan examination was within normal limit. Result of direct laryngoscopy showed there was no mass on oropharynx or larynx. From BERA examination found block conduction of 8th nerve tract in left pons, congruent with hemilesia of left side brainstem.

Based on this result the final diagnosis was vertebrobasilar stroke, and the type of pathology was ischemic caused by Atherothrombotic. From a population-based study, patients >44 years of age presenting with dizziness symptom (DS) to the emergency department, Stroke/TIA was diagnosed in 3.2% (53 of 1666) of all patients with DS. Only 0.7% (9 of 1297) of those with isolated DS had a stroke/TIA. Patients with stroke/TIA were slightly older than those without stroke/TIA. Male gender was associated with stroke/TIA, whereas isolated DS was negatively associated with stroke/TIA. Patients with imbalance (dizziness as referent) were more likely to have stroke/TIA. The proportion of cerebrovascular events in patients presenting with dizziness, vertigo, or imbalance is very low. Isolated dizziness, vertigo, or imbalance strongly predicts a noncerebrovascular cause. The symptom of imbalance is a predictor of stroke/TIA. [6]

Lesions in the vertebrobasilar system have some characteristic clinical features that distinguish them from lesions in the hemispheres. When cranial nerves or their nuclei are involved, the corresponding clinical signs are ipsilateral to the lesion and the corticospinal signs are crossed, involving the opposite arm and leg. Cerebellar signs (eg, dysmetria, ataxia) are frequent. Involvement of the ascending sensory pathways may affect the spinothalamic pathway or the medial lemniscus (dorsal columns), resulting in a condition referred to as dissociated sensory loss. This condition occurs when there is loss of one sensory modality on one side and preservation of other sensory modalities in the opposite limbs. Dysarthria and dysphagia typically are present. Vertigo, nausea, and vomiting, along with nystagmus, represent involvement of the vestibular system. Additionally, unilateral Horner syndrome occurs with brainstem lesions. Occipital lobe lesions result in visual field loss or visuospatial deficits. In contrast to hemispheric lesions, cortical deficits, such as aphasia and cognitive impairments, are absent.[3]

Lateral medullary (Wallenberg) syndrome most often, this syndrome is due to vertebral artery occlusion or, less commonly, to Postero Inferior Cerebellar Artery (PICA) occlusion. Patients present with nausea, vomiting, and vertigo from involvement of the vestibular system. Ipsilateral clinical features include ataxia and dysmetria, due to damage of the inferior cerebellar peduncle and cerebellum; Horner syndrome (eg, ptosis, miosis, hypohidrosis or anhidrosis, enophthalmos), due to the damage to descending sympathetic fibers; facial pain and temperature loss; reduced corneal reflex from damage to the descending spinal tract and nucleus of 5th cranial nerve; nystagmus; hypoacusis (cochlear nucleus); dysarthria; dysphagia; paralysis of the pharynx, palate, and vocal cord; and loss of taste from the posterior third of the tongue (nuclei or fibers of 9th and 10th cranial nerve). Contralateral findings include the loss of pain and temperature sense in the body and extremities, indicating involvement of the anterior spinothalamic tract. Other findings include tachycardia and dyspnea (dorsal nucleus of 10th cranial nerve), and palatal myoclonus, a rhythmic involuntary jerking movement of the soft palate, pharyngeal muscles, and diaphragm. Palatal myoclonus sometimes follows infarction of the dentate nucleus of the cerebellum and inferior olive.[7]

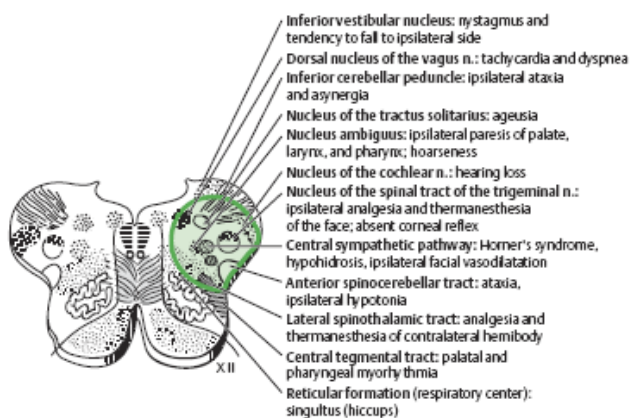


Figure 5: Dorsolateral medullary syndrome (Wallenberg syndrome) (Duus, 2005).

Stroke caused by multifactor disease such as hypertension, diabetes mellitus, dyslipidemia and many other factors are listed as risk factors. This patient had uncontrolled hypertension as risk factor. Hypertension was contributing factor in approximately 70 % of stroke.[8] Hypertension has been found to be the strongest risk factor in intracerebral hemorrhage as well as in thrombotic stroke. Hypertension also predisposes to cardiac disease promoting cardiogenic embolism and to the lesser extent to subarachnoid hemorrhage from aneurysms. Risk factor of stroke is the presence of definitive hypertension including Systolic blood pressure > 160 mmHg and or Diastolic blood pressure > 95 mmHg when compared with in normotensive is 3 in men and 2.9 in women. Incidence of stroke increases with severity of hypertension in men and women in all age categories from 45-84 years. [9]

People with heart disease of almost any type have more than twice the risk of stroke compared with people with normal cardiac function. Hypertensive heart disease, whether

detected clinically by left ventricular hypertrophy (LVH), on EKG, or by echocardiogram, is associated with an increased risk of both thromboembolic and hemorrhagic stroke.[10]

4. Management

This patient had been given several therapies:

General:

Airway, Breathing and circulation maintenance oxygen 3 L/min, Intra Vena Fluid: Asserger 20 drops per minute

Pharmacotherapy :

Piracetam inj 3 gram/6 hours
 Citicholin inj 500 mg/12 hours
 Ranitidin inj 50 mg/12 hours
 Aspilet 2 x 80 mg
 Captopril 2 x 6,25 mg
 Flunarizine 2 x 10 mg

Diet: High nutrition with low salt via gastric catheter

Physiotherapy

Management of Vertebrobasilar Atherothrombotic Disease (VBATD) in the Emergency Department varies on the basis of the patient's symptoms and condition. For patients with VBATD who have experienced ischemic infarcts, management falls into 2 major categories, (1) supportive measures and (2) interventions to reestablish patency in the infarct-related artery or to prevent occlusion of a vessel at risk for atherothrombotic or embolic occlusion:[7]

- a) Airway issues must be addressed in patients with brainstem infarction resulting from VBATD.
 - Compromise of ninth and tenth cranial nerves can blunt the gag reflex and inhibit even a conscious or awake patient from handling secretions effectively.
 - Secure the airway of patient with an unstable course or severe deficits before starting prolonged diagnostic imaging studies.
- b) ED patients with ischemic stroke often are hypertensive, even in the absence of premorbid blood pressure elevations.
 - Given the autoregulatory curve's tendency to shift to the right during hypertension, most authors caution against lowering the blood pressure in the first 24-48 hours after onset of stroke.
 - A precipitous drop in blood pressure can have a significant impact on cerebral perfusion pressure.
 - Consider antihypertensive medication only in cases of concomitant hypertensive emergency (ongoing end-organ damage), mean arterial pressure (MAP) greater than 130 mm Hg, or systolic blood pressure greater than 220 mm Hg.
- c) Because most patients with significant neurologic symptoms are denied oral intake until swallowing mechanisms are evaluated, goals of intravenous fluid therapy are to provide isotonic hydration and to avoid hyperglycemia, which appears to exacerbate neuronal injury in stroke.
- d) Treat vomiting with antiemetics; vomiting may be severe in some brainstem infarctions.

e) Prevent arterial occlusion: If a hemorrhagic lesion has been excluded, patients with Vertebrobasilar arterothrombotic disease are treated with antiplatelet agents or, in certain circumstances, an anticoagulant such as warfarin (see Medications section). Reperfuse the infarct-related artery by intraarterial thrombolysis or percutaneous transluminal angioplasty.

Neuroprotectan

Neuroprotectan drugs give variety result in stroke patient, National Guideline of Stroke not yet recommended neuroprotectan, so did AHA Guidelines. Nevertheless Indonesian Neurological Association still recommended piracetam and citicholine as neuroprotectan drugs for stroke patients.[11]

Piracetam

Piracetam has two mechanism affected to neuronal and vascular level: a. neuronal level: related to phospholipid, cell membran fluidity repaired, neurotransmitter repair, adenylate cyclase stimulation, b. vascular level: increase of erythrocyte deformability, decrease of platelet anti-aggregation, microcirculation repaired. It is indicated to be given at seven hours of stroke onset. First 12 grams of piracetam per infusion over 20 minute, and then followed with 3 grams bolus every 6 hour or 12 grams every 12 hour until the fourth day. The day of 5 until the end of 4 week, piracetam given 4,8 gram 3 times a day orally, and on the week of 5 until 12 it given 2,4 gram twice a day.[11]

Citicholine treatment will improve cerebral function passing through some ways as follow: a. Increase phosphatidyl choline to make membrane repair, b. Inhibit free fatty acid and free radical. c) Increase acetylcholine neurotransmitter production which has therapeutic effect as long as ischemic. d) As glutathione resources which kind of primary endogenous antioxidant in the brain.[12] For ischemic stroke, citicholine should be given on first 24 hour since stroke attack. With dose 250-1000 mg, intravenous 2-3 times a day over 2-14 day.[11]

Antiplatelet

Aspirin has proved to be perhaps the most consistently useful drug in the prevention of thrombotic and embolic strokes. One currently favored approach, based in part on the above-mentioned WARSS trial, is to simply administer aspirin in all cases of acute stroke (except perhaps if t-PA has been used). The acetyl moiety of aspirin combines with the platelet membrane and inhibits platelet cyclo-oxygenase, thus preventing the production of thromboxane A₂, a vasoconstricting prostaglandin, and also prostacyclin, a vasodilating prostaglandin. In patients who cannot tolerate aspirin, the platelet aggregate inhibitor clopidogrel or a similar drug (such as *ticlopidine* or *dipyridamole*) can be substituted.[4]

The results of prospective trials showed that antiplatelet agents (aspirin, ticlopidine, clopidogrel, dipyridamole, and the combination of aspirin and dipyridamole) were beneficial in series of patients with TIAs and strokes.[13] Clopidogrel 75 mg/day, is more effective than aspirin in preventing secondary ischemic events such as stroke, myocardial

infarctions, and vascular death. The Relative risk reduction is 8-9%. Clopidogrel is indicated in patient who are aspirin tolerated and should be considered in high risk patient, especially those who fail aspirin monotherapy. Aspirin combined with extended-release dipyridamol is another effective secondary stroke prevention regimen. The benefit of the two agents are additive. Headache, is the most common side effect, is attributable to the dipyridamol component. Ticlopidine is a platelet ADP receptor antagonist chemically related to clopidogrel. It has superior efficacy compared with aspirin, but side effect include rash, diarrhea, and neutropenia, which necessitates CBC monitoring. For these reasons, ticlopidine is rarely used as a first-line agent. [10]

Experience with flunarizine, a selective calcium-entry blocker, in the treatment of dizziness is reviewed. Clinical efficacy was predicted in pharmacological studies both in rabbits and humans: torsion swing or caloric induced nystagmus were significantly suppressed by flunarizine. Open therapeutic findings, using clinical and electronystagmographic or audiographic assessments as well, showed that flunarizine is of benefit to patients with vertigo of labyrinthine as well as of cerebrovascular origin. These results were confirmed in double-blind controlled trials. Flunarizine, either started with a loading dose gradually decreased thereafter, or given at a fixed 10 mg. dose schedule was proven to produce rapid improvement of dizziness and unsteadiness and to be tolerated very well.[14]

Anti vertigo drugs less benefit to improve vertigo symptom in patient with central vertigo compare with vertigo caused by peripheral vestibular lesions. Patient with cerebellum infarction must control carefully to prevent dysfunction of brainstem by cerebellar edema.[15]

Rehabilitation [3]

Physical Therapy: Rehabilitation services have been shown to play a critical role in recovery from acute stroke. In addition to the physicians, nurses play a crucial role on the rehabilitation team and often are first to suggest initiation of therapy services as they have the most extensive involvement with the patient. Prior to discussion of the specific therapy disciplines, address nursing issues in the care of patients with vertebrobasilar stroke.

Occupational Therapy: Occupational therapy is responsible for retraining fine motor skills that are needed to perform ADL (eg, dressing, bathing, grooming), as well as hand and arm function. OT also is involved in general strengthening, wheelchair mobility, upper extremity orthotics, and evaluation of needs for adaptive equipment, as well as family training and cognitive retraining for safety and ADL.

Speech Therapy: Speech therapy (ST) is responsible for cognitive retraining, speech and language skills, safety skills, swallowing assessment, and family training. Patients with dysphagia present with increased pooling of a bolus in the vallecula and/or pyriform sinuses, which spills into the airway, posing a significant risk for aspiration and pneumonia. Evaluation of these patients should be thorough and should include a videofluoroscopy with a modified barium swallow to assess for silent aspiration. The speech

and language therapist often performs the initial swallowing evaluation and determine the risk for aspiration and consistency of the diet.

5. Prognosis

When discharge from hospital after 7 days, this patient have controlled hypertension, no more horner's syndrome dan Thermanesthesia alternans but still have of left multi cranial nerve palsys (5th, 7th Lower Motor Neuron, 8th, 9th, 10th cranial nerve).

The outcome of vertebrobasilar stroke depends on the severity of the neurologic signs, the presence or absence of arterial lesions, the location and extent of infarction, and the mechanism of ischemia. The rate of death immediately after posterior-circulation stroke is approximately 3 to 4 percent. The recent study found 3.6 percent of patients died, and 18 percent of patients had a major disability. Cardiac embolism, basilar-artery involvement, and the involvement of multiple intracranial territories increase the risk of a poor outcome irrespective of the patient's age and underlying risk factors. Basilar-artery occlusive disease carries a high risk of disability and death, and efforts should be directed at identifying this lesion as quickly as possible.[13]

The prognosis of infarction of the basilar or vertebral arteries is poor. In one series, 45% of patients presented in coma. Importantly, half of the patients in this series had prodromal symptoms, including vertigo, which cleared completely in the 6 months prior to the stroke.[16]

The prognosis of patients with the lateral medullary syndrome usually is quite good for functional outcome; however, patients may die in the acute phase from aspiration pneumonia, and death has been reported from sleep apnea in a number of cases. [7]

Vertebrobasilar TIAs (ie, VBI) generally may have a more favorable prognosis than carotid territory TIAs because the risk of developing a completed stroke is less. Collateral circulation may account for improved outcome in these patients. Lateral medullary infarction (Wallenberg syndrome) is characterized by persistent symptoms that last for years. [7]

6. Conclusion

Vertigo is a prominent symptom of ischemic attacks and of brainstem infarction particularly the Wallenberg syndrome. A characteristic feature are a crossed weakness and sensory disturbance on one side of the face and on the opposite side of the body. For patients with VBATD who have experienced ischemic infarcts, management falls into 2 major categories, (1) supportive measures and (2) interventions to reestablish patency in the infarct-related artery or to prevent occlusion of a vessel at risk for atherothrombotic or embolic occlusion. The outcome of vertebrobasilar stroke depends on the severity of the neurologic signs, the presence or absence of arterial lesions, the location and extent of infarction, and the mechanism of ischemia

References

- [1] Moheet, A.M., Katzan, I. "Stroke". 2013, Available: <http://www.clevelandclinicmeded.com/medicalpubs/diseasemanagement/neurology/ischemic-stroke/> [Accessed: Sept. 12, 2016]
- [2] Meschia, J.F., Brott, T.G., Brown, J., Robert, D., "The Ischemic stroke genetics study (ISGC) protocol", BMC Neurology III:4. 2003.
- [3] Kaye, V., Brandster, M.E. 2006, "Vertebrobasilar Stroke". Available: <http://emedicine.medscape.com/article/323409-overview>. [Accessed: Sept. 12, 2016].
- [4] Adams, R.D., Victor, M., Ropper, A.H., "Principles of Neurology", 8th ed. Mc Graw Hill. Inc, Singapore. 2005
- [5] Duus, "Brainstem, Topical Diagnosis in Neurology", 9th ed, Thieme Stuttgart, New York. 2005.
- [6] Kerber, Kevin A., et al. "Stroke among patients with dizziness, vertigo, and imbalance in the emergency department." *Stroke* 37.10: 2484-2487. 2006
- [7] Lang, E. & Avilalo M, 2006, "Vertebrobasilar Atherothrombotic Disease". Available: <http://emedicine.medscape.com/article/794678-overview>. [Accessed: Sept. 12, 2016].
- [8] Yoon, P. W., Gillespie, C. D., George, M. G., & Wall, H. K. "Control of hypertension among adults—National Health and Nutrition Examination Survey, United States, 2005–2008", *MMWR Morb Mortal Wkly Rep*, 61(ssuppl). 2012
- [9] Budiarto, "Rational use of anti aggregating agents, in Ischemic Stroke Prevention, Stroke in depth-Now and The Future", Pendidikan Kedokteran Berkelanjutan, Surabaya, 2004.
- [10] Chiu, D., "Vascular Disease, Neurology secret", 3rd ed. Hanley & Belfus, Inc, Philadelphia. 2004.
- [11] PERDOSSI, " Guideline Stroke", Kelompok Studi Stroke. Perhimpunan Dokter Spesialis Saraf Indonesia. 2007.
- [12] Adibhlata, R.M., et al., "Effects of Citicholine on Phospholipid and glutation Levels in Tanscient Cerebral Ischaemia", *Stroke*, 32: 2376-2381. 2001.
- [13] Savitz SI & Caplan LR, "Vertebrobasilar Disease", *N Engl J Med*; 352:2618-26. 2005.
- [14] Wouters L., Amery W., Towse G., "Flunarizine in The Treatment of Vertigo, *J Laryngol Otol*: 97:697-704. 1985.
- [15] Basjiruddin A, "Gangguan Vestibuler Yang Disebabkan Oleh Gangguan Peredaran Darah Otak, *Neuro-Otologi Klinis Vertigo*", Joesoef A, Kusumastuti K (eds) Kelompok Studi Vertigo, Perhimpunan Dokter Spesialis Saraf Indonesia, Pengurus Pusat PERDOSSI. 2002.
- [16] Marill K, 2006, Central Vertigo, Available: <http://emedicine.medscape.com/article/794789-overview>. [Accessed: Sept. 12, 2016].