

Table of Contents

Astaxanthin increase osteocytes, osteoblasts, decrease adipocytes cells, and reduces osteonecrotic events in femoral head of Wistar rats exposed to alcohol.

Agus Eka Wiradiputra I Ketut Suyasa Putu Astawa Ketut Siki Kawiya

[DOWNLOAD PDF](#) | [VIEW PDF](#) |

Work-related psychological distress and social dysfunction in Nurses at Haji Hospital Medan-Indonesia

Novy Prasanty M. Surya Husada Elmeida Effendy Muhammad Joesoef Simbolon

[DOWNLOAD PDF](#) | [VIEW PDF](#) |

Ganglion Cell Complex thickness as an early predictor of microstructural changes in varying degrees of myopia in comparison with Retinal Nerve Fiber Layer (RNFL) thickness

Andi Pratiwi Machmud Andi Muhammad Ichsan Habibah Setyawati Muhiddin

[DOWNLOAD PDF](#) | [VIEW PDF](#) |

Rapid action to avoid cataract blindness in South Sulawesi

Habibah Setyawati Muhiddin Ahmad Ashraf Amalius George Ade Novra Sitanaya Dyah Ayu Windy

[DOWNLOAD PDF](#) | [VIEW PDF](#) |

Testosterone increases corpus cavernous smooth muscle cells in oxidative stress-induced rodents (Sprague-Dawley)

I Nyoman Gede Wardana IGA Widianti Gede Wirata

[DOWNLOAD PDF](#) | [VIEW PDF](#) |

Bioequivalence study of dihydroartemisinin-piperaquine (DHP) generic formulation in fixed-dose combination, in healthy Indonesian volunteers

Ani Isnawati Retno Gitawati Mariana Raini Indri Rooslamati Lanny Marliany Effi Setiawati Vivi Setiawaty

[DOWNLOAD PDF](#) | [VIEW PDF](#) |



Agile design of public hospitals in Iran

Ghahraman Mahmoudi Mohammad Ali Jahani Masoomeh Abdi Mousa Yaminfirooz Mohammad Amin Bahrami

[DOWNLOAD PDF](#) | [VIEW PDF](#) |

Plasma miR-135a; a potential biomarker for diagnosis of new type 2 diabetes (T2DM)

Mohamad Reza Sarookhani Maryam Honardoost Farshad Foroughi Yousef Khazaei Monfared

[DOWNLOAD PDF](#) | [VIEW PDF](#) |

Cranial nerve disorder on nasopharyngeal cancer patient at Dr.Kariadi Hospital Semarang 2014-2016

Dwi Antono Muyassaroh Muyassaroh Rully Satriawan Rachma Purnama Sari

[DOWNLOAD PDF](#) | [VIEW PDF](#) |

Effect of glomerulosclerosis index, tubular index, and matrix metalloprotein against serum creatinine and estimated glomerular filtration rate in obstructive kidney stone patients in Sanglah General Hospital Denpasar-Bali

Oka A. A. G Sun Fu

[DOWNLOAD PDF](#) | [VIEW PDF](#) |

Correlation between Quality of Work Life (QWL) with Nurse productivity in inpatient room Bhayangkara Tk III Hospital Manado

Natalia G Wara Starry H Rampengan Martha Korompis

[DOWNLOAD PDF](#) | [VIEW PDF](#) |

Higher endometrial receptivity caused by Letrozole in antagonist protocol-stimulated mouse uterus

A. A. N. Anantasika K. Suwiyoga I. M. Bakta I. N. M. Astawa

[DOWNLOAD PDF](#) | [VIEW PDF](#) |

Operative Nuances of Endoscopic Third Ventriculostomy for Pediatric Obstructive Hydrocephalus

Dewa Putu Wisnu Wardhana Sri Maliawan

[DOWNLOAD PDF](#) | [VIEW PDF](#) |

The relationship between spiritual intelligence, life expectancy, and self- regulation among high school students

Najaf Tahmasbipour Sadegh Nasri Zahra Rafieeyazd

[DOWNLOAD PDF](#) | [VIEW PDF](#) |

The effect of slow-stroke back massage on anxiety in female patients with heart failure

Fatemeh Mohaddes Narges Ghaderi Ehsanpour Tahereh Najafi Ghezeljeh

[DOWNLOAD PDF](#) | [VIEW PDF](#) |

Medicine reminder to improve treatment compliance on geriatric patients with diabetic neuropathy at Sanglah Central Hospital, Bali-Indonesia

Ida Ayu Manik Partha Sutema Made Krisna Adi Jaya I Made Bakta

[DOWNLOAD PDF](#) | [VIEW PDF](#) |

The rationale of surgical treatment in pediatric spine tuberculosis

Komang Agung Irianto

[DOWNLOAD PDF](#) | [VIEW PDF](#) |

Effective methods in preventing plagiarism in medical research: A qualitative study at Tabriz University of Medical Sciences-Iran

Nayer Soltany Mohammadhiwa Abdekhoda Shafi Habibi

[DOWNLOAD PDF](#) | [VIEW PDF](#) |

Association between premature canities and quality of life at Medan, Indonesia 2017

Putri Ashraf Nelva K Jusuf Rointan Simanungkalit

[DOWNLOAD PDF](#) | [VIEW PDF](#) |

Impacts of endometrioma type and two-different techniques of laparoscopic cystectomy on ovarian reserve by measuring anti-mullerian hormone concentration

Ida Bagus Putra Adnyana

[DOWNLOAD PDF](#) | [VIEW PDF](#) |

Adult Idiopathic Scoliosis: Correction or not?

Tjokorda GB Mahadewa

[DOWNLOAD PDF](#) | [VIEW PDF](#) |

Measuring the nurses' professional self-concept and its correlation with working stress in Iranian educational Hospitals

Razieh Montazeralfaraj Montazeralfaraj Elham Ahmadi Ahmadi Arefeh Dehghani Tafti Tafti Omid Barati Mohammad Amin Bahrami

[DOWNLOAD PDF](#) | [VIEW PDF](#) |

The relationship between emotional intelligence with general health and academic achievement: a case study in Iran's Health system

Mohammad Ranjbar Razieh Montazerfaraj Mastoureh Pourmahmoodian

[DOWNLOAD PDF](#) | [VIEW PDF](#) |

Cost for traffic accident related injuries and its comparison it with the national standard: A case study in Iran

Somayeh Mahdian Mahdian Kavos Asgari Asgari Mohammad Ranjbar

[DOWNLOAD PDF](#) | [VIEW PDF](#) |

Utilization of Medical Education research studies: A survey among participants in Iranian National Conference on Medical Education

Tahereh Changiz Alireza Yousefy Mohammad Fakhari

[DOWNLOAD PDF](#) | [VIEW PDF](#) |

Evaluating Hospital safety index in Susa public hospital: An action research study

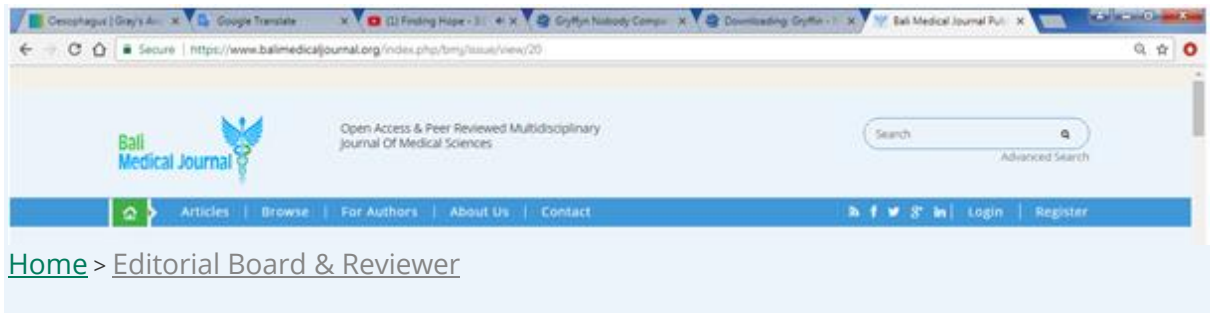
Ahmad Reza Raeisi Amin Torabipour Leyla Karimi

[DOWNLOAD PDF](#) | [VIEW PDF](#) |

The effect of educational Intervention based on Health Belief Model (HBM) on the promotion of teachers social capital in Baft in 2015

Rahmatolah Dadvar Mohammad Hossein Baghianimoghadam Seyyed Saeed Mazloomi

[DOWNLOAD PDF](#) | [VIEW PDF](#) |



Editor-in-Chief

Prof. Dr. Sri Maliawan, SpBS

(Scopus ID= 15738530400, h-index= 5, srimaliawan@unud.ac.id / maliawans@yahoo.com)

Department of Neuro Surgery, Udayana University

Sanglah General Hospital

Bali - Indonesia

Associate Editor

Prof. Putra Manuaba, M.Phil

(Scopus ID= 8412278400, h-index=

3, putramanuaba@unud.ac.id / putramanuaba28@yahoo.com)

Biomedicine Postgraduate Program, Udayana University

Bali - Indonesia

Prof. Ketut Suwiyoga, SpOG

(suwiyoga@balimedicaljournal.org)

Faculty of Medicine, Udayana University, Sanglah Hospital Denpasar, Bali-Indonesia

Editorial Board for Regional America

Ankit Sakhuja, M.B.B.S., F.A.C.P., F.A.S.N.

(Scopus ID= 16744977200, h-index= 8, asakhuja@med.umich.edu)

Nephrology and Hypertension Cleveland Clinic (United States)

Editorial Board for Regional Australia

Prof. John Svigos, MB. BS. DRCOG., FRCOG., RANZCOG

(Scopus ID= 6603773825, h-index= 7, jsvigos@iprimus.com.au)

Ashford Hospital & Faculty of Health Sciences, University of Adelaide, Australia

dr Deasy Ayuningtyas Tandio MPH-MBA.

Email: deasytandio@yahoo.com

James Cook University Australia Master of Public Health Master Of Business Administration,
Indonesia

([orcidID: 0000-0001-7847-2831](https://orcid.org/0000-0001-7847-2831), H-index = 1).

Editorial Board for Regional Europa

Prof. Harald Hoekstra

([Scopus ID= 36038081900](https://scopus.com/authid/detail.url?authorID=36038081900), [h-index= 53](https://h-index.com/53/jsvigos@iprimus.com.au), jsvigos@iprimus.com.au)

Universitair Medisch Centrum Groningen, Division of Surgical Oncology, Groningen the
Netherland

Editorial Board for Regional Asia

Prof Huang Qin

([Scopus ID= 8570628900](https://scopus.com/authid/detail.url?authorID=8570628900), [h-index= 1](https://h-index.com/1/qhuang@cqu.edu.cn), qhuang@cqu.edu.cn)

Chairman Dept. of Neurosurgery, Guangdong 999 Hospital Guangzhou China

Prof. Soo Khee Chee

([Scopus ID= 7005885770](https://scopus.com/authid/detail.url?authorID=7005885770), [h-index= 8](https://h-index.com/8/kheechee.soo@duke-nus.edu.sg), kheechee.soo@duke-nus.edu.sg)

SGH (Singapore General Hospital), National University Hospital, Duke Medical Center
Singapore

Dr. G Sai sailesh Kumar, Ph.D

([Scopus ID= 56176035300](https://scopus.com/authid/detail.url?authorID=56176035300), [h-index= 5](https://h-index.com/5/saisailesh.kumar@gmail.com), saisailesh.kumar@gmail.com)

Department of Physiology, Little Flower Institute of Medical Sciences and Research, Angamaly,
Kerala,India

Assoc. Prof. Mohammad Amin Bahrami

([Scopus ID= 55524082200](https://scopus.com/authid/detail.url?authorID=55524082200), aminbahrami1359@gmail.com)

Head of healthcare management department, Shahid Sadoughi University of Medical Sciences,
Yazd,Iran

Dr. Tanveer Beg, PhD

([Scopus ID: 6505772852](https://scopus.com/authid/detail.url?authorID=6505772852); [h-index = 11](https://h-index.com/11/tbmirza@jazanu.edu.sa); tbmirza@jazanu.edu.sa)

Assistant Professor, Department of Biology, Faculty of Science, Jazan University, Jazan, Saudi
Arabia.

Editorial Board Members

Prof. Andi Asadul Islam

(undee@med.unhas.ac.id)

Faculty of Medicine Hasanudin University, Makasar-Indonesia

Prof. Dr. dr. Abdul Hafid Bajamal, Sp.BS

(hfbajamal@gmail.com)

Faculty of Medicine Airlangga University, Surabaya-Indonesia

dr. I.B. Amertha P. Manuaba, SKed, MBiomed.

(AmerthaManuaba@gmail.com / Amertha_Manuaba@unud.ac.id)

(ResearcherID: P-9169-2016) (orcid.org/0000-0001-6647-9497)

[Scopus ID=57195520004](https://scopus.com/authid/detail.uri?authorId=57195520004)

Biomedicine Magister Program, Udayana University, Indonesia

Editorial inquiries to be addressed to: editor@balimedicaljournal.org

Reviewer

Prof. Dr. dr. Raka Sudewi, SpS (K)

(raka_sudewi@unud.ac.id/raka_sudewi2006@yahoo.com)

Universitas Udayana, Department of Neurology, Bali, Indonesia

Scopus Author ID: 12140226200 (H-index: 6)

Dr. dr. Tjok Gd. Bgs. Mahadewa, S.Ked, Sp.BS(K)-Spine

(tjokmahadewa@hotmail.com)

Universitas Udayana, Department of Neurosurgery, Bali, Indonesia

Scopus Author ID: 6507494320 (H-index: 3)

dr. Dewa Putu Wisnu Wardhana, MD, FICS

(wisnu_wardhana@unud.ac.id)

Universitas Udayana, Department of Neurosurgery, Bali, Indonesia

Prof. Dr. dr. Made Wardhana, SpKK(K), FINS DV, FAADV

(made_wardhana@yahoo.com)

Universitas Udayana, Department of Dermatology and Venerology, Bali, Indonesia

Dr. dr. A A Mas Putrawati Triningrat, Sp. M (K)

(masputra06@gmail.com)

Universitas Udayana, Department of Ophthalmology, Bali, Indonesia

Dr.dr.Tjokorda Gde Agung Senapathi,SpAn.KAR

(tjoksenapathi@unud.ac.id)

Universitas Udayana, Department Anesthesia & Reanimation, Bali, Indonesia

Scopus Author ID: 36519653900 (H-index: 2)

The screenshot shows a web browser window displaying the Science Impact Factor profile for BALI MEDICAL JOURNAL. The page includes a navigation menu on the left with options like Home, Contact Us, Journal Search, and Master Journal List. The main content area lists the journal's title, ISSN (2089-1180), Chief Editor (Prof. Dr. Sri Maliawan), email (editor@balimedicaljournal.org), language (English), starting year (2012), frequency (3), website (http://balimedicaljournal.org), and country (Indonesia). A description states that the journal is published by DiscoverSys Inc., Canada, on behalf of Sanglah General Hospital in collaboration with the Indonesian Physician Forum and Indonesia College of Surgeons. It is an open access, peer-reviewed journal. A green checkmark indicates the journal is indexed, and the Impact Factor is listed as 1.66. A download logo for the Science Impact Factor is also visible. The browser's taskbar at the bottom shows the system time as 9:17 on 19/07/2018.

The screenshot shows the website for BALI MEDICAL JOURNAL, specifically the 'Indexing' page. The page header includes navigation links for Articles, Browse, For Authors, About Us, and Contact, along with social media icons and options for Login and Register. The main content area lists the databases where the journal is indexed: Web of Science (Clarivate Analytics), USA National Library of Medicine (Pubmed), NIH National Institutes of Health, HINARI Research in Health, International Committee of Medical Journal Editors, DOAJ Directory of Open Access Journals, SINTA - Science and Technology Index, Portal Garuda, Google Scholar, DOI Crossref, EBSCO Open Science Directory, Sherpa/Romeo, Ulrichsweb.com™ [Proquest], InCites Journal Citation Reports (Web of Science), Harvard Library, Index Copernicus, National Library of Australia, University of Denmark, Library of Science and Technology (China), ETH Bibliothek (Switzerland), SJIF Journal Rank, Science Impact Factor (SIF), and Genamics. On the right side, there are logos for Web of Science, Scopus CITEDNESS, and DOAJ. Below these logos are three green buttons: 'Full Indexing List', 'In Press', and 'Submit An Article'.

Testosterone increases corpus cavernous smooth muscle cells in oxidative stress-induced rodents (*Sprague-Dawley*)



I Nyoman Gede Wardana,^{1*} I Gusti Ayu Widianti,¹ Gede Wirata¹

ABSTRACT

Background: Nowadays, there are many researchers interested in the role of oxidative stress in the pathophysiological mechanism against erectile dysfunction. Oxidative stress occurs when there is an imbalance between pro-oxidant and the ability of the antioxidants to scavenge excess reactive oxygen species. The important role of oxidative stress in the pathophysiological mechanism of male and female infertility has been known. However, its role in maintaining the integrity structure of penile erectile tissue especially corpus cavernous smooth muscle cell has not been investigated comprehensively yet. In another side, testosterone has a critical role in maintaining the integrity of the penile erectile tissue.

Aim: This study aims to investigate the effect of oxidative stress condition on the administration of testosterone for increasing corpus cavernous smooth muscle cells.

Methods: The experiment uses pretest-posttest control group design. Data were collected from 40 rodent's strain SD (*Sprague-Dawley*). Ten penile organs were removed before stress, and 30 rodents given psychosocial stress for 6 weeks. After the third-week of stress, 10 penile

organs were removed. At the beginning of the fourth week, 20 rodents were randomly divided into 2 groups: the control group (untreated mouse), were treated with an intramuscular aquabides injection and the case group were treated with intramuscular testosterone injection (case group). Five penile organs from each group were removed to observe the corpus cavernous smooth muscle cells number at the sixth weeks of the stress. During the six week stress, blood samples were collected for MDA and SOD measurement at the beginning, at the third week, and at the sixth week.

Results: This study found that oxidative stress decreases the corpus cavernous smooth muscle cell (CCSM) number significantly. The number of CCSM before stress $20,20 \pm 1,23$, and after the third-week of stress is $14,20 \pm 1,03$ ($P < 0,05$). In addition, the administration of testosterone at the beginning of fourth-week of stress raises CCSM number significantly. The number of CCSM before treatment is $13,80 \pm 0,84$, and after treatment is $18,40 \pm 1,14$.

Conclusion: There was a significant elevation of CCSM number without being affected by oxidative stress in this study.

Keywords: oxidative stress, psychosocial stress, MDA, SOD, testosterone, corpus cavernous smooth muscle cell

Cite This Article: Wardana, I.N.G., Widianti, I.G.A., Wirata, G. 2018. Testosterone increases corpus cavernous smooth muscle cells in oxidative stress-induced rodents (*Sprague-Dawley*). *Bali Medical Journal* 7(2): 313-322. DOI: [10.15562/bmj.v7i2.970](https://doi.org/10.15562/bmj.v7i2.970)

¹Anatomy Department, Faculty of Medicine, Udayana University

INTRODUCTION

Oxidative stress is a condition in which the anti-oxidant defense system is inadequate to inactivate the reactive oxygen compound and the reactive nitrogen compound produced by either the body due to its excess production, decreased antioxidant defense system, or both. It has an essential role in acute and chronic diseases and the normal aging process. It causes damage to acid-base nuclei, fats, and proteins that affect cell conditions and viability or induce the occurrence of various cellular responses through the formation of secondary reactive compounds and ultimately cell death due to necrosis or apoptosis.¹

Several studies have shown the effect of free radicals on the smooth muscle cells of the corpus cavernosa. Excessive production of NO (nitric oxide) as a result of inflammatory processes such as Peyronie disease, penile trauma, and priapism causes cytotoxic effects on the cavernous muscle cells.² Meanwhile, a study by conditioning

rodents having occlusive venous priapism showed elevated lipid peroxidation levels in corpus cavernous tissue.³ Its smooth muscle cells that had been given high concentrations of NO decreased synthesis of ATP (Adenosine Triphosphate) and DNA (Deoxyribonucleic Acid) significantly.⁴ The mechanism by which high concentrations of NO can cause cytotoxic effects on it remains unclear. NO levels were also found to increase in the interstitial space of the cutaneous tissue after being given thermal stress.⁵ Another study found that there is fibrosis in the corpus cavernous tissue after neurotomy characterized by increased expression of $\beta 1$ mRNA, HIF-1 α , TGF- $\beta 1$, and type III collagen by immunohistochemical examination.⁶ The integrity and number of its smooth muscle cells are essential in erectile physiology that shown in a study by undergoing rabbit castration. Those make decrement of intracavernous pressure and changes the balance of total connective tissue with the number

*Correspondence to:
I Nyoman Gede Wardana, Anatomy Department, Faculty of Medicine, Udayana University
mandewardana@unud.ac.id

of smooth muscles cells. Besides, there is progressively fat cell accumulation in the subtunical region of the corpus cavernosum and eventually leads to venous occlusion and erectile dysfunction.⁷

The expectable decrement of the concentrations of testosterone occurs after two weeks post-castration.⁸ On the other hand, the replacement of testosterone 0.018 milligrams by dose in castrated rodents can improve the corpus structure of the cavernosa.⁹ Testosterone will reduce its concentration in the blood by responding to long-term stress. Stress derived from various stimuli will cause a sharp increment in glucocorticoid concentrations in the blood and decreased testosterone concentrations as a result of reduced steroidogenesis.¹⁰

Several studies have shown the negative effects of psychosocial stress according to changes in the modern lifestyle of the human body.¹¹⁻¹⁴ It will increase blood pressure and then decrease NO concentrations.¹⁵ Consequently, it influences subcellular injury in endothelial cells.¹⁶ Psychological stress which is given to rodents every 1 hour for ten weeks tends to decrease the sexual activity of male rodents and lowering catecholamine levels and its metabolites in the brain.¹⁷ The isolation stress assigned to a 35-day-old rodent by placing it in a small cage for 30 days will decrease the secretion of prolactin, LH, and testosterone.¹⁸ It also increases the levels of corticosterone on day 7th and 30th as well as oxidative stress in peripheral blood cell DNA.¹⁹

In the preliminary study obtained that psychosocial stress which is given about 4 hours/day for six weeks in male rodents had significantly increased malondialdehyde (MDA) levels in the first week of treatment and also decreased levels of superoxide dismutase (SOD) antioxidants. In simpler terms, oxidative stress occurs after the first week of treatment, and it becomes higher and higher every week, both in the third week and the sixth week.²⁰ It decreases the number of smooth muscle cells of the corpus cavernosum during the third week of treatment. Intramuscular injection of 0.018 mg testosterone at the beginning of the fourth week was able to restore the amount of smooth muscle cell, but that was unable to absorb oxidative stress in the same way.^{21,22} This research is necessary to re-examine how oxidative stress conditions influence the provision of testosterone in maintaining the integrity of penile tissue, especially the number of smooth muscle cells within corpus cavernosum.

MATERIAL AND METHOD

This research is experimental research, using both pre-test and post-test control group design within

nine weeks.²³ Pocock's formula calculates the samples. Based on preliminary study, the writer obtained ten samples. As the rodent was partially killed two times before, then the sample size was 100%, so it was 20 for each treatment group. It was adult male rodents (*Sprague-Dawley*) with the following inclusion criteria: 3 months old, weight average 250-300 gram, and healthy. Psychosocial stress is the level of stress for rodents in the form of placement of 5 rodents in one cage 20 × 10 × 12 cm in size along 4 hours/day for six weeks. Testosterone injection is the concentration of testosterone using "Sustanon 250", regarding to dose conversion by Gosh, particularly the adult human dose is 1 mL (body weight 60-70 kg), as well as its conversion to 200 gram of rodents, is 0,018 ml.²⁴ Example of dosage calculation as follows. If rodent weight is 300 grams, then the dose is $300/200 \times 0.018 \text{ ml} = 0.027 \text{ ml}$ or 27 μl . So, the Australian-made microsyringe "Sustanon 250" is inserted until it shows the scale 27.

The number of smooth muscle cells within corpus cavernosum is the average number of smooth muscle cells found between the two sinus cavernosum (trabecula) examined on 5 high power field (HPF) using 40x magnification. Lipid peroxidation levels are determined by measuring the levels of thiobarbituric acid (TBARS)-reactive products and expressed as malondialdehyde (MDA) levels. MDA levels are plasma malondialdehyde levels measured by Hach DR/2000-branded spectrophotometer. The levels of SOD antioxidants are plasma SOD levels measured by particular reagents for SOD. The weight of adult male rodents is metric status measured by using electronic scales under the brand "Sartorius" every week during treatment. In this study environmental conditions during the experiment will be made equal each other.

Equipment used in this research are, such as: 6 units rodent cages of 20 × 10 × 12 cm in size, 6 units rodent cages of 50 × 40 × 15 cm in size, both in which there are husks, food, and drink bottles, Sartorius electronic scale (5000 gram in capacity), Australian-made microsyringe 0-50 μl in scale, object glass and cover glass, minor surgical set, Olympus light microscope, Hach DR/2000-branded spectrophotometer, stationery, drinking water (Aqua®), standard foods for male rodents (*Sprague-Dawley*), ether, EDTA, paraffin blocks, formaldehyde buffer solution, reagents for measuring level of MDA and SOD antioxidants, and trichrome light green (Gomori) staining material.

40 rodents are prepared, and then before the treatment, 10 rodents are euthanized, and their penis organs are established in the histopathological study to examine the number of smooth

muscle cells within corpus cavernosum. Afterward, 30 survival rodents obtain a psychosocial stress treatment for six weeks. At the end of the third week, ten euthanized rodents are examined to get their corpus cavernosum smooth muscle cell data. Moreover, 20 of remaining rodents are randomly divided into two groups, namely the control group (received aquabides injections) and the case group (received testosterone injections). And at the end of the treatment, 5 penis organ samples of euthanized rodents from each group are prepared for histopathological study again. The blood samples of 20 are taken before treatment, at the end of the third week, and at the sixth week of treatment for examining MDA and SOD levels.

The Measurement of MDA Levels

Blood samples are aspirated from medial canthus of sinus orbitalis, approximately 2 mL at week-0, first week, third week and sixth week. It is inserted into a tube containing EDTA 1 mg/ml, then centrifuged 4000 rpm for 15 minutes to obtain plasma. Plasma is important to check the levels of MDA and SOD afterward. The examination procedure of MDA levels is performed according to Conti's project.²⁵ Two tubes of 13 ml polypropylene must be prepared, one tube for standard and the other one for plasma. Each tube is added 750 μ l of H_3PO_4 and 250 μ l of TBA (thiobarbituric acid). One tube

was inserted with 50 μ l of plasma, and so 50 μ l of standard solution (1,1,3,3-tetraethoxypropane) into the other one. In addition, each tube was added with 450 μ l of H_2O again and shaken into the vortex. Both tubes are then heated to 100° C for 60 minutes, and they are cooled in ice bath for \pm 10 minutes (until pink) for next step. In addition, those samples were prepared for examination in the column of Sep-Pak C_{18} . First, methanol is felt into the column of Sep-Pak C_{18} as many as 4 times and briefly discarded. Secondly, added 5 ml of H_2O and discarded, too. Those samples are next inserted and also rejected, till shown pink color appearance on the walls. Finally, re-inserting 4 ml of methanol accommodated within those tubes and interpreting them in a spectrophotometer of 532 nm in wavelength (the units are mmol/L).

The Measurement of SOD Antioxidant Level

Reagents required, such as: mixed substrate 0.05 mmol/l, xanthine 0.025 mmol/l, buffer 50 mmol/l, pH 10.2, CAPS 0.94 mmol/l, and xanthine oxidase 80 U/l. The standard process for the measurement of SOD antioxidant level is performed based on the manual Randox laboratory technique.²⁶ 2 tubes must be prepared, one tube for standard and the other one for plasma. One tube contains 0.05 ml of plasma, and the standard one contains 0.05 ml standard solution. Both tubes incorporated by a mixed substrate solution of 1.7 ml in volume. Both solutions in the tube are shaken with the vortex machine. The final solution of 0.25 ml xanthine oxidase is added to each tube and shaken with a vortex machine. After first 30 seconds, the absorbance of the mixture is read as A1 in the spectrophotometer and so the next three minutes as A2. The SOD level is calculated by the formula: $(A2 - A1) / 3$.

Corpus Cavernosum Smooth Muscle Cells Number

The number of corpus cavernosum smooth muscle cells are provided from the transverse section of the mid-corpus cavernosum calculated by counting them between the two sinuses using an Olympus light microscope (magnification of 40x). The development of the penile microstructure is performed by standard microscopic preparation procedure (Figure 1).

Penile Organ Collecting Techniques

The rodents were killed by previously stunned by inserting it into a jar. Then we waited for 5-10 minutes until they fell asleep and removing the penis tissue by doing an incision in the abdomen.

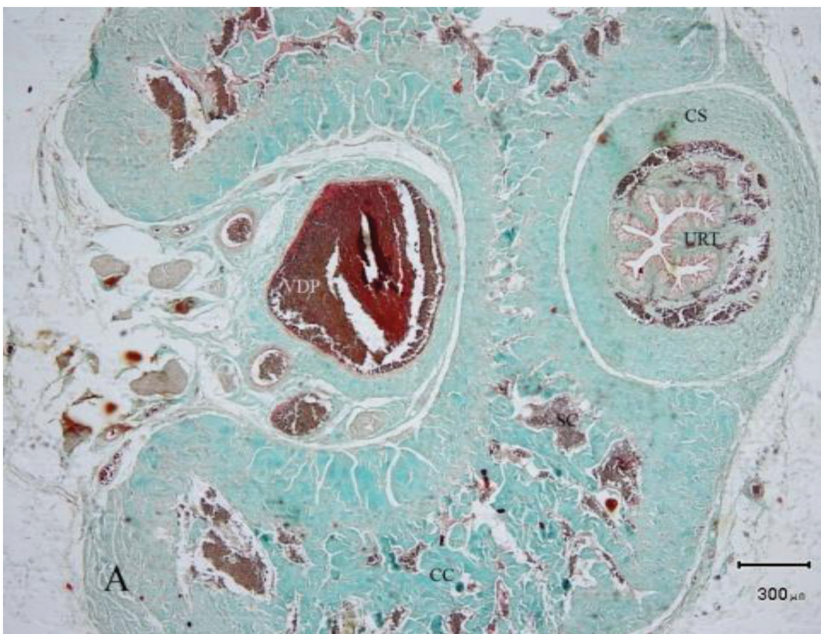


Figure 1 Transversal section of corpus cavernosum of the rodent before induced with stress (4x). (VDP: Dorsalis Vein of Penis; CS: Corpus Spongiosum; CC: Corpus Cavernosum; SC: Sinus Cavernosum; URT: Urethra)

Histopathological Processing Technique

Penile organs that have been taken are fed directly into 10% formalin buffer (pH: 7.2). The next incision in the medial part of the corpus cavernosum is approximately 3-5 mm thick and placed in the cassette (Tissue Tak III, Milles). It automatically helps in the form of dehydration, clarification, penetration, and paraffin blocking within its. The stages are as follows: 1 × 0.5-2 hours ethanol 80%, 4 × 0.5-2 hours ethanol 95%, 1 × 0.5-2 hours ethanol 100%, 3 × 0.5-2 hours xylene, and 3 × 0.5-2 hours of paraffin. Final processing is done by embedding the preparation with a paraffin-liquid (Histoplast Shandon) in a stainless steel mold, and the top surface is sealed with a plastic cassette, and that organ is ready to be cut with a microtome. That organ is reduced with a hyper cut-Shandon rotary type-microtome with 6 microns thickness. The ribbon-formed incision is then placed in a water bath at a temperature of 45°C. Incision by incision is then separated and captured on the object glasses prior to chrome gelatin adhesive on those. Those specimens are finally dried and ready for painting.

Trichrome Light Green Staining

The required solutions are 75 ml of Bouin's picric acid, 25 ml of formalin 40%, 5 ml of glacial acetic acid, 0.6 gram of trichrome chromo tope 2R, 0.3 gram of light green SF solution, 1.0 ml of glacial acetic acid, 0.8 gram of phosphotungstic acid, 100 ml of aquabides, iron-hematoxylin solution by Weigert, and xylene solution. The specimens are inserted in xylene solution for 10 minutes, then into absolute alcohol for 10 minutes, and into next 95% alcohol for 10 minutes. Those are briefly rinsed with water, then put in a Bouin's solution and put into an oven with a temperature of 56°C for 1 hour. Afterward, they are washed with running water, then fill them into iron hematoxylin solution for 10 minutes, rewashed them with running water for 5 minutes. The next progressing step is conducted by incorporating them into trichrome dye solution for 15-20 minutes, then rinse with running water, fill them into alcohol 95% for 5 minutes, insert them into absolute alcohol for 10 minutes, xylene solution for 10 minutes, and finally, apply for balsam. Their feature found under microscopic study are mainly appear as the black-color nucleus, red-color muscles and cytoplasm, green-color connective tissues, and also orange-color erythrocytes.

Statistical Analysis

Data obtained in this study are analyzed by a specific test. The test is performed to determine whether the data are normally distributed using the

Shapiro-Wilk test. To test the effect of psychosocial stress on MDA levels, SOD, and the number of smooth muscle cells of the corpus cavernosum, the effect of testosterone at the beginning of the fourth week of treatment on the muscle cell number, MDA and SOD levels, paired sample t-test is recommended absolutely (O1-O2; O3-O4). On the other hand, to compare the average number of smooth muscle cells in both treatment groups, independent samples t-test is used consistently. The degree of significance in this study, $\alpha = 0.05$.

RESULTS

Normality test for MDA and SOD antioxidant using Shapiro-Wilk test showed that both distributions are normal ($P > 0.05$). It is continued by using parametric paired sample t-test, either to test the increment of the average of MDA level or so the decrement of the average of SOD antioxidant level. [Table 1](#) shows that the mean of MDA levels before stress is 3.76 ± 0.48 mmol/L, whereas after stress was 15.75 ± 0.51 mmol/L. The statistical analysis with paired sample t-test showed that the result was significantly different ($P < 0.05$) with t value = -66.31 and $P = 0.000$. It means there is an increase in the mean of MDA levels after stress than before about 11.99 mmol/L. In another hand, the mean of SOD concentration before stress was 765.24 ± 9.69 , and after stress was 591.58 ± 9.53 μ /gHb. The paired sample t-test shows that the result is significantly different ($P < 0.05$) with t value = 68.12 and $p = 0.000$. It means the decrement value of the mean of SOD level before and after given stress is about 173.66 μ /gHb. Of the three weeks psychosocial stress, the rodents were in a condition of oxidative stress.

The normality test for corpus cavernous smooth muscle cell number shows that the data distribution is normal ($P > 0.05$). The effect of oxidative stress on the number of smooth muscle cells is presented briefly in [Figure 6](#) which shows the average of smooth muscle cells number before stress is 20.2 ± 1.23 cells, whereas after stress 14.2 ± 1.03 cells. The analysis with paired sample t-test got a significantly different result ($P < 0.05$) with t value = 16.43 and p-value = 0.000, and the mean decrement as many as 6 cells. So for three weeks given psychosocial stress, there has been a significant decrement in the corpus cavernous smooth muscle cells number. The effect of aquabidesh and testosterone injection on MDA levels before and after treatment is analyzed by independent t-test ([Table 1](#), [Figure 7](#)). Independent t-test shows that MDA and SOD levels before treatment in both groups did not differ

Table 1 MDA, SOD, and CCSM levels in Control and Case Groups Before and After Treatment

Variable		N	Before Treatment Mean \pm SD	After Treatment Mean \pm SD	t	p
Control	MDA (mmol/L)	10	15,71 \pm 0,51	26,14 \pm 0,56	-44,79	0,000
	SOD (μ /gHb)	10	592,53 \pm 8,00	354,63 \pm 7,39	82,59	0,000
	CCSM	5	14,6 \pm 1,14	8,6 \pm 1,52	5,48	0,005
Case	MDA (mmol/L)	10	15,79 \pm 0,53	26,08 \pm 0,74	-29,74	0,000
	SOD (μ /gHb)	10	590,63 \pm 11,21	352,88 \pm 8,86	53,56	0,000
	CCSM	5	13,8 \pm 0,84	18,4 \pm 1,14	-6,15	0,004

Note:

CCSM = corpus cavernous smooth muscle cells

SOD = superoxide dismutase

MDA = malondialdehyde

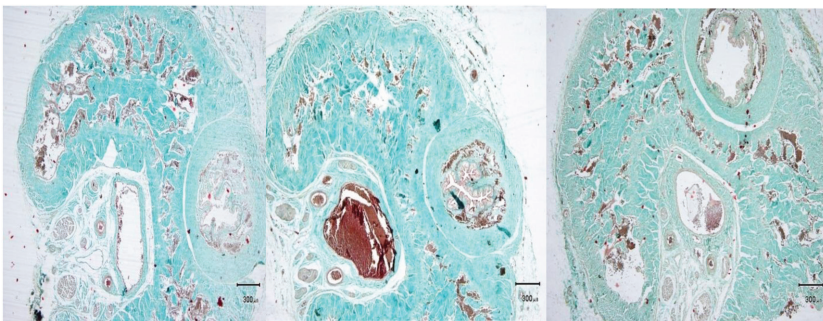


Figure 2 (Left) Transversal section of corpus cavernosum of the rodent in the 3rd week of stress (4x). (Middle) Transversal section of corpus cavernosum of the rodent in the 6th week of stress + aquabides injection in an early 4th week (4x). (Right) Transversal section of corpus cavernosum of the rodent in the 6th week of stress + testosterone injection in an early 4th week (4x)

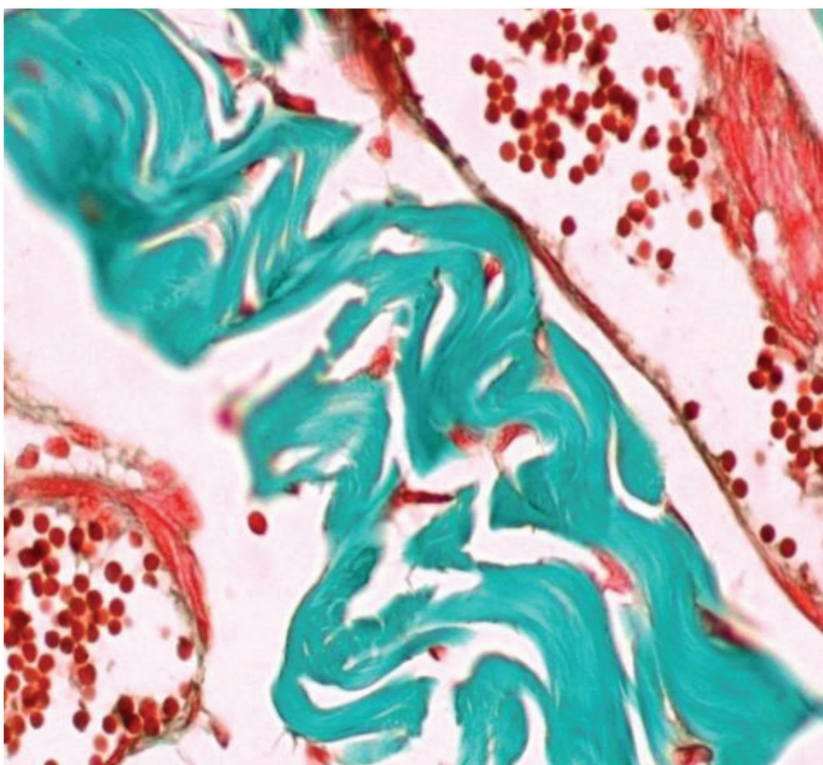


Figure 3 Corpus cavernous smooth muscle cells number before treatment (40x)

significantly ($P > 0.05$). The average MDA level in both groups after treatment did not differ significantly ($P > 0.05$). Likewise, the average SOD antioxidants level in both groups after treatment did not differ significantly. Thus, the administration of aquabides and testosterone before and after treatment has the same effect on both average MDA and SOD levels. Paired sample t-test was performed to know the effect of administration of aquabides and testosterone on MDA and SOD level.

In the control group, there is an enhancement of the average MDA levels before and after treatment about 10.43 mmol/L and significantly different ($P < 0.05$). Average SOD levels are found to decrease about 237.89 μ /gHb, and significantly different ($P < 0.05$). In the case group, an enhancement of the average MDA levels before and after treatment was 10.29 mmol/L and significantly different ($P < 0.05$). Average SOD levels are found to decrease about 237.74 μ /gHb, and also significantly different by using paired sample t-test ($P < 0.05$).

The effect of aquabides and testosterone injection on corpus cavernous smooth muscle cells number (Table 1, Figure 7) shows its increment in the testosterone group significantly ($P < 0.05$) about 4-6 cells, whereas in the group given aquabides reduce it significantly ($P < 0.05$) as many as 6 cells.

DISCUSSION

Psychosocial Stress Causes Oxidative Stress

From preliminary research, it was found that oxidative stress induced by psychosocial stress for 4 hours/day occurred at the end of the first week of treatment. The timing of oxidative stress greatly depends on the type and duration of given stress. The exact mechanism how stress can increase free radicals is still unclear. But other studies have shown a strong relationship between stress, whether physical, metabolic, or psychosocial, and high free radicals in the blood. Psychological stress by pulling out rodent's whisker within 24 hours will increase oxidative stress characterized by increased carbonyl and TBARS.

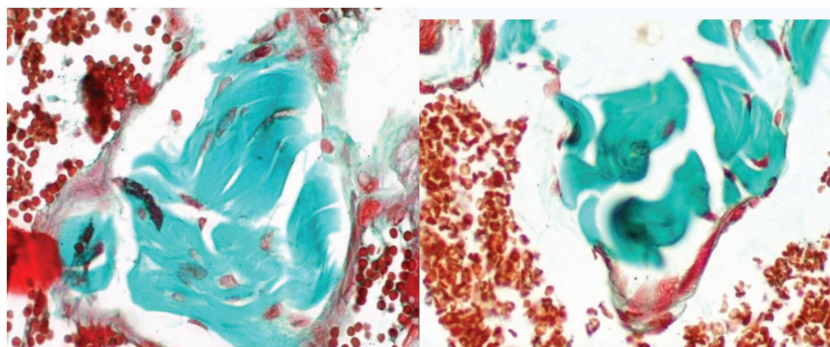


Figure 4 (Left) Corpus cavernosum smooth muscle cells number after the 3rd week of stress (40x). (Right) Corpus cavernosum smooth muscle cells number after the 6th week of stress + aquabides injection in an early 4th week (40x)

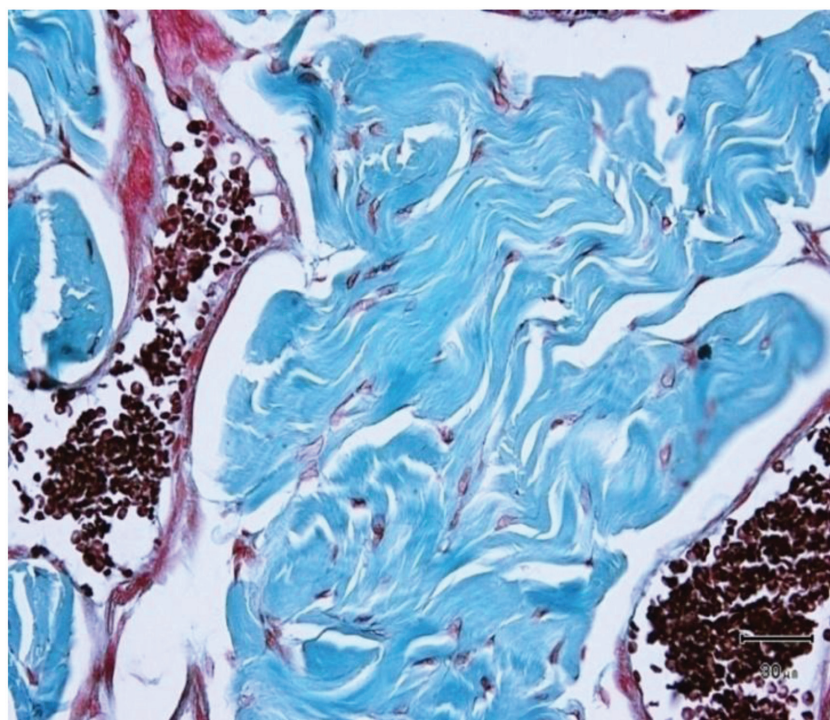


Figure 5 Corpus cavernosum smooth muscle cells number after the 6th week of stress + testosterone injection in an early 4th week (40x)

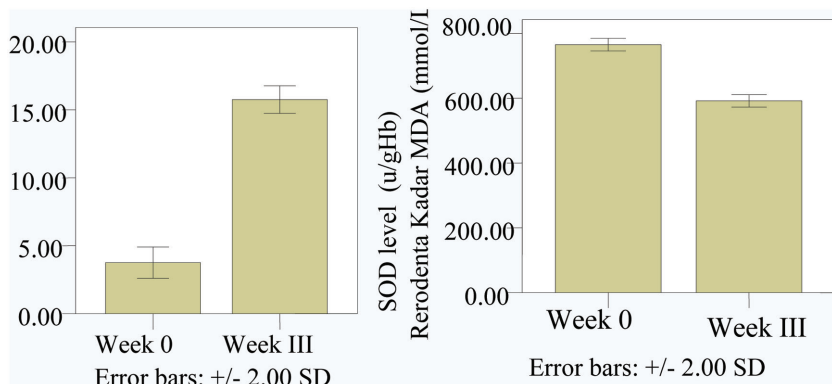


Figure 6 The average of MDA level, SOD level, and corpus cavernosum smooth muscle cell (CCSM) number before and after 3rd week induced by psychosocial stress (Note: from left to right, respectively)

Giving isolation stress in rodents will increased corticosteroid levels and induced oxidative stress in peripheral blood cell DNA on day-7 and day-30.¹⁹ Besides, there is association between stress and oxidant formation in rodents which is given immobilization stress by binding their four legs with plaster for 8 hours and they showed a significant rising of lipid peroxidation in the cortex and cerebellum.²⁶ Similarly, the emotional stress given to rodents induces the formation of reactive oxygen (SOR) compounds and oxidative damage to hepatic cells.²⁷

The intraperitoneal administration of CCl₄ in SD (*Sprague-Dawley*) rodents causes oxidative stress and liver damage within 24 hours. The damage is more increase with the higher doses given.²⁸ Providing physical stress by allowing rodents to swim 5 minutes/day for five days leads to oxidative stress, giving α -tocopherol before, during, and after stress can reduce oxidative stress.³⁰ The first evidence to show psychosocial stress that induced the rising of free radical formation and damage to DNA nuclei was found in studies of mouse liver cells which is given isolation stress. Stressed rodents showed an elevated 8-OH-dG in liver cell nuclear DNA after being given stress at the second, third and fourth hours and returned to normal about one hour after stressor is stopped.²⁸ The hormonal stress like epinephrine, norepinephrine, and cortisol can induce DNA damage to 3T3 mutant cells in vitro.³¹

Oxidative Stress Lowering Corpus Cavernosum Smooth Muscle Cells Number

The effect of oxidative stress on penile organs, especially on corpus cavernosum smooth muscle cells, had never been investigated before this research. Oxidative stress plays an essential role in the occurrence of endothelial dysfunction in blood vessels. Due to endothelial dysfunction, there will be both an increased vascular permeability and endothelial adhesion to leukocytes, leading to vascular congestion, edema, and extravasation of leukocyte cells. If this progression occurs longer than usual, it will be changed to natural cell death.³¹

Research on rodents who were subjected to NIDDM (Non-Insulin Dependent Diabetes Mellitus) by injecting long-term intraperitoneally streptozolisin 90 mg/kg showed oxidative stress on the penile tissue. It is evidenced by elevated MDA levels which are accompanied by decreased glutathione antioxidant levels in the penile tissue. Furthermore, it describes the rising of lipid peroxidation in the blood leads to degrading cell age, hypercoagulopathy, and increased adhesiveness to endothelium. In addition, enhanced glycation products from diabetes cause a tendency to accumulate in the walls of blood vessels and tissues that eventually cause endothelial damage during oxidative stress.³²

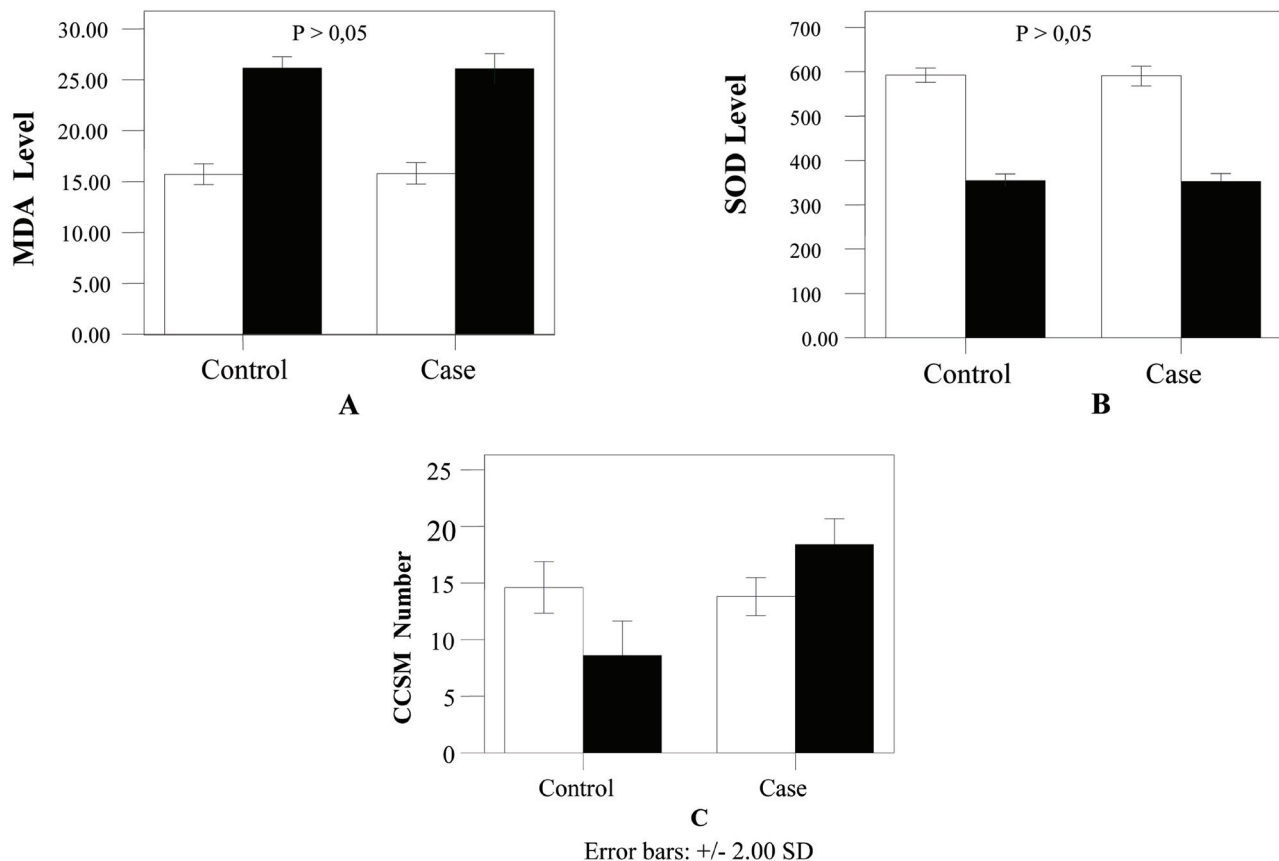


Figure 7 The diagrams show how the administration of aquabidesh (control) and testosterone (case) it is on MDA level (A) dan SOD antioxidant level (B), and corpus cavernous smooth muscle (CCSM) cell number (C). (Note: White bars = Before treatment; Black bars = after treatment)

Additionally, the hydrogen peroxide which is a redox signal molecule is essential to activate BFKB, Nrf2, and other transcription factors. The elevated hydrogen peroxide levels are associated with redox cell status that plays a role in the process of adaptation, proliferation, differentiation, apoptosis, and cellular necrosis.³³ Based on the above description can be shortly explained that the lowering of corpus cavernous smooth muscle cells numbers due to endothelial dysfunction caused by oxidative stress. But it must be proven first by looking at whether endothelial dysfunction has occurred in this study. Endothelial dysfunction is characterized by rising endothelial permeability resulting in congestion, edema, leukocyte cell build up, and disruption of the endothelium.³⁴

Administration of Testosterone Increases Corpus Cavernous Smooth Muscle Cells Number in Oxidative Stress State

Intramuscular injection of 0.018 mg of testosterone in rodents under oxidative stress conditions was able to increase corpus cavernous smooth muscle cells which are previously dropped in

oxidative stress. So the condition of oxidative stress does not affect the administration of the testosterone injections. Several studies linked the relationship between these two conditions. The castrated rodents show its enhancement characterized by elevation of 8-hydroxy-2'-deoxyguanosine (8-OHdG) in the cell nucleus and cell proteins damage with elevated 4-hydroxynonenal (HNE). Both biomarkers are specific to determine the presence of damage to epithelial cells of the prostate gland in the ventral lobes. Expression of the enzyme SOD₂, Gpx₁, Txn, and Prdx₃ in which as an antioxidant also decreases after castration. During the seven days of testosterone, the conditions of oxidative stress dropped, but after that, its condition increased again.³⁵

The association between oxidative stress conditions and testosterone administration is also demonstrated by a study of albino rodents. The albino rodents were given sodium fluoride 20 mg/kg BW/day to induce oxidative stress for 30 days.³⁶ Then, reproductive organs such as testes, prostate, epididymis and metabolic organs such as liver and kidneys are examined to determine the

effects of oxidative stress on the organ. Testosterone and vitamin E were administered intraperitoneally at a dose of 40 µg/100 grams a day, three hours after sodium fluoride, next vitamin E is administered at a dose of 20 mg/100 grams BW.

In the control group, arising oxidative stress characterized by elevated MDA levels and decreased catalase and peroxidase enzyme activities and decreased testiculo-somatic, prostato-somatic, and testiculosomatic index. Although the groups administered by testosterone, oxidative stress persists, but the testiculo-somatic, prostato-somatic, and testiculosomatic indexes are found to increase. The combination of testosterone and vitamin E improves oxidative stress condition and raises the testiculo-somatic, prostato-somatic, and testiculosomatic indexes. The hepato-somatic and reno-somatic index in the three groups did not differ significantly.³⁶

The physiologic dose of testosterone has a neuroprotective effect on primary cultures of human neuronal cells undergoing apoptosis due to the oxidative stress.³⁷ Primary culture of induced human neurons cells undergoes apoptosis by removing the serum. In addition, testosterone, methyltestosterone, and epitestosterone are given in physiological doses. The concentrations of androgen receptors are found about 8 ± 2 fmol/mg protein in the neuron culture. Its study explains that androgens induce neuroprotection directly throughout androgen receptors and its results also show that testosterone can be useful in the treatment of Alzheimer's disease in the aging process.^{37,38}

Provision of testosterone in rodents under oxidative stress conditions can increase corpus cavernous smooth muscle cells. The rising of its cell indicates that testosterone has a critical role in maintaining the structure and function of the trabecular. Research by castrating either through surgery or by drug administration in animals suggests that the decreasing of castrated androgens results in the atrophy of corpus cavernous trabecular and induces connective tissue stacking. Changes in the architecture of these tissues are associated with intracavernous pressure due to stimulation of the pelvic nerve.³⁸

Androgen depression causes unorganized corpus cavernous trabecular. It appears with many cytoplasmic vacuoles and less cytoplasmic miofilaments. In addition, the reduction of androgens leads to apoptosis, connective tissue stacking, and the differentiation of adipocytes from precursor cells. Reducing the ratio of smooth muscle cell count to connective tissue results in fibrosis that eventually

produces erectile dysfunction.⁸ Androgens regulate the differentiation of pluripotent cells into smooth muscle cells and inhibit their differentiation into adipocyte cells.^{39,40} Adipocyte cell stacking in the sub-natal region is the underlying cause of dysfunction of the occlusion vein. Thus, the rising of smooth muscle cells in this study is due to the differentiation of pluripotent cells into smooth muscle cells by testosterone administration, even under oxidative stress conditions.

Testosterone Doesn't Reduce Oxidative Stress

In one hand, testosterone in this study can't reduce oxidative stress happening due to psychosocial stress. It is supported by research that explains about the combination of testosterone enanthate (TE) and depo-medroxyprogesterone acetate (DMPA) as a contraceptive in SD rodents did not affect MDA concentrations and GSH concentrations in blood plasma.⁴¹ Otherwise, the effects of testosterone on peroxidation lipid levels and antioxidant status in the penile tissue need to be re-examined. Thus, the provision of testosterone can increase the number of corpus cavernous smooth muscle cells as compared with aquabides, although under oxidative stress conditions. Besides, the terms of oxidative stress that occurs in rodents do not affect the effects of testosterone.

CONFLICTS OF INTEREST

The author states there is no perceived conflict of interest regarding the presumption of innocence in the research report.

ACKNOWLEDGEMENT

The author would like to acknowledge The Center for Food Studies and Nutrition Graduate Program, Gadjah Mada University as the place for the examination of MDA, SOD, and rodent necropsies; Laboratory of Histology, Veterinary Department, Gadjah Mada University as the place for penile histopathological examination; and The Center of Veterinary Denpasar, Department of Agriculture, Directorodente General of Animal Husbandry on Raya Sesian Street No 266 as the place for counting cells as well.

REFERENCES

1. Dalle-Donne, I., Rossi, R., Colombo, R., Giustarini, D., and Milzani, A. Biomarkers of Oxidative Damage in Human Disease. *Clinical Chemistry* 2006; 52 (4): 601-623.

2. Wink, D.A., Feelisch, M., Fukuto, J., Christodoulou, D., Jourdain, D., Grisham, M.B., Vodovotz, Y., Cook, J.A., Krishna, M., DeGraff, W.G., Kim, S., Gamson, J., Mitchell, J.B. The Cytotoxicity of Nitroxy: Possible Implications for the Pathophysiological Role of NO. *Arch Biochem Biophys* 1998; 351: 66-74.
3. Evliyaoglu, Y., Kayrin, L., and Kaya, B. Effect of Pentoxifylline on Venous Occlusive Priapism-Induced Corporeal Tissue Lipid Peroxidation in Rodent Model. *Urol Res* 1997; 25: 143-147.
4. Rajasekaran, M., Hellstrom, W.J.G., and Sikka S.C. Nitric Oxide Induces Oxidative Stress and Mediates Cytotoxicity to Human Cavernosal Cells in Culture. *Journal of Andrology* 2001; 22: 34-39.
5. Kellogg, D.L., Zhao, J.L., Friel, C., Roman, L.J. Nitric Oxide Concentration Increases in the Cutaneous Interstitial Space during Heat Stress in Humans. *J Appl Physiol* 2003; 94: 1971-1977.
6. Leungwattanakij, S., Bivalacqua, T.J., Usta, M.F., Yang, D.Y., Hyun, J.S., Champion, H.C., Abdel-Majeed, A.B., and Hellstrom, W.J.G. Cavernous Neurotomy Causes Hypoxia and Fibrosis in Rodent Corpus Cavernosum. *J Androl* 2003; 24: 239-245.
7. Traish, A.M., Munarriz, R., O'Connell, L., Choi, S., Kim, S.W., Kim, N.N., Huang, Y.H., Goldstein, I. Effects of Medical or Surgical Castration on Erectile Function in An Animal Model. *Journal of Andrology* 2003; 24 (3): 381-387.
8. Traish, A.M., Toselli, P., Jeong, S.J., Kim, N.N. Adipocyte Accumulation in Penile Corpus Cavernosum of the Orchiectomized Rabbit: a Potential Mechanism for Venous Occlusive Dysfunction in Androgen Deficiency. *J Androl* 2005; 26: 242-248.
9. Traish, A.M., Goldstein, I., Kim, N.N. Testosterone and Erectile Function: From Basic Research to a New Clinical Paradigm for Managing Men with Androgen Insufficiency and Erectile Dysfunction. *Eur Urol* 2007; 52: 54-70.
10. Weissman, B.A., Sottas, C.M., Zhou, P., Iadecola, C., and Hardy, M.P. Testosterone Production in Rodents Lacking Inducible Nitric Oxide Synthase Expression is Sensitive to Restraint Stress. *Am J Physiol Endocrinol Metab* 2007; 292: E615-E620.
11. Dressler W. W., and Bindon J. R. Social Status, Social Context, and Arterial Blood Pressure. *American Journal of Physical Anthropology* 1997; 102:55-66.
12. Garruto, R.M., Little, M., James, G., and Brown, D. Natural experimental models: the global search for biomedical paradigms among traditional, modernizing and modern populations. *Proceedings of the National Academies of Science* 1999; 96:10536-10543.
13. Facchinetti, F., and Ottolini, F. 2004. Stress and Preterm Delivery. *Journal of Psychosomatic Obstetrics and Gynecology*, 25:1-2.
14. Rabin, D., Gold, P.W., Margioris, A.N., and Chrousos, G.P. 1986. Stress and Reproduction: Physiologic Interactions between the Stress and Reproductive Axis. New York: Plenum Press.
15. Bernatova, I and Csizmadiova, Z. Effect of Chronic Social Stress on Nitric Oxide Synthesis and Vascular Function in Rodents with Family History of Hypertension. *Life Sci* 2006; 78 (15): p. 1726-32.
16. Okruhlicova, L., Dlugosova, K., Mitasikova, M., Bernatova, I. Ultrastructural characteristics of aortic endothelial cells in borderline hypertensive rodents exposed to chronic social stress. *Physiological Research-Pre Press Article* 2006.
17. Sato, Y., Suzuki, N., Horita, H., Wada H., Shibuya, A., Adachi, H., Tsukamoto, T., Kumamoto, Y., and Yamamoto, M. Effects of Long-term Psychological Stress on Sexual Behavior and Brain Catecholamine Levels. *Journal of Andrology* 1996; 17 (2): 83-90.
18. Esquifino, A.I., Chacón, F., Jimenez, V., Reyes Toso, C.F., Cardinali, D. 24-Hour Changes in Circulating Prolactin, Follicle-Stimulating Hormone, Luteinizing Hormone and Testosterone in Male Rodents Subjected to Social Isolation. *Journal of Circadian Rhythms* 2004; 2: 1-6
19. Nishio, Y., Nakano, Y., Deguchi, Y., Terato, H., Ide, H., Ito, C., Ishida, H., Takagi, K., Tsuboi, H., Kinase, N., and Shimoi, K. Social Stress Induce Oxidative DNA Damage in Mouse Peripheral Blood Cells. *Genes and Environment* 2007; 29; 17-22.
20. Wardana, I.N.G. 2009a. Stres Psikososial Menyebabkan Terjadinya Stres Oksidatif pada Minggu Pertama Perlakuan. Penelitian Pendahuluan. Program Magister Ilmu Biomedik UNUD.
21. Wardana, I.N.G. 2009b. Pemberian Injeksi Testosteron tidak Mampu Meredam Stres Oksidatif yang Terjadi pada Tikus yang Mendapatkan Stres Psikososial. Penelitian Pendahuluan. Program Magister Ilmu Biomedik UNUD.
22. Wardana, I.N.G. 2009c. Pemberian Injeksi Testosteron Mempertahankan Jumlah Sel Otot Polos Corpus Cavernosum Penis Tikus. Penelitian Pendahuluan. Program Magister Ilmu Biomedik UNUD.
23. Campbell, D.T., and Stanley, J.D. 1968. Experimental and Experiment Quasi Experimental Design for Research. Chicago.
24. Conti, M., Moramd, P.C., Lecillain, P., Lemonnier, A. Improve Fluorimetric Determination of Malonaldehyde. *J Clin Chem* 1991; 37 (7): 1273-1275.
25. Randox CE Laboratories Ltd. 2006. RANSOD. 182-183.
26. Liu, J., Wang, X., Shigenaga, M.K., Yeo, H.C., Mori, A., Ames, B.N. Immobilization Stress Causes Oxidative Damage to Lipid, Protein, and DNA in the Brain Of Rodents. *FASEB J* 1996; 10: 1532-1538.
27. Adachi, S., Kawamura, K., and Takemoto, K. Oxidative Damage of Nuclear DNA in Liver of Rodents Exposed to Psychosocial Stress. *Cancer Research* 1993; 53 (18): 4153-4155.
28. Panjaitan, R.G.P., Handharyani, E., Chairul, Masriani, Zakiah, Z., and Manalu, W. Pengaruh Pemberian Karbon Tetraklorida Terhadap Fungsi Hati dan Ginjal Tikus. *Makara Kesehatan* 2007; 11 (1): 11-16.
29. Wresdiyanti, T., Astawan, M., Fithriani, D., Adnyane, K.M., Novelina, S., and Aryani, S. tt. Pengaruh α -Tokoferol Terhadap Profil Superoksida Dismutase dan Malondialdehida pada Jaringan Hati Tikus di Bawah Kondisi Stres. *Jurnal Veteriner*.
30. Flint, M.S., Baum, A., Chambers, W.H., and Jenkins, F.J. Induction of DNA Damage, Alteration of DNA Repair and Transcriptional Activation by Stress Hormones. *Psychoneuroendocrinology*. 2007; 32: 470-479.
31. Lum, H., and Roebuck, K.A. Oxidant Stress and Endothelial Cell Dysfunction. *Am J Physiol Cell* 2001; 280: C719-C741.
32. Ji-Kan Ryu., Dae-Jong K., Lee, T., Yun-Seog, K., Sang-Min, Y., and Jun-Kyu, S. The Role of Free Radical in the Pathogenesis of Impotence in Streptozotocin-Induced Diabetic Rodents. *Yonsei Medical Journal* 2003; 44 (2). 236-241.
33. Packer, L, and Cadenas, L. Oxidative stress and Disease. In: Packer, L, and Sies, H (editors). Oxidative Stress and Inflammatory Mechanism in Obesity, Diabetes, and the Metabolic Syndrome. *CRC Press* 2008; 12-16
34. McQuaid, K.E. and Keenan, A.K. Endothelial Barrier Dysfunction and Oxidative Stress: Roles for Nitric Oxide. *Experimental Physiology* 1997; 82: 369-376.
35. Tam, N. T. C., Ying, G., Yuet-Kin, L., and Shuk-Mei, H. Androgen Regulation of Oxidative Stress in the Rodent Prostate. *American Journal of Pathology* 2003; 163: 2513-2522
36. Sarkar, A. D., Maiti, R., and Ghosh, D. Induction of Oxidative Stress on Reproductive and Metabolic Organs in Sodium Fluoride-Treated Male Albino Rodents: Protective Effect of Testosterone and Vitamin E Coadministration. *Informa Healthcare* 2005; 15: 271-277.
37. Hammond, J., Le, Q., Goodyer, C., Gelfand, M., Trifiro, M., and LeBlanc, A. X Testosterone-Mediated Neuroprotection through the Androgen Receptor in Human Primary Neurons. *J Neurochem* 2005; 77 (5): 1319-1326.

38. Bivalacqua, T.J., Usta, M.F., Champion, H.C., Kadowitz, P.J., Hellstrom, W.J. Endothelial dysfunction in erectile dysfunction: role of the endothelium in erectile physiology and disease. *J Androl* 2003; 24: S17-S37.
39. Bhasin, S., Taylor, W.E., Singh, R., Artaza, J., Sinha-Hikim, I., Jasuja, R., Choi, H., Gonzalez-Cadavid, N.F. The Mechanism of Androgen Effects On body composition: mesenchymal pluripotent cell as the target of androgen action. *J Gerontol* 2003; 58: M1103-M1110.
40. Singh, R., Artaza, J.N., Taylor, W.E., Gonzalez-Cadavid, N.F., Bhasin, S. Androgen Stimulate Myogenic Differentiation and Inhibit Adipogenesis in C3H 10T1/2 Pluripotent Cells Through an Androgen Receptor-Mediated Pathway. *Endocrinology* 2003; 144: 5081-5088.
41. Panghiyangani, R. dan Suhartono, E. tt. Pengaruh Kontrasepsi Hormonal Pria Kombinasi Testosteron Enantat (TE) dan Depo Medroksi Progesteron Asetat (DMPA) Terhadap Pembentukan Radikal Bebas. Available at: [Http: //Biologiweb.Files.Wordpress.Com/2008/10/Kontrasepsi-Te-Dmpa.Doc](http://Biologiweb.Files.Wordpress.Com/2008/10/Kontrasepsi-Te-Dmpa.Doc)



This work is licensed under a Creative Commons Attribution