MANAGEMENT OF PEDIATRIC MUSCULOSKELETAL TRAUMA

Ketut Siki Kawiyana

Orthopaedi & Traumatology Subdivision Udayana University

Sanglah General Hospital, Denpasar-Bali

INTRODUCTION

- Over the past 2 decades, the number of musculoskeletal injuries sustained by children and adolescents has increased markedly.
- This may reflect an increasing use of motorized and high-speed wheeled vehicles among this population

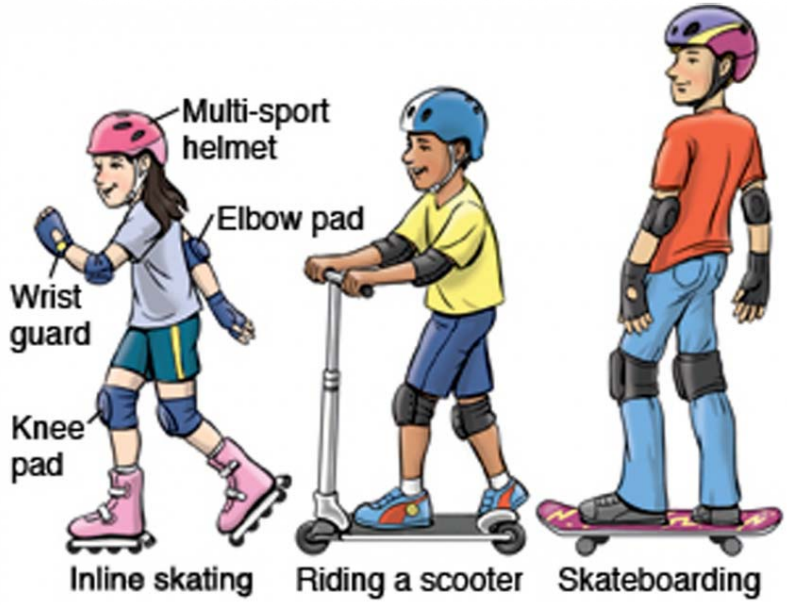

Walter W. Huurman, MD* and Glen M. Ginsburg, MD. Musculoskeletal Injury in Children. *Pediatrics in Review Vol. 18 No. 12 December 1997*

INTRODUCTION

It is important to recognize the basic skeletal differences between children and adults

The common signs and symptoms of fractures, sprains, strains, and dislocations

The initial treatment and stabilization of these injuries in children.

Walter W. Huurman, MD* and Glen M. Ginsburg, MD. Musculoskeletal Injury in Children. *Pediatrics in Review Vol. 18 No. 12 December 1997*

JOURNAL OF CLINICAL ORTHOPAEDICS AND TRAUMA 6 (2015) 12–18

Available online at www.sciencedirect.com

ScienceDirect

journal homepage: www.elsevier.com/locate/jcot

Original Article

The clinical profile of musculoskeletal injuries in children attending a major hospital in Delhi, India

Sumit Sural M.B.B.S, M.S(Orth.)[a,*], *Anu Verma M.B.B.S, M.D*[b]

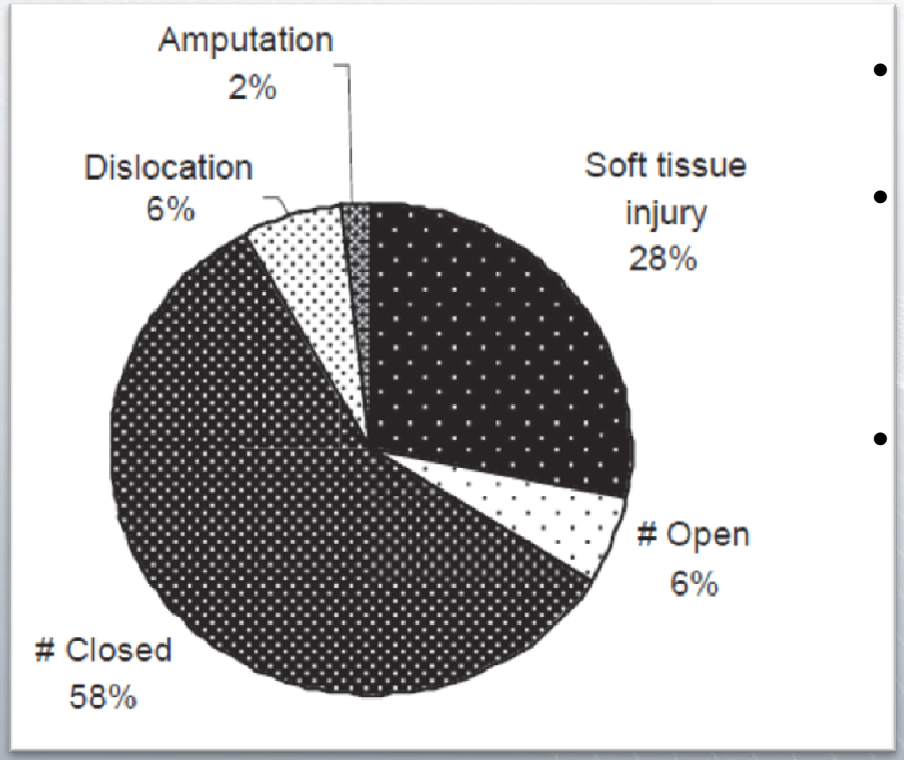

- Injuries in children were found to be preventable.
- Small interventions while constructing homes can contribute tremendously to injury prevention and control in children.
- Parental awareness about the various modes of injury

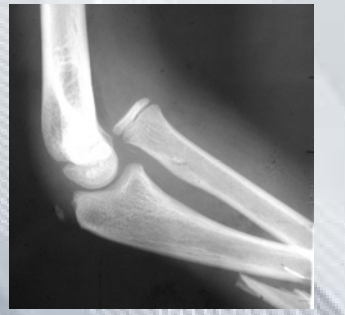

Special Considerations In The Child

- Children **“are not little adults”**.
- They are different: **structurally, physiologically, neurologically and psychologically.**
- There are: **significant differences in the type of injuries sustained by children compared to adults.**

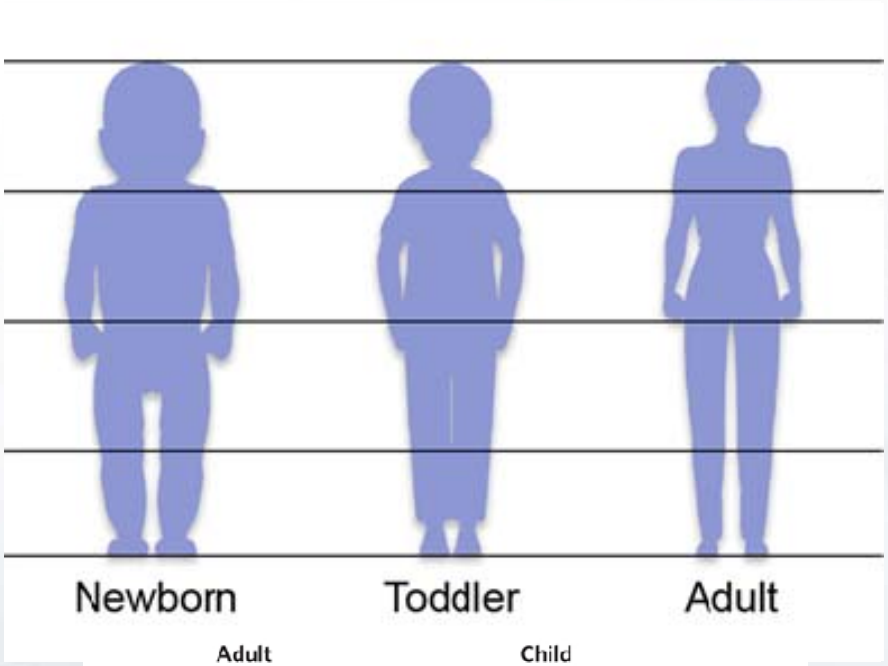

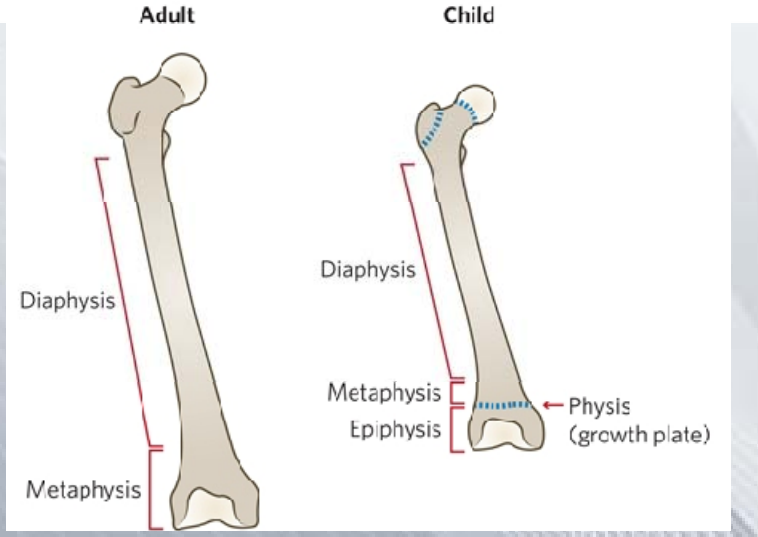

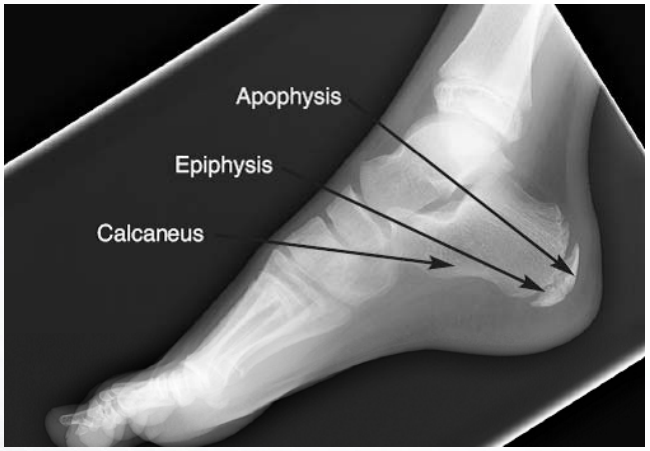

Special Considerations In The Child

- **The 'pubertal (also termed adolescent)** growth spurt' is a time of accelerated growth
  - Increased height and body mass → the incidence of sport and exercise related injury ↑↑
- **Apophyses** (sites of tendon attachment) are cartilaginous plates that are sites of growth
  - They are relatively weak and vulnerable to either macro-trauma (acute injury; avulsion) or micro-trauma (repetitive overuse) termed **'apophysitis',** which is very common.
  - The apophysis is the so called 'weakest link' in the musculo-tendinous unit in children
- **The epiphyseal plate (or 'physis')** is the growth plate between the metaphysis and the epiphysis
  - are very vulnerable to injury (macro-trauma or micro-trauma).

- Unique Anatomic Features
  - Physis
  - Epiphysis
  - Apophysis
  - Metaphysis
  - Diaphysis

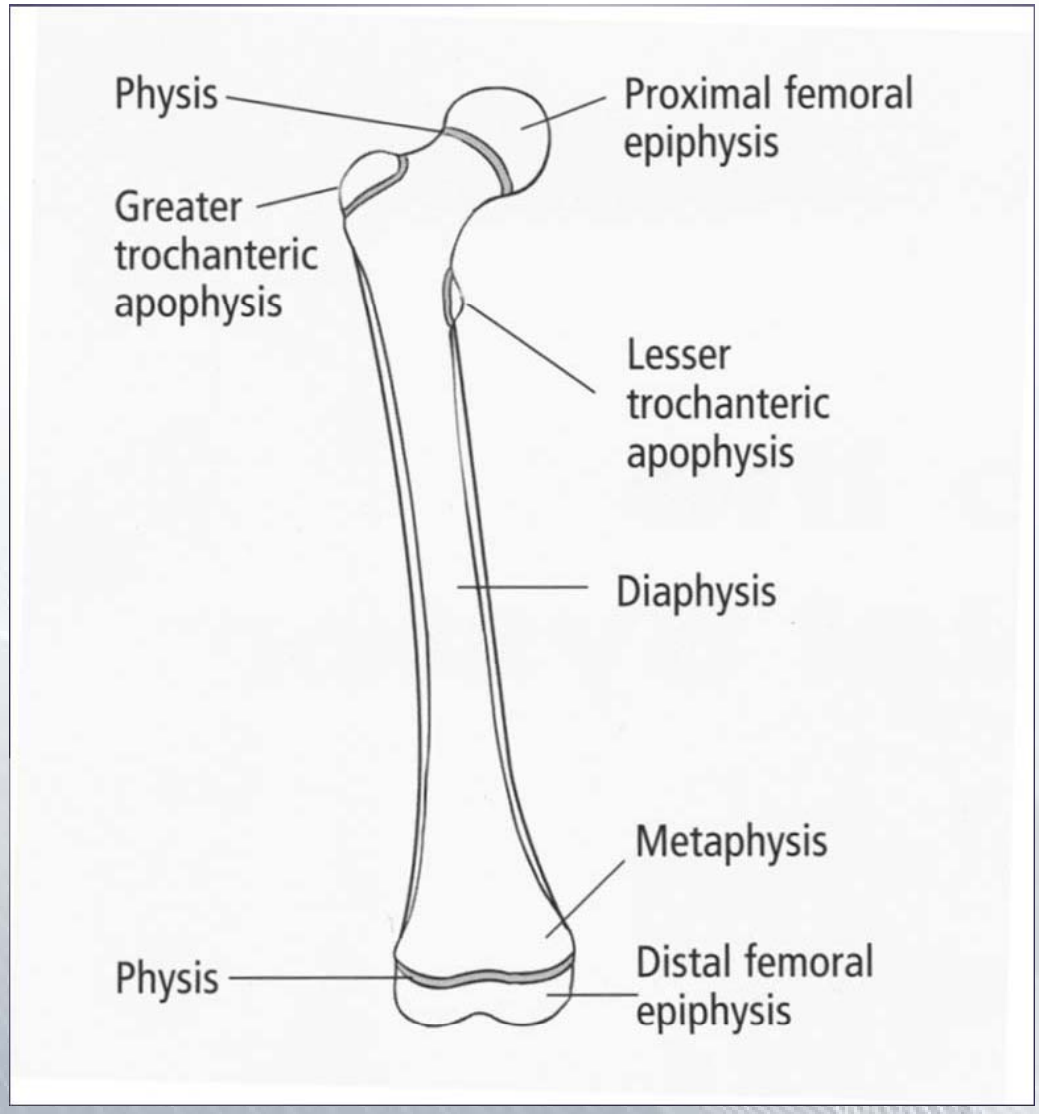

Injuries in adults compared to children

Site	Mechanism	Injury in Adult	Injury in Child
Knee	Twisting/valgus force	Anterior cruciate ligament (ACL) disruption, +/-meniscal injury	Avulsion tibial spine origin of ACL, fracture distal femoral or proximal tibial epiphysis
Knee	Overuse	Patellar tendinopathy	Osgood–Schlatter, SLJ disease
Shoulder	Fall	Acromio-clavicular joint disruption	Fracture distal clavicle epiphysis
Shoulder	Fall	Dislocated Gleno-humeral joint	Fracture proximal humeral epiphysis
Thumb	Valgus force	Ulnar collateral ligament disruption	Fracture proximal phalangeal epiphysis
Thigh/Hip	Acute flexor/extensor strain	Quadriceps or hamstring strain	Apophyseal avulsion of anterior inferior iliac spine or ischial tuberosity
Heel	Overuse	Achilles tendinopathy	Sever's apophysitis

SOFT TISSUE AND JOINT INJURY

SOFT TISSUE AND JOINT INJURY

(MUSCLE, TENDON, LIGAMENT)

Strains

- muscular injuries caused by excessive stretching that result in pain and swelling of that muscle.

Sprains

- caused by overstretch and partial tearing of a ligament.

Subluxation

- incomplete separation of a joint in which there still is partial contact between each bone's articular cartilage.

Dislocation

- complete separation in which all contact is lost between articular surfaces

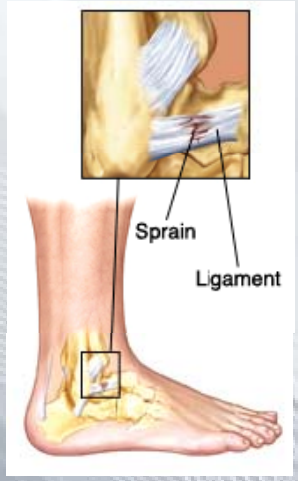

Pathophysiological responses of Soft Tissue Healing

- Bleeding phase
- Inflammatory phase
- Proliferative phase
- Remodelling phase

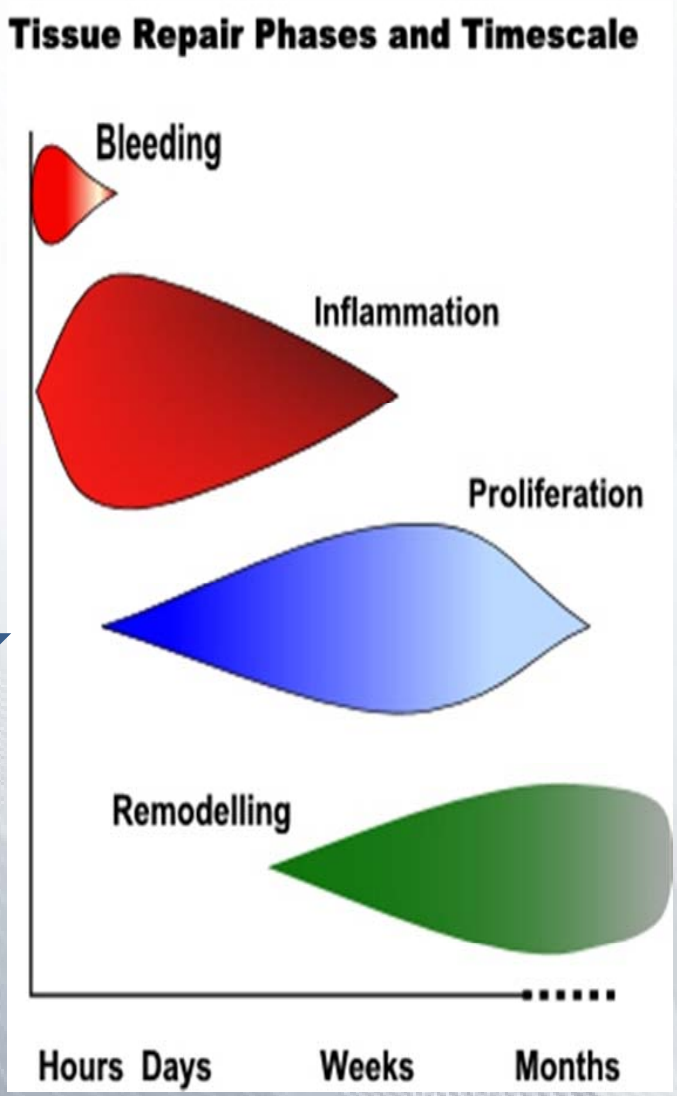

Clinical classification of muscle strains (traditional)

Delayed onset muscle soreness	•Mildest form •Muscle fibers are not torn
Mild (Grade I)	•Tear of only few muscle fibers with minor swelling and discomfort •Minimal loss of strength and restriction of the movement •Ability to mobilize
Moderate (Grade II)	•Greater damage of muscle •Clear loss of function •Ability to contract
Severe (Grade III)	•Tear extends across the entire cross-section of the muscle •Complete loss of muscle function

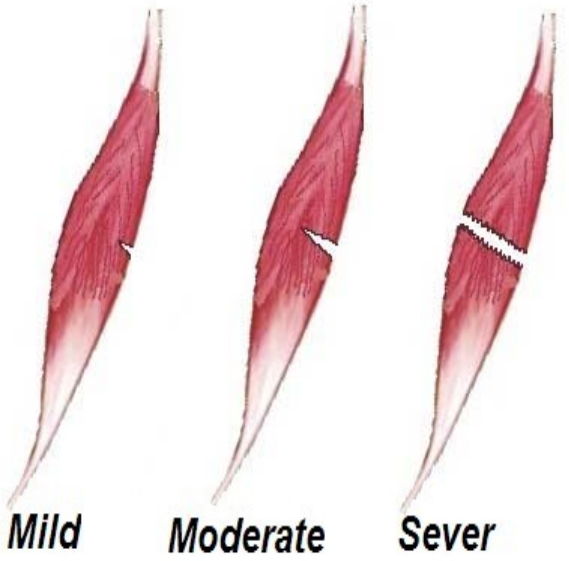

Healing of strain Injury

Destruction phase :

- ruptured myofiber become necrotized only over a short distance
- “Fire door”, a contraction band formed within a couple of hours, in the shelter of which the rupture is sealed by new sarcolemma
- Gap between stumps is filled by a hematoma

Repair phase

- Begins with phagocytosis of the necrotized tissue by blood derived monocytes
- Satelite cells are activated and begin the repair of the breached myofiber
- Myoblast are form within couple of days
- Injured sites are revascularied by ingrowing capillaries

Remodeling phase

- Formation of a mature contractile apparatus
- Attachment of the ends of the regenerated myofibers to the intervening scar by newly form MTJs
- Contraction of the large granulation to scar tissue is driven by fibroblasts , transforming to the myofibroblasts.

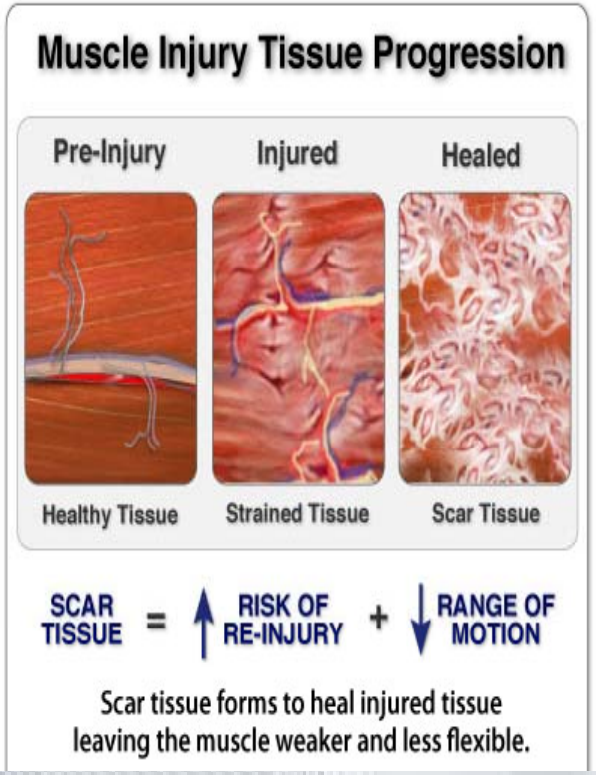

Regeneration of shearing injury

A. Torn Myofiber

B. Contraction band and demarcation membrane seal the torn fiber ends. Satelite cells begin to proliferate and inflammation reaction begins.

C. SCs differentiate into myoblasts and fibroblasts begin to produce collagens

D. Myoblasts fuse into myotubes

E. Myotubes fuse with the surviving parts of the torn fibers and start to form new MTJs.
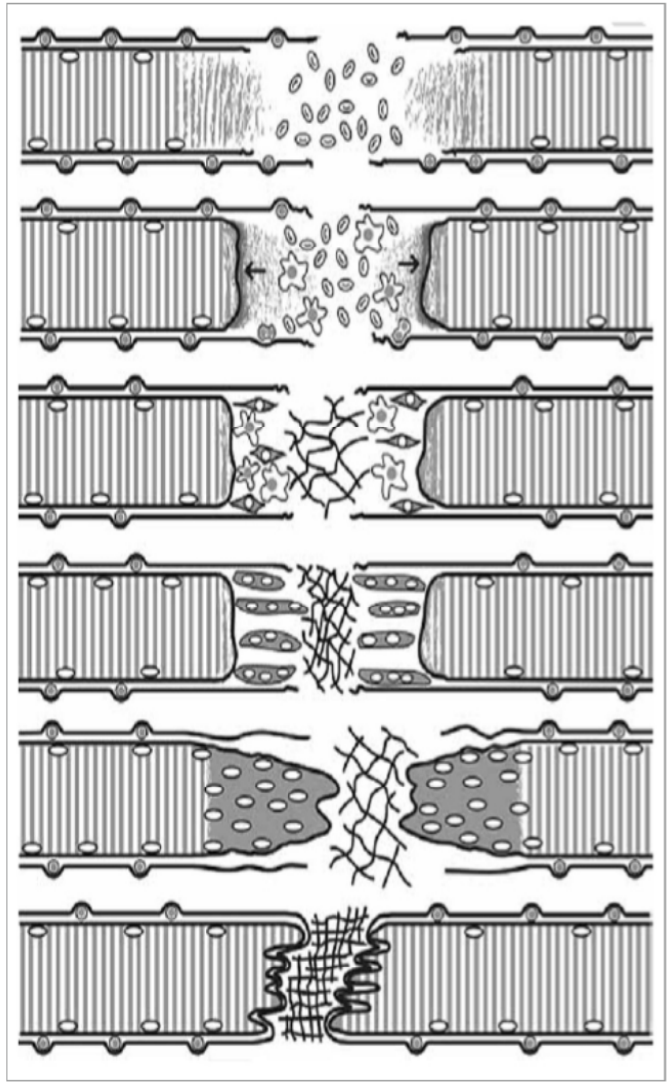
F. Fully regenerated fiber with organized scar tissue and MZTJs attached to it