



Published by DiscoverSys

A coexistence of pemphigus vulgaris and type II diabetes in geriatric patient: A case report



CrossMark

Nyoman Suryawati,* I Gusti Ayu Agung Praharsini,
Made Wardhana, I Gusti Nyoman Darmaputra

ABSTRACT

Background: Pemphigus Vulgaris (PV) is an autoimmune bullous disorder that usually affected the middle-aged and elderly. PV management in elderly patients is still a challenge for clinicians because of an increased risk of developing diabetes in the elderly. Corticosteroid is the first-line treatment for PV; however, careful consideration should be taken for diabetes patients due to the risk of disrupting glucose control leading to acute decompensation.

Case: A seventy-year-old female with type II diabetes reported to Sanglah General Hospital with multiple painful blisters on the chest, back, and oral mucous. She has been treated with insulin since last year, but the treatment was non-compliant. Dermatological examination

showed multiple flaccid bullae containing serous fluid with a positive Nikolsky sign, and multiple skin erosions. Histopathology finding is appropriate with PV. The Tzank smear examination revealed acantholytic cells. She was diagnosed with PV and typed II diabetes; therefore, we treated her with azathioprine, insulin and Lantus injection; sodium chloride 0.9% compress and fusidic acid cream 2% twice daily for topical treatment.

Conclusion: Azathioprine is the treatment of choice because it works by blocking DNA replication without increasing blood glucose levels. The selection of appropriate medications can improve patient prognosis.

Keywords: *Pemphigus Vulgaris, treatment, azathioprine*

Cite This Article: Suryawati, N., Praharsini, I.G.A.A., Wardhana, M., Darmaputra, I.G.N. 2020. A coexistence of pemphigus vulgaris and type II diabetes in geriatric patient: A case report. *Bali Medical Journal* 9(1): 314-317. DOI: [10.15562/bmj.v9i1.1643](https://doi.org/10.15562/bmj.v9i1.1643)

Department of Dermatology and Venereology, Faculty of Medicine, Universitas Udayana, Sanglah General Hospital, Bali, Indonesia

INTRODUCTION

Pemphigus Vulgaris (PV) is a rare group of autoimmune bullous disorders, with an incidence of 2-10 cases per one million population in some areas of the world and a prevalence of 0.1-0.7 per one hundred thousand population.¹ The peak incidence of PV occurs between the fourth and sixth decades of life, with a male-to-female ratio of 1:2.^{1,2} The human immune system at the beginning of the sixth decade of life undergoes dramatic aging-related changes, which continuously progress to a state of immunosenescence.³ Immunosenescence manifests as increased susceptibility to infections, increased prevalence of cancer, autoimmune, and other chronic diseases characterized by a pro-inflammatory state, such as atherosclerosis and diabetes mellitus.^{4,5}

PV was a highly fatal disease until the introduction of corticosteroids, which have reduced its mortality rate from 75% to less than 10%, with most morbidity and mortality today due to iatrogenic causes rather than the disease itself.^{2,6} PV management in the elderly patient with diabetes is still a challenge for clinicians. Corticosteroid, which is the first-line treatment for PV, should be carefully considered in diabetes patients due to the risk of disrupting glucose control leading to acute decompensation.⁷ We will report a coexistence of PV and

type II Diabetes in a geriatric patient, which focuses on the management of the patient.

CASE

A seventy-year-old female reported to Sanglah General Hospital with multiple painful blisters on the chest, back, and oral mucous in the past month. She has no history of fever, upper respiratory tract infection, or pain during urination before the complaint. History of skin rash in the past and within her family was denied. She has been diagnosed with type II diabetes and treated with insulin in the past year, and the treatment was uneventful.

Physical examination showed the good general condition, blood pressure 120/80 mm Hg, respiratory rate 20x/minute, temperature 36.5°C, with visual analog scale (VAS) score of 2. Dermatological examination showed multiple flaccid bullae containing serous fluid with a positive Nikolsky sign, and multiple skin erosions (Figure 1-3).

The Tzank smear examination found acantholytic cells (Figure 4). Laboratory examination such as routine blood test, renal function, and liver function test were within normal range; an increase of fasting glucose (433 mg/dl) and blood glucose 2 hours postprandial (588 mg/dl). Glycated hemoglobin (hemoglobin A1c/ HbA1C). Histopathology

*Correspondence to:
Nyoman Suryawati, Department of Dermatology and Venereology, Faculty of Medicine, Universitas Udayana, Sanglah General Hospital, Bali, Indonesia
suryawati@unud.ac.id

Received: 2019-10-24
Accepted: 2020-03-15
Published: 2020-04-01

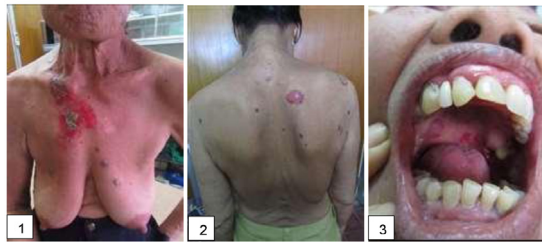

Figure 1-3 Clinical manifestation in the chest and back showed multiple flaccid bullae containing serous fluid with multiple erosions and positive Nikolsky sign (1 and 2); Clinical manifestation in oral mucous showed multiple erosion (3)

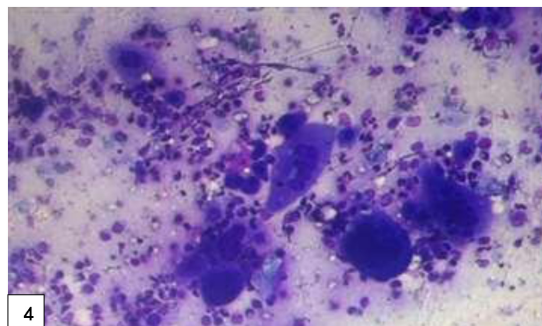


Figure 4 Tzank smear examination showed acantholytic cell

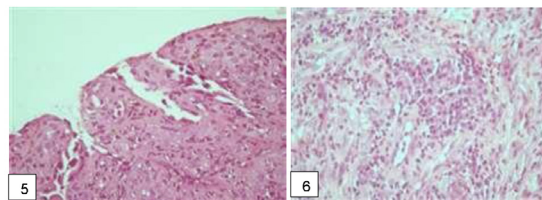


Figure 5-6 The histopathologic finding revealed suprabasal blister with acantholytic cells with inflammatory infiltrate containing polymorphonuclear cells, neutrophils, plasma cells, and lymphocytes that is appropriate with PV

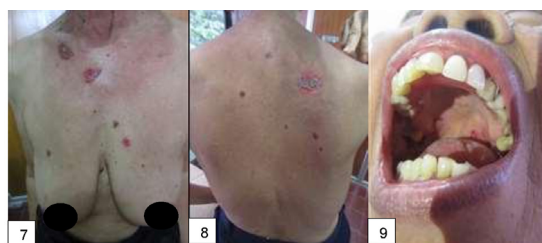

Figure 7-9 Clinical manifestation in the chest, back, and oral mucous after one month of treatment

finding revealed suprabasal blister with acantholytic cells with inflammatory infiltrate containing polymorphonuclear cells, neutrophils, plasma cells, and lymphocytes that were appropriate with PV (Figure 5-6).

She was diagnosed with PV and typed II diabetes. She has been treated with azathioprine 100 mg daily, insulin injection 12 IU three times daily, Lantus injection 14 IU at bedtime, sodium chloride 0.9% compress, and fusidic acid cream 2% twice daily for topical treatment. She showed a good clinical response after a one-month treatment (Figure 7-9).

DISCUSSION

The clinical manifestation of PV is characterized by a flaccid blister on the skin and mucous membrane. Patients can present with painful ulcerations, especially in buccal or palatine mucous, but it can also present in the nose, genitals, anus, esophagus, and conjunctiva.⁸ In most cases of PV, oral lesions (50-70%) can predominantly precede lesions in the skin. The characteristic finding in PV is that erosion can be extended into visibly normal skin by pulling the remnant of the blister wall or rubbing at the periphery of the active lesion. The erosions also can be induced in normal-appearing skin distant from active lesions by pressure or mechanical shear force, which is known as Nikolsky sign.⁹ A smear taken from the base of a blister or on the oral lesion (Tzank preparation) contains acantholytic cells.¹⁰ The characteristic finding in PV is a suprabasal blister with acantholysis with a feature of a row tombstone. In the early phase, eosinophilic spongiosis may be evident.^{9,10}

The diagnosis of PV in our case was based on a painful ulcer in oral mucous and painful blister on the skin with a positive Nikolsky sign. The Tzank smear examination found acantholytic cells. The histopathological result showed a suprabasal blister with acantholytic cells that are appropriate with PV.

Skin bullae in PV patients tend to rupture because the cellular interconnections are weakened by the autoimmune attack on desmoglein (Dsg) 1, and 3.⁸ Pathogenesis of PV includes targeting desmosomal proteins (pemphigus antigens) by immunoglobulin G (IgG) antibodies to produce the formation of intraepithelial, mucocutaneous blisters.^{1,6} Oral epithelium mostly expresses Dsg 3, whereas skin expresses Dsg 1.¹ When autoantibodies damage Dsg 3, it will cause initial phase oral lesions. However, if damage occurs in Dsg 1, skin lesions will appear, and the disease tends to become

more severe.⁹ Disruption of this autoantigen by the antigen-antibody reaction has a marked effect on the integrity of the epidermis resulting in cellular detachment (acantholysis), suprabasal clefting, and subsequent bullae formation. Several cytokines such as interleukin (IL)-4, IL-6, IL-10, tumor necrosis factor (TNF)- α , and enzymes (phospholipase or proteinase) are released by T-lymphocytes that propagate this tissue reaction and subsequent tissue injury.¹¹

The peak incidence of PV occurs between the fourth and sixth decades of life.^{1,2} As age advances, the immune system undergoes profound remodeling and decline, with a major impact on health and survival.¹² Aging is associated with declines in adaptive and innate immunity.¹³ The aging immune system fails to maintain full tolerance to self-antigens, with an increased incidence of autoimmune diseases.^{4,5,12} The increase of autoimmune diseases is probably due to lymphopenia occurring with age, leading to excess homeostatic lymphocyte proliferation, as well as a decrease in regulatory T-cell function and decreased of apoptotic cells clearance by macrophages.¹²

Type II diabetes or non-insulin dependent diabetes mellitus (NIDDM) is a heterogeneous disorder caused by a combination of genetic factors related to insulin secretion, insulin resistance, and environmental factors such as obesity, overeating, lack of exercise, stress, and aging. The incidence of diabetes increases with age, with most cases being diagnosed after the age of 40.¹⁴ Aging contributes to type II diabetes through impaired β -cell function and impaired β -cell adaptation to insulin resistance leading to impaired insulin secretion.¹⁵ The aging process can be accompanied by a low-grade chronic inflammatory reaction characterized by increased levels of cytokines and pro-inflammatory markers. Among pro-inflammatory cytokines, TNF- α , IL-1, and IL-6 seem to inhibit insulin signaling and increase insulin resistance and risk of type II diabetes.^{5,15}

Systemic Corticosteroid is the first-line therapy for PV because of effectiveness in remission induction and maintenance of remission.⁶ Corticosteroid, which is the first-line treatment for PV, should be carefully considered in diabetes patients due to the risk of disrupting glucose control leading to acute decompensation.⁷ Corticosteroids-induced hyperglycemia is a well-known adverse effect of glucocorticoid treatment that could occur in both diabetic and non-diabetic patients.¹⁶ The steroid can elevate blood glucose levels by increasing hepatic glucose production and inhibiting glucose uptake into muscles. The steroid also has a complex effect on β -cell function.¹⁷ Strategies to reduce

the risk of steroid side effects in diabetes patients are augmenting or starting insulin or other oral antidiabetic, or splitting the dose of corticosteroids.¹⁶ Adjuvant treatments have been introduced as steroid-sparing agents such as azathioprine, mycophenolate mofetil, methotrexate, cyclophosphamide, cyclosporin, and dapsone.¹¹

Azathioprine is an effective adjunctive immunosuppressive agent for PV, with clinical remission rates of approximately 50% in a retrospective study.⁹ Azathioprine was the most commonly prescribed adjuvant agent used to treat PV and can be used as monotherapy in mild cases.^{6,11} Azathioprine is a synthetic purine analog derived from 6-mercaptopurine. It is a purine antagonist, and its active metabolites (6-thioguanine) act by disrupting the function of endogenous purines. Mechanism of azathioprine's immunosuppressive activities is inhibiting the synthesis of DNA, RNA, and proteins; it may also interfere with cellular metabolism and inhibit mitosis. It reversibly reduces the number of monocytes and Langerhans cells, impairs γ -globulin synthesis and T-cell lymphocyte function, and may affect the responses of B cells that depend on helper T cells and the function of suppressor B cells.¹⁸

The complexity of diabetes and its management requires a collaborative effort by a team of health care providers, which may include physicians, nurse practitioners, nurses, dietitians, pharmacists, social workers, and mental health professionals. Lifestyle interventions, including physical activity, and mild-moderate weight loss, are the first-line intervention for diabetes prevention and treatment of hyperglycemia in older people.¹⁵ Our case showed a good response with azathioprine 100 mg daily, the combination of insulin and Lantus injection, also sodium chloride 0.9% compress and fusidic acid cream twice daily. The patient was also suggested changing her lifestyle, such as nutrition intake and physical activity.

CONCLUSION

PV management in the elderly patient with diabetes is still a challenge for clinicians. The treatment choice for this condition is azathioprine, which has the mechanism of action by blocking DNA replication without increasing glucose level. The selection of appropriate medications can improve patient prognosis.

CONFLICT OF INTEREST

There is no competing interest regarding the manuscript.

FUNDING

None.

AUTHOR CONTRIBUTION

All the authors are responsible for the study from the conceptual framework.

REFERENCES

- Handa H. A Comprehensive Review on Pemphigus Vulgaris. *Biomedical Journal of Scientific & Technical Research*. 2017; 1: 1796–9.
- Dimarco C. Pemphigus: Pathogenesis to Treatment. *Rhode Island Medical Journal*. 2016; 28: 28–31.
- Weyand CM, Goronzy JJ. Aging of the Immune System. Mechanisms and Therapeutic Targets. *Annals of the American Thoracic Society*. 2016 Dec; 13(Supplement_5): S422–8.
- Ponnappan S, Ponnappan U. Aging and Immune Function: Molecular Mechanisms to Interventions. *Antioxidant and Redox Signaling*. 2011; 8: 1551–85.
- Castelo-Branco C, Soveral I. The immune system and aging: a review. *Gynecological Endocrinology*. 2014; 30(1): 16–22.
- Harman KE, Brown D, Exton LS, Groves RW, Hampton PJ, Mohd Mustapa MF, et al. British Association of Dermatologists' guidelines for the management of pemphigus vulgaris 2017. *British Journal of Dermatology*. 2017; 177(5): 1170–201.
- Jannot-Lamotte M, Raccah D. Management of diabetes during corticosteroid therapy. *Presse Med*. 2000; 29: 263–6.
- Sanders WJ. A brief review of pemphigus vulgaris. *Biomedical Dermatology*. 2017; 1: 1–7.
- Payne A, Stanley J. Pemphigus. In: Kang S, Amagai M, Bruckner A, Enk A, Margolis D, McMichael A, et al., editors. *Fitzpatrick's Dermatology*. Ninth. New York: Mc Graw Hill Education; 2019. p. 909–33.
- Wojnarowska F, Venning V. Immunobullous Diseases. In: Burns T, Breathnach S, Cox N, Griffiths C, editors. *Rook's Textbook of Dermatology*. Eight. Wiley-Blackwell; 2010. p. 40.1-40.23.
- Ganapathy S, Vedam V, Rajeev V, Arunachalam R. Autoimmune Disorders – Immunopathogenesis and Potential Therapies. *Journal of Young Pharmacists*. 2017 Jan 10; 9(1): 14–22.
- Simon AK, Hollander GA, McMichael A. Evolution of the immune system in humans from infancy to old age. *Proceedings of the Royal Society B: Biological Sciences*. 2015 22; 282(1821): 20143085.
- Fuentes E, Fuentes M, Alarcón M, Palomo I. Immune System Dysfunction in the Elderly. *Anais da Academia Brasileira de Ciências*. 2017; 89(1): 285–99.
- Ozougwu O. The pathogenesis and pathophysiology of type 1 and type 2 diabetes mellitus. *Journal of Physiology and Pathophysiology*. 2013; 4(4): 46–57.
- Lee PG, Halter JB. The Pathophysiology of Hyperglycemia in Older Adults: Clinical Considerations. *Diabetes Care*. 2017; 40(4): 444–52.
- Habib G, Dar-Esaif Y, Bishara H, Artul S, Badarny S, Chernin M, et al. The impact of corticosteroid treatment on hemoglobin A1C levels among patients with type-2 diabetes with chronic obstructive pulmonary disease exacerbation. *Respiratory Medicine*. 2014; 108(11): 1641–6.
- Simmons LR, Molyneaux L, Yue DK, Chua EL. Steroid-Induced Diabetes: Is It Just Unmasking of Type 2 Diabetes? *ISRN Endocrinology*. 2012; 2012: 1–5.
- Meurer M. Immunosuppressive therapy for autoimmune bullous diseases. *Clinics in Dermatology*. 2012; 30(1): 78–83.



This work is licensed under a Creative Commons Attribution