

### Vol. 19 No. 1, Maret 2018

- Karakteristik tipe diabetes akibat induksi deksametasone ●
- Gambaran patologi mencit tripanosomiasis pascaterapi ●  
ekstrak daun kipahit
- Ekstrak kulit buah naga menurunkan induksi tumor mammae ●
- Salep daun sirih merah untuk terapi luka miasis ●
- Ekstrak terung asam & temu kunci atau terung asam & lempuyang, ●  
menekan *A. hydrophila* dan *Pseudomonas*
- Ekstrak bakau api-api putih hambat mikrob patogen ●  
pada larva udang windu
- Senyawa antibakteri pada katak papua ●
- Morfometri limpa codot krawar (*Cynopterus brachyotis*) ●
- Ekspresi hyaluronan pascavitrifikasi oosit matang dan belum matang ●
- Anak-anak babi turunan induk yang disuntik gonadotropin ●
- The comparison of various technique for diagnosis of demodecosis ●
- Prevalensi paramphistomosis pada sapi bali di Papua Barat ●
- Peningkatan kadar lemak tidak jenuh susu sapi setelah ransum ●  
diimbahi minyak jagung
- Bius tetes infus gravimetrik ketapol pada babi ●
- Karakteristik Gen Sitokrom Lebah Liar Apis cerena ●  
Asal Pulau Hoga Sulawesi Tenggara
- Limfosit, Monosit, dan Basofil Sapi Bali yang Digembalakan ●  
di Tempat Sampah Kota
- Penanganan obstruksi duodenum pada anjing ●
- Urolith surgical removal in green iguana ●



AFP Foto/Muhammad Agus Salim

Ketika musim duren memuncak di bulan Februari-Maret, bukan hanya manusia yang suka duren, harimau sumatra pun menyukai duren. Memanfaatkan cakarinya, harimau dengan mudah membelah duren runtuh. Mungkin duren itu yang membuatnya masuk kampung di Mandailing Natal Sumut atau karena habitatnya telah dirusak. Sempat dijuluki harimau jadi-jadian, sang raja rimba pun diuber masuk hutan sampai masyarakat menemukan goa persembunyiannya. Tak berapa lama, harimau masuk kampung lagi tanpa menyadari masyarakat telah mempersenjatai dirinya dengan tombak. Masyarakat Desa Hatupangan, Kecamatan Batang Natal, Mandailing Natal, Sumatra Utara menombak sang raja rimba hingga tewas Minggu 4 maret 2018. Jasadnya digantung dan dipertontonkan. Petugas yang sempat mau membantu warga menghalau harimau dilarang masuk desa dan bahkan disandera dan diintimidasi. Diduga ada ilegal logging dibalik itu semua sehingga masyarakat begitu tega menghabisi satwa yang terancam punah dan dilindungi.

**PEMIMPIN UMUM** : I WAYAN BATAN DEWAN REDAKSI : NYOMAN MANTIK ASTAWA (KETUA), IDA BAGUS ARKA, NYOMAN SADRA DHARMAWAN, IWAN H. UTAMA, I GUSTI NGURAH KADE MAHARDIKA, I KETUT PUJA, I KETUT SUATHA, TJOK GDE OKA PEMAYUN, ROOSTITA L. BALIA, I KETUT BERATA, AIDALOUISE TENDEN ROMPIIS, GUSTIAYU YUNIATI KENCANA REDAKTUR PELAKSANA : I NYOMAN SUARTHA & I G M KRISNA ERAWAN, **SEKRETARIS REDAKSI** : I NYOMAN SUARSANA. **STAF REDAKSI** : I WAYAN SUARDANA, I GUSTI NGURAH SUDISMA, NI GUSTI AGUNG AYU SUARTINI, I MADE SUKADA, ANAK AGUNG SAGUNG KENDRAN, ANAKAGUNG AYU MIRAHADI, I MADE KARDENA, YANA QOMARIANA. **TATA USAHA** : WERDI SUSARI, PUTU AYU SISYAWATI PUTRI NINGSIH. **KANTOR REDAKSI & ALAMAT SURAT** : KLINIK HEWAN FKH UNUD, Jl. Raya Sesetan Gg. Markisa 6 Banjar Gaduh, Denpasar - Bali. **PENERBIT** : FAKULTAS KEDOKTERAN HEWAN, UNIVERSITAS UDAYANA BEKERJA SAMA DENGAN PERHIMPUNAN DOKTER HEWAN INDONESIA. **REKENING** : NOMOR 0118628705 A/N dth. I NYOMAN SUARTHA, M.Si BNI CABANG DENPASAR DICETAK OLEH: PERCETAKAN PELAWA SARI, JL. ANTOSURA 33 DENPASAR

Setiap naskah yang dikirim ke redaksi untuk dipublikasikan dalam Jurnal Veteriner dipandang sebagai karya asli penulis dan bila diterima, naskah tersebut tidak diperkenankan dipublikasikan lagi secara keseluruhan ataupun sebagian tanpa seijin Jurnal Veteriner.

Naskah Asli  
 Original Article

<p><b>RAHMANIA HANIM, HUDA SHALAHUDIN DARUSMAN, MIN RAHMINIWATI</b>                  Studi Karakteristik Tipe Diabetes pada Tikus                  (<i>Rattus novergicus</i>) yang Diinduksi Deksametason                  (CHARACTERISTIC STUDY OF THE TYPE OF DIABETES IN RAT (<i>RATTUS NOVERGICUS</i>)                  MODEL INDUCED BY DEXAMETHASONE) .....</p>	1-10
<p><b>SUTIASTUTI WAHYUWARDANI, APRIL H WARDHANA,                  DIDIK T SUBEKTI, DHARWIN SISWANTORO</b>                  Gambaran Patologi Infeksi <i>Trypanosoma evansi</i> pada Mencit Pascapengobatan                  dengan Ekstrak Ethanol Daun Kipahit (<i>Tithonia diversifolia</i>)                  (PATHOLOGIC FEATURES OF TRYPANOSOMA EVANSI INFECTION AFTER BEING TREATED                  WITH ETHANOLIC EXTRACT OF KIPAHT LEAVES (<i>TITHONIA DIVERSIFOLIA</i>) .....</p>	11-22
<p><b>MUHAMMAD THOHAWI ELZIYAD PURNAMA, RAGIL ANGGA PRASTIYA,                  FAISAL FIKRI, AMUNG LOGAM SAPUTRO, BODHI AGUSTONO</b>                  Ekstrak Etanol Kulit Buah Naga Menurunkan Indikasi Neoplasia Mammarum                  Tikus Putih Berdasarkan Histopatologi dan <i>Inhibitor Siklooksigenase-2</i>                  (DRAGON FRUIT ETHANOL EXTRACT REDUCES INDICATIONS OF WHITE RAT                  NEOPLASIA BASED ON HISTOPATHOLOGY AND CYCLOOXYGENASE-2 INHIBITORS) .....</p>	23-29
<p><b>SUS DERTHI WIDHYARI, IETJE WIENTARSIH, AULIA ANDI MUSTIKA,                  APRIL HARI WARDHANA, DODI DARMAKUSUMA, LINA NOVIYANTI SUTARDI,                  MUHAMMAD BINTANG</b>                  Potensi Salep Ekstrak Daun Sirih Merah Terhadap Profil Eritrogram                  Sebagai Terapi pada Luka Miasis                  (THE EFFECT OF RED BETEL LEAF EXTRACT OINTMENT IN ERYTHROGRAM                  PROFILES AS THERAPY IN MYIASIS WOUND) .....</p>	30-34
<p><b>ESTI HANDAYANI HARDI, GINA SAPTIANI, NURKADINA,                  IRAWAN WIJAYA KUSUMA, WIWIN SUWINARTI</b>                  Uji In Vitro Gabungan Ekstrak <i>Boesenbergia pandurata</i>, <i>Solanum ferox</i>,  <i>Zingiber zerumbet</i> terhadap Bakteri Patogen pada Ikan Nila                  (IN VITRO TEST OF CONCOCTION PLANT EXTRACTS OF BOESENBERGIA PANDURATA,                  SOLANUM FEROX, ZINGIMBER ZERUMBET AGAINST PATHOGENIC                  BACTERIA IN TILAPIA) .....</p>	35-44
<p><b>GINA SAPTIANI, ANDI NOOR ASIKIN, FIKRI ARDHANI, ESTI HANDAYANI HARDI</b>                  Tanaman Bakau Api-api Putih (<i>Avicennia marina</i>) Berpotensi Menghambat                  Mikrob Patogen dan Melindungi <i>Post Larva</i> Udang Windu                  (THE POTENTIAL OF AVICENNIA MARINA TO INHIBITS PATHOGEN MICROBES                  AND PROTECTS THE POST LARVA OF TIGER PRAWN) .....</p>	45-54
<p><b>MARIA MASSORA, ELDA IRMA J. J. KAWULUR*, HERMAWATY ABUBAKAR</b>                  Uji Aktivitas Senyawa Antibakteri Katak Papua                  (ANTIBACTERIAL ACTIVITY TEST OF PAPUAN FROGS) .....</p>	55-61
<p><b>DESRAYNI HANADHITA, ANDHIKA YUDHA PRAWIRA, ANISA RAHMA,                  ARYANI SISMIN SATYANINGTIJAS, SRIHADI AGUNGPRIYONO</b>                  Morfometri Limpa Berkaitan dengan Produksi Radikal Bebas dan Antioksidan                  pada Kelelawar Pemakan Buah Codot Krawar (<i>Cynopterus brachyotis</i>)                  (MORPHOMETRIC STUDY OF SPLEEN ASSOCIATED WITH FREE RADICAL PRODUCTION                  AND ANTIOXIDANT DEFENSE IN THE LESSER SHORT-NOSED FRUIT BATS                  (<i>Cynopterus brachyotis</i>)) .....</p>	62-70
<p><b>ZAKIYATUL FAIZAH, R. HARYANTO ASWIN, HAMDANI LUNARDHI, WIDJIATI</b>                  Hyaluronan Expression on Vitriified Oocytes Before and After In Vitro Maturation                  (EKSPRESI HYALURONAN PADA OOSIT YANG DIVITRIFIKASI                  SEBELUM DAN SESUDAH MATURASI IN VITRO) .....</p>	71-75

- FRISKA MONTOLALU, ANITA ESFANDIARI, DAMIANA RITA EKASTUTI, WASMEN MANALU**  
 Kondisi Neonatus Anak Babi yang Dilahirkan oleh Induk yang Disuntik Gonadotropin  
 Sebelum Pengawinan  
*(THE NEONATE CONDITIONS OF PIGLETS BORN FROM SOW  
 INJECTED WITH GONADOTROPIN PRIOR TO MATING)*..... 76-84
- I NYOMAN SUARTHA, WILLY MORIS NAINGGOLAN,  
 YEKHONYA REHUEL SIDJABAT, NI MADE RESTIATI**  
 The Comparison of Scraping, Trichogram, and Taping Techniques for Diagnosis  
 of Demodicosis in Dog  
*(PERBANDINGAN TEKNIK SCRAPING, TRICHOGRAM, DAN TAPING  
 DALAM MENDIAGNOSIS DEMODEKSOSIS PADA ANJING)*..... 85-90
- PURWANINGSIH, NOVIYANTI, RIZKI PRATAMA PUTRA**  
 Prevalensi dan Faktor Risiko Paramphistomiasis  
 pada Sapi Bali di Distrik Prafi, Kabupaten Manokwari, Provinsi Papua Barat  
*(PREVALENCE AND RISK FACTORS OF PARAMPHISTOMIASIS BALI CATTLE IN PRAFI  
 DISTRICT, MANOKWARI REGENCY, WEST PAPUA PROVINCE)* ..... 91-99
- DANES SUHENDRA, SUDJATMOGO, WIDIYANTO**  
 Pengimbangan Minyak Jagung Terproteksi dengan Berbagai Level Protein Ransum Sapi  
 Friesian Holstein Meningkatkan Kadar Asam Lemak Tidak Jenuh Susu  
*(CORN OIL PROTECTED SUPPLEMENTATION WITH VARIOUS OF PROTEIN LEVEL  
 ON FRIESIAN HOLSTEIN COW DIET FOR MILK UNSATURATED FATTY ACID LEVEL)* ..... 100-108
- I NYOMAN TIRTA ARIANA, ANAK AGUNG OKA, I GEDE SURANJAYA, I KETUT BERATA**  
 Peningkatan Limfosit, Monosit, dan Basofil pada Sapi Bali yang Digembalakan  
 di Tempat Pembuangan Akhir Sampah Kota Denpasar  
*(THE ELEVATION LEVEL OF LIMPLOCYTE, MONOCYTE, AND BASOPHIL  
 ON BALI CATTLE GRAZING AT WASTE DISPOSAL CITY OF DENPASAR)*..... 109-115
- SURIANA, JAMILI, PARAKKASI**  
 Karakteristik Gen Sitokrom C Oksidase Sub Unit I (CO1) Lebah Liar *Apis cerena*  
 (Hymenoptera: apidae) Asal Pulau Hoga Sulawesi Tenggara  
*(CHARACTERISTICS OF GEN CYTOCHROME C OXIDASE SUBUNIT I (CO1) WILD BEES  
 Apis cerena (Hymenoptera: Apidae) FROM THE HOGA ISLAND OF SOUTH EAST SULAWESI)* .. 116-125
- I GUSTI AGUNG GDE PUTRA PEMAYUN, I GUSTI NGURAH SUDISMA**  
 Anestesi Tetes Infus Gravimetrik Ketapol sebagai Alternatif Bius Umum Secara  
 Inhalasi Guna Menjaga Status Anestesi pada Babi  
*(THE GRAVIMETRIC INFUSION ANAESTHESIA WITH KETAPOL AS AN ALTERNATIVE  
 GENERAL INHALATION ANESTHESIA TO MAINTANACE  
 ANESTHESIA STATUS ON PIGS)* ..... 126-136
- ERWIN, RUSLI, AMIRUDDIN, DENI NOVIANA, RADEN RORO SOESATYORATIH,  
 ARNI DIANA FITRI<sup>1</sup>, SITARIA FRANSISKA SIALLAGAN**  
 Penanganan Obstruksi Duodenum pada Anjing: Laporan Kasus  
*(TREATMENT OF DUODENUM OBSTRUCTION IN DOGS: CASE REPORTS)* ..... 137-142
- PUVEANTHAN NAGAPPAN GOVENDAN, I GUSTI MADE ANANTHAWIJAYA,  
 ANAK AGUNG GEDE JAYAWARDITHA**  
 Case Report : Urolith Surgical Removal in a Green Iguana (*Iguana iguana*)  
*(LAPORAN KASUS : BEDAH PENGELUARAN BATU KANTUNG KEMIH  
 PADA SEEKOR IGUANA HIJAU (IGUANA IGUANA))* ..... 143-147
- PEDOMAN BAGI PENULIS** ..... i

# The Comparison of Scraping, Trichogram, and Taping Techniques for Diagnosis of Demodicosis in Dog

(*PERBANDINGAN TEKNIK SCRAPING, TRICHOGRAM, DAN TAPING DALAM MENDIAGNOSIS DEMODEKSOSIS PADA ANJING*).

I Nyoman Suartha<sup>1\*</sup>, Willy Moris Nainggolan<sup>2</sup>,  
Yekhonya Rehuel Sidjabat<sup>2</sup>, Ni Made Restiati<sup>2</sup>

<sup>1</sup>Laboratory of Veterinary Internal Medicine,  
Faculty of Veterinary Medicine, Udayana University  
Jl Sudirman, Denpasar, Bali, Indonesia

<sup>2</sup>Bali Veterinary Clinic  
Jl Pantai Prerenan, Banjar Delod Padonan  
Mengwi, Badung, Bali, Indonesia  
Email: nyoman\_suartha@unud.co.id

## ABSTRACT

Demodicosis is a parasitic disease which is predilected in skin. Demodicosis in dogs may present local or general clinical symptoms. The success of demodicosis treatment is highly dependent on dog immune conditions, nutritional status, disease status, and routine treatment. The success of the treatment is also affected by the accuracy in the diagnostic technique used. The purpose of this study was to compare the three diagnostic skin examination techniques namely scraping, trichogram, and taping to diagnose cases of demodicosis. A total of 20 dog samples was taken from dog patients that came to Bali Veterinary Clinic, at Prerenan, Badung, Bali, with symptoms of itching, hair loss, skin redness, scale, and hyperpigmentation. Sampling was done by technique of scraping, trichogram, and taping. Scraping technique was done by scraping the skin, trichogram technique was done by pulling hair, and taping technique was done by attaching the tape. The result of *Demodex* mite isolation from the three diagnostic techniques performed showed scraping technique  $5.45 \pm 1.05$ ; trichogram technique  $1.10 \pm 0.91$ ; and taping technique  $3.50 \pm 0.83$  dogs. Its Concluded that scraping technique provides the best diagnostic value for the isolation of *Demodex* mites compared to the other two.

Keywords: scraping; trichogram; taping; diagnostic; demodexosis; dog

## ABSTRAK

Demodeksosis adalah penyakit parasit dengan tempat predileksi pada kulit. Demodeksosis pada anjing dapat menampakkan gejala klinis lokal atau general. Keberhasilan pengobatan demodeksosis sangat tergantung atas kondisi imun anjing, status nutrisi, status penyakit, dan pengobatan yang rutin. Keberhasilan pengobatan juga dipengaruhi keakuratan dalam teknik diagnostik yang digunakan. Tujuan penelitian ini adalah membandingkan tiga teknik diagnostik pemeriksaan kulit yaitu *scraping*, *trichogram*, dan *taping* dalam mendiagnosis kasus demodeksosis. Sebanyak 20 ekor sampel anjing diambil dari pasien anjing yang datang ke Bali Veterinary Clinic, di Prerenan, Badung, Bali, dengan gejala gatal, kerontokan rambut, adanya kemerahan kulit, kulit berketombe atau bersisik (*scale*), dan hiperpigmentasi. Pengambilan sampel dilakukan dengan teknik *scraping*, *trichogram*, dan *taping*. Teknik *scraping* dilakukan dengan mengerok kulit, teknik *trichogram* dilakukan dengan mencabut rambut, dan teknik *taping* dilakukan dengan penempelan selotip. Hasil isolasi tungau *demodeks* dari ketiga teknik diagnosis yang dilakukan menunjukkan teknik *scraping*  $5,45 \pm 1,05$ , teknik *trichogram*  $1,10 \pm 0,91$ , dan teknik *taping*  $3,50 \pm 0,83$  ekor. Disimpulkan teknik *scraping* memberikan nilai diagnostik terbaik untuk mengungkap adanya tungau *demodeks*.

Kata-kata kunci: scraping; trichogram; taping; diagnosis; demodeksosis; anjing.

## INTRODUCTION

Demodicosis is a parasitic disease caused by *Demodex* mite which is predilected in skin. The diseases firstly reported in year 1842 (Sastre *et al.*, 2012). Normally *Demodex* mites live in dog skin (Fondati *et al.*, 2010; Ravera *et al.*, 2013). This mite can transmit from mother to puppies during lactation period in 2-3 days old (Miller *et al.*, 2013). There are three strain of *Demodex* who infected dog i.e. *Demodex canis* (Hillier *et al.*, 2002), *D. coneis* (Carlotti *et al.*, 2006), and *D. injai* (Sastre *et al.*, 2012). Clinical sign of demodicosis in dog are in local and general form. Local demodicosis is a lesions which find in less than six locations, with diameter less than 2.5cm, while, general demodicosis is a lesion which find in 12 or more locations and even in all body parts (head, face and body) (Miller *et al.*, 2013). However, no absolute definitions are agreed to define the shape of local and general lesions of demodicosis (Waisglass, 2015). Isolation of blood biomarkers i.e. serum C-reactive protein level and haptoglobin, can be used as an indicator that demodicosis is general (Martinez-Subiela *et al.*, 2014).

Juvenile demodicosis is a disease found in small races dogs under 12 months, under 18 months of age in large breeds, and less than two years of age in giant dog races. While, demodicosis is categorized in adult dogs if the dog has never suffered from skin problems since the dog was born until the dog was four years old (Waisglass, 2015). These groupings often have difficulty when the medical record of the dog is not recorded completely.

The success of demodicosis treatment depends on the isolation of the causative agent, and the introduction of clinical demodicosis at the location of the body first attacked (Saridomichelakis *et al.*, 2007). Other factors determining the success of demodicosis treatment are immune dog conditions, nutritional status, disease status, and routine therapy (Ferrer *et al.*, 2014). Cooperation and understanding of the owner is necessary because treatment requires a longer time and intensive (Waisglass, 2015). Early onset of infection also affects the speed of cure of demodicosis treatment. In dogs that have suffered from demodicosis since juvenile require longer treatment period, compared to dogs suffering from demodicosis as adults.

Rapid, easy, and simple diagnostic techniques of demodicosis are necessary in veterinary practice. The speed of diagnosis

provides a good added value for practitioners in veterinary medical services. The technique of scraping and trichogram is a common way of diagnosis of demodicosis (Saridomichelakis *et al.*, 2007). One other demodicosis diagnostic technique that can be used is taping (Pereira *et al.*, 2012). This paper would like to compare the implementation of three diagnostic techniques in diagnosing cases of demodicosis at the veterinary practice. The purpose of this study was to compare the three diagnostic skin examination techniques namely scraping, trichogram, and taping to diagnose cases of demodicosis.

## RESEARCH METHODS

The samples were taken from dog patients who came to Bali Veterinary Clinic, Prerenan, Badung-Bali. Patients used as samples were those who had skin problems and showed symptoms of itching, hair loss, skin redness, scale and hyperpigmentation. Sampling was performed at three different sites of the lesion (head, body, and leg). At each location sampling was done with all three diagnostic techniques (scraping, trichogram, and taping). The number of dogs taken were 20 samples, without regard to gender, age, and race.

### Scraping Technique

Scraping was done by using scalpel blade. Prepare; mineral oil dripped in the middle of the glass object. Area of the skin sampled, massage with finger and thumb as much as 10 times, and continue when doing scraping. Avoid cutting skin when doing scraping. Scraping was done on the skin until it bleeds. Samples are placed on mineral oil droplets on glass objects. The skin scrap sample was flattened with a syringe needle, covered with a glass cover and observed under a light microscope with 400x magnification. Note the number of mites, eggs, and *Demodex* larvae observed (Saridomichelakis *et al.*, 2007).

### Trichogram Technique

In areas of the skin that indicate a lesion, the hair on it was removed with the forefinger and thumb. Prepare an object glass and spilled mineral oil on it. Removed hair was placed on mineral oil droplets and then spread and flattened with a syringe needle. Cover the object glass with the cover glass then examined under a light microscope with 400x magnification. Note

the number of mites, eggs, and *Demodex* larvae observed (Beco *et al.*, 2007).

**Taping Technique**

Tapping was done by using clear tape with length 6 cm and width 2 cm. In the area of the skin that have lesion, massage with finger and thumb as much as 10 times. Press the sticky side of the tape firmly to the skin area to be sampled. Pinch up the taped skin and place fingers on top of the tape; roll and squeeze the skin firmly, as if trying to squeeze the follicle contents onto the sticky portion of the tape. Remove the tape and place sticky side down onto the object glass. Examined the sample under a light microscope with 400x magnification. Note the number of mites, eggs, and *Demodex* larvae observed (Pereira *et al.*, 2012). Data of *Demodex* mites obtained were analyzed with SPSS 13 for windows program.

**RESULT AND DISCUSSION**

The mean number of *Demodex sp* mites observed in each field of view of microscope, respectively; technique of scraping, trichogram, and taping was  $5.45 \pm 1.05$ ;  $1.10 \pm 0.91$ ;  $3.50 \pm 0.83$ . The results of *Demodex sp* mite isolation, each data of the three diagnostic techniques are presented in Table 1.

Demodicosis is a skin disorder that takes a long time and perseverance in the treatment. The inaccuracy of the diagnostic technique used has an effect on the accuracy of the diagnosis of demodicosis. Difficulties in the diagnosis also due to clinical symptoms caused by demodicosis often overlap with other diseases that attack the skin. Symptoms become less specific if there is a secondary infection of bacteria. Inexpensive, quick, and easy diagnostic techniques for isolation of *Demodex* mites are scraping, trichogram and taping (Saridomichelakis *et al.*, 2007; Beco *et al.*, 2007; Fondati *et al.*, 2010). Another technique that can be used is biopsy (Fondati *et al.*, 2010) and isolation techniques from feces (Waisglass, 2015). Biopsy techniques are more difficult and take longer time. When making histologic preparations in biopsy techniques, *Demodex* mites are often frequently drift.

In this study, dogs used as samples showed symptoms of itching, hair loss, skin redness, scale, and hyperpigmentation (Fig 1 a-b). Of the three techniques used, all were able to isolate

Table 1. Average number of *Demodex* mites isolated from all three diagnostic techniques

Technique	Number of sample	Average Number of <i>Demodex</i>
Scraping	20	$5.45 \pm 1.05^a$
Trichogram	20	$1.10 \pm 0.91^b$
Taping	20	$3.50 \pm 0.83^c$

the demodex mite (Fig 2 a-c). Scraping technique obtained the most *Demodex* mite isolation, which was significantly different from two other techniques ( $P < 0.05$ ). In the scraping technique can also be isolated eggs and pupa of *Demodex* mites (Fig 3 a-c). This can be due to the help of massage and scraping the skin until bloody. Massage helps release *Demodex* mites from the keratin tissue of the hair follicle. Scrape until it bleeds as a scrape marker until the dermis layer of the skin, the predilection site of the *Demodex* mite (Beco *et al.*, 2007).

In the trichogram technique found the least amount of *Demodex* mites. This can be caused by *Demodex* mites still left in the skin during hair removal process. In the trichogram technique was not recommended to do hair root massage, so keratin on the hair root is not released, which is where the predilection of *Demodex* mite (Beco *et al.*, 2007). Trichogram was less sensitive than scraping when mite infestation is low (Saridomichelakis *et al.*, 2007). However, if a *Demodex* mite is found, it can't be indicated as a normal condition (Fondati *et al.*, 2010). Further examination is needed. It was reported that for the isolation of *Demodex* mite in dogs is more difficult than isolating *Demodex* mite in humans, so isolation of a single human *Demodex* mite may be indicated as a normal condition.

In taping technique found fewer *Demodex* mites than scraping methods and more from the trichogram technique. In taping technique was also done a massage on the skin before sampling process, so that the mites in the dermis layer rise to surface and taped to the tape used. In the taping technique was not followed by scraping the skin, so that mites that are still more deep in the skin can't be attached to tape. Taping techniques can be used as an alternative to replace scraping techniques (Pereira *et al.*, 2012; Miller *et al.*, 2013). Taping techniques can isolate *Demodex canis* in dogs more sensitive than scraping techniques (Pereira *et al.*, 2015).



Figure 1a. Dog samples with hair loss symptoms in the face and leg areas



Figure 1b. Dog samples with hair loss symptoms around the eyes

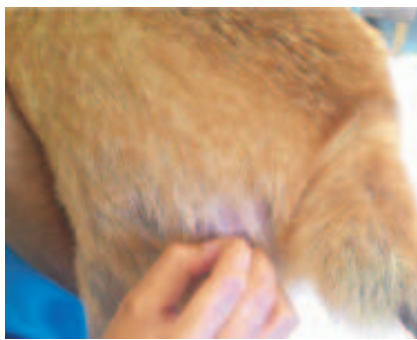

Figure 2a. Trichogram techniques

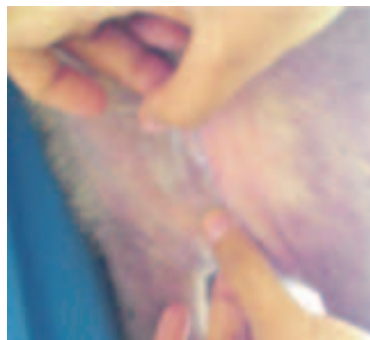

Figure 2b. Taping techniques

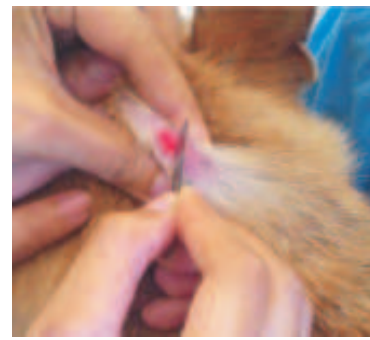

Figure 2c. Scraping techniques

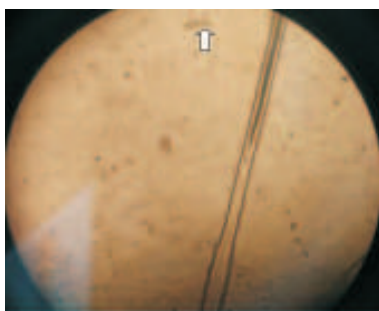


Figure 3a. Result of *Demodex* mites isolation on trichogram technique, under light microscope with 400x magnification.



Figure 3b. Result of *Demodex* mites isolation on taping technique, under light microscope with 400x magnification.

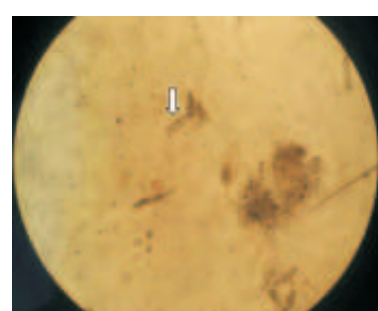


Figure 3c. Result of *Demodex* mites isolation on scraping technique, under light microscope with 400x magnification



Skin scraping technique provides better diagnostic value than trichogram and taping. However, these three techniques can be applied to isolate the *Demodex* mites. Tapping technique as an option especially if the area of the lesion is difficult to do i.e. scraping over the eyes and legs (Saridomichelakis *et al.*, 2007) and difficult to control for scraping. Skin biopsy techniques are not recommended for diagnostic tests of demodicosis. A very small number of skin samples and *Demodex* mite forms were often damaged during the histopathology preparation process (Fondati *et al.*, 2010), except on scraping techniques is difficult to do. Additional tests for the diagnosis of demodex mite can be done by observation of feces using Saline Acetic Formaldehyde solution (Weisglas, 2015).

More detailed diagnostic and examination techniques are necessary in cases of demodicosis in adult dogs. The non-negligible factors in the treatment of demodicosis are long-term treatment with steroid tablets, steroid ointment, hematology and blood chemistry profile of the patient, test of heartworm infection, and daily feed given (Mueller *et al.*, 2012).

### CONCLUSION

The scraping diagnostic technique provides the best diagnostic value in the isolation of *Demodex* mites in dogs.

### SUGGESTION

Based on our observation, we recommended that clinicians use the scrapping technique to diagnose demodicosis in dog.

### ACKNOWLEDGEMENT

Acknowledgment is declared to the Director of Bali Veterinary Clinic, Jl Pantai Prerenan, Banjar Delod Padonan, Prerenan, Mengwi, Badung, Bali, for assistance and facilities of the research.

### REFERENCES

- Beco L, Fontaine J, Bergvall K, Favrot C. 2007. Comparison of skin scrapes and hair plucks for Detecting *Demodex* mites in canine demodicosis, a multicentre, prospective study. *Vet Dermatol* 18: 281
- Carlotti DN. 2006. *Demodex injai*, *Demodex cati*, and *Demodex gatoi* (and others...) diagnosis and treatment. In Proceedings, 21 ESVD-ECVD Annual Congress. Pp. 194-198.
- Ferrer L, Ravera I, Silbermayr K. 2014. Immunology and pathogenesis of canine demodicosis. *Vet Dermatol* 25: 427-e65.
- Fondati A, De Lucia M, Furiani N, Monaco M, Ordeix L, Scarpella F. 2010. Prevalence of *Demodex canis*-positive healthy dogs at trichoscopic examination – 2009 ESVD and ACVD. *Vet Dermatol* 21(2): 146-151.
- Hillier A, Desch CE. 2002. Large-bodied *Demodex* mite infestation in 4 dogs. *J Am Vet Med Assoc* 220: 623-627.
- Martinez-Subiela S, Bernal LJ, Tvarijonaviciute A. 2014. Canine demodicosis: the relationship between response to treatment of generalised disease and markers for inflammation and oxidative status. *Vet Dermatol* 25: 72e24.
- Miller WH, Griffin CE, Campbell KL. 2013. Parasitic Skin Diseases. In: *Muller and Kirk's Small Animal Dermatology*. 7<sup>th</sup> ed. Toronto: Elsevier Inc. Pp. 304-315.
- Mueller RS, Bensignor E, Ferrer L, Holm B, Lemarie S, Paradis M, Shipstone MA. 2012. Treatment of demodicosis in dogs: 2011 clinical practice Guidelines. *Vet Dermatol* 23: 86-e21.
- Pereira AV, Pereira SA, Gremião IDF, Campos MP, Ferreira AM. 2012. Comparison of acetate tape impression with squeezing versus skin scraping for the diagnosis of canine demodicosis: Acetate tape versus skin scrape. *Aus Vet J* 90: 448-450.
- Pereira DT, Castro LJM, Centenaro VB, Amaral AS, Krause A, Schmidt C. 2015. Skin impression with acetate tape in *Demodex canis* and *Scarcoptes scabiei*. var. *vulpes* diagnosis. *Arq Bras Med Vet Zootec* 67(1): 49-54.
- Ravera I, Altet L, Francino O, Sanches A, Roldan W, Villanueva S, Bardagi M, Ferrer L. 2013. Small *Demodex* populations colonize most parts of the skin of healthy dogs. *Vet Dermatol* 24: 168-e37.

- Saridomichelakis MN, Koutinas AF, Farmaki R, Lontides LS, Kasabalis D. 2007. Relative sensitivity of hair pluckings and exudate microscopy for the diagnosis of canine demodicosis. *Vet Dermatol* 18(2): 138-141.
- Sastre N, Ravera I, Villanueva S. 2012. Phylogenetic relationships in three species of canine Demodex mite based on partial sequences of mitochondrial 16S rDNA. *Vet Dermatol* 23: 509-e101.
- Waisglass S. 2015. How Approach Demodicosis. *Veterinary Focus* 25(2): 10 -19.