

JURNAL MEDIK VETERINER

Indexed in SCOPUS based on the decision of
The Scopus Content Selection and Advisory Board (CSAB)
on August 29, 2023

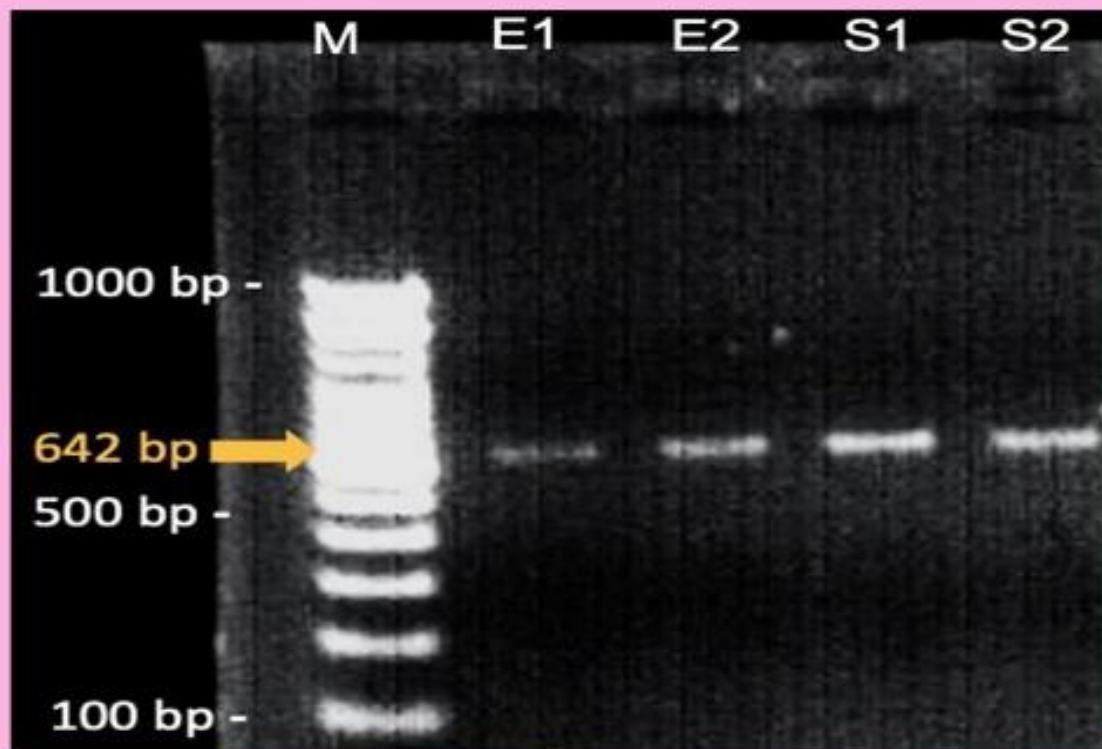


Figure source: Belgania et al. 2023, J Med Vet, 6(2), 209-215.



Collaboration
FACULTY OF VETERINARY MEDICINE
UNIVERSITAS AIRLANGGA
and

INDONESIAN VETERINARY MEDICAL ASSOCIATION



SINTA ACCREDITATION

SERTIFIKAT

Direktorat Jenderal Pendidikan Tinggi, Riset dan Teknologi
Kementerian Pendidikan, Kebudayaan, Riset dan Teknologi Republik Indonesia



Kutipan dari Keputusan Direktorat Jenderal Pendidikan Tinggi, Riset dan Teknologi
Kementerian Pendidikan, Kebudayaan, Riset, dan Teknologi Republik Indonesia

Nomor 225/E/KPT/2022
Peringkat Akreditasi Jurnal Ilmiah periode III Tahun 2022

Nama Jurnal Ilmiah
Jurnal Medik Veteriner
E-ISSN: 2581012X

Penerbit: Fakultas Kedokteran Hewan, Universitas Airlangga

Ditetapkan Sebagai Jurnal Ilmiah

TERAKREDITASI PERINGKAT 2

Akreditasi Berlaku selama 5 (lima) Tahun, yaitu
Volume 5 Nomor 1 Tahun 2022 sampai Volume 9 Nomor 2 Tahun 2026
Jakarta, 07 December 2022
Plt. Direktur Jenderal Pendidikan Tinggi,
Riset, dan Teknologi



Prof. Ir. Nizam, M.Sc., DIC, Ph.D., IPU, ASEAN Eng
NIP. 19610706198710101

PUBLISHER

Jurnal Medik Veteriner



Collaboration
Faculty of Veterinary Medicine, Universitas Airlangga
and
Indonesian Veterinary Medical Association



EDITOR ADDRESS

School of Health and Life Sciences, Universitas Airlangga
Jalan Wijaya Kusuma No.113, Mojopanggung, Giri, Banyuwangi, East Java 68425
Telp: 0333-417788, Fax: 0333-428890
e-mail: jmv@psdku.unair.ac.id
Homepage: <https://e-journal.unair.ac.id/JMV/index>

EDITORIAL TEAM

Editor in Chief

Faisal Fikri, drh., M.Vet., Universitas Airlangga, Indonesia

Managing Editor

Muhammad Thohawi Elziyad Purnama, drh., M.Si., Universitas Airlangga, Indonesia

Editorial Board Member

Agus Purnomo, drh., M.Sc., Universitas Gadjah Mada, Indonesia

Shekhar Chhetri, DVM., M.Sc., PhD., Royal University of Bhutan, Bhutan

Ahmad Kurniawan, drh., M.Sc., Badan Tenaga Nuklir Nasional (BATAN), Indonesia

Etsuko Hashimoto, DVM., PhD., Azabu University, Japan

Parthiban Sivamurthy, DVM., M.Sc., PhD., Tamilnadu University, India

Lalu Faisal Fajri, drh., M.Vet., BP3TR Disnakeswan Nusa Tenggara Barat, Indonesia

Assylkhanov Darkhan, DVM., PhD., Kazakh National Agrarian University, Kazakhstan

Ali Ahmad Alsahami, DVM., MVM., PhD., Universiti Putra Malaysia, Malaysia

Syakirah Azmey, DVM., M.Sc., PhD., Universiti Brunei Darussalam, Brunei Darussalam

Editorial Assistant

Muhammad Wahyudi, Amd., Sidoarjo, Indonesia

Section Editor

Choirun Nisa, S.IIP., Universitas Airlangga, Indonesia

Janet Wulandari, S.Kom., Universitas Airlangga, Indonesia

PEER REVIEWER

Jurnal Medik Veteriner (JMV) editorial team would sincerely like to thank all of our reviewers who contributed to peer review for the journal.

Prof. Dr. Bambang Sektiari L. DEA., drh., Universitas Airlangga, Indonesia

Prof. Hong Kean Ooi, DVM., PhD., Azabu University, Japan

Prof. Fedik A. Rantam, drh., Universitas Airlangga, Indonesia

Prof. Dr. İbrahim Aytekin, Selçuk Üniversitesi, Turkey

Prof. Dr. Ir. I Wayan Suarna, MS., Universitas Udayana, Indonesia

Prof. Lucia Regolin, DVM., PhD., University of Padova, Italy

Prof. Dr. RTS. Adikara, drh., M.S., Akp. TOT., Universitas Airlangga, Indonesia

Thomas Larsson Duran, DVM., M.Sc., PhD., James Cook University, Australia

Celia Hitomi Yamamoto, MD., Ph.D., Universidade Federal de Juiz de Fora, Brazil

Noor Hidayah Mohd Isa, DVM., MVM., PhD., Universiti Putra Malaysia, Malaysia

Dr. Rondius Solfaine, MP., APVET., drh., Universitas Wijaya Kusuma, Indonesia

Dr. Nanik Hidayatik, drh., M.Si., Universitas Airlangga, Indonesia

Wipaporn Jarujareet, DVM., PhD., Rajamangala University of Technology Srivijaya, Thailand

Dr. Ahmad Shofy Mubarak, S.Pi., M.Si., Universitas Airlangga, Indonesia
Yance Hanzie Setya Pratama, dr., Sp.B, Universitas Brawijaya, Indonesia
Maria Imaculata Arifin, drh., M.Sc., Ph.D., University of Calgary, Canada
Dr. Öğr. Üyesi Rabia Albayrak Delialioğlu, Ankara Üniversitesi, Turkey
Dr. Sattar Mengal, DVM., Lasbela University of Agriculture, Pakistan
Innocent Damudu Peter, DVM., PhD., University of Maiduguri, Nigeria
Dr. Ugbo Emmanuel Nnabuike, DVM., Ebonyi State University, Nigeria
Dr. Hebert Adrianto, S.Si., M.Si., M.Ked.Trop., Universitas Ciputra, Indonesia
Dewi Klarita Furtuna, dr., M.Ked.Klin., Sp.MK., Universitas Palangkaraya, Indonesia
Budhy Jasa Widyananta, drh., M.Si., IPB University, Indonesia
Dilasdita Kartika P., drh., M.Si., Balai Besar Veteriner Kelas I, Denpasar, Bali, Indonesia
Widodo Cipto Subagyo, drh., M.Si., Pusat Kesehatan Hewan, Banyuwangi, Indonesia
Junianto Wika Adi Pratama, drh., M.Si., Universitas Wijaya Kusuma, Indonesia
Samsuri, drh., M.Kes., Universitas Udayana, Indonesia
Ririn Rohmawati, drh., M.Si., Kementerian Pertanian, Republik Indonesia
Rama Arge Frismana, drh., M.Si., Klinik Habitat Satwa Surabaya, Indonesia
Arya Pradana Wicaksono, drh., M.Vet., Asosiasi Dokter Hewan Kuda Indonesia (ADHKI)
AKBP Drh. Chaindraprasto Saleh, Direktorat Polisi Satwa Baharkam Mabes Polri, Indonesia
Muhammad Lukman, drh., Dinas Pertanian Banyuwangi, Indonesia

VISION AND MISSION

Jurnal Medik Veteriner (JMV) with registered number pISSN 2615-7497 ; eISSN 2581-012X is an international journal published by Faculty of Veterinary Medicine, Universitas Airlangga and Indonesian Veterinary Medical Association (IVMA).

Jurnal Medik Veteriner (JMV) has been indexed in Scopus based on the decision of The Scopus Content Selection and Advisory Board (CSAB) on August 29, 2023.

Jurnal Medik Veteriner (JMV) has been awarded SINTA 2 from the Director General of Higher Education, Research and Technology, Ministry of Education, Culture, Research and Technology, Republic of Indonesia Number: 225/E/KPT/2022, on December 7, 2022.

Jurnal Medik Veteriner (JMV) publishes original research, case reports, and review articles on the scope of veterinary medicine which is published biannually year: April and October. This journal is contributed by practitioners, lecturers, researchers, students, and volunteers in the field of veterinary medicine. A submitted manuscript will be processed by the editorial board and reviewers. The peer review process is carried out through the Open Journal System (OJS). Complete information about the process of peer-reviewing manuscripts and guidelines for writing manuscripts is available on the website.

VISION

To become a leading and reputable international journal levels in the field of veterinary science.

MISSION

1. Utilization of journals as a source of novelty and intellectual development for the academic community in supporting Universitas Airlangga World Class University;
2. Organizing accountable and quality journal management to improve the number of intellectual products;
3. Promote as excellent references and indexed on reputable databases.

Jurnal Medik Veteriner (JMV) publishes high quality and novelty papers focusing on Veterinary and Animal Science. The fields of study are anatomy, pathology, basic medicine, veterinary public health, microbiology, veterinary reproduction, parasitology, animal husbandry, and animal welfare. Food animals, companion animals, equine medicine, aquatic animal, wild animals, herbal medicine, acupuncture, epidemiology, biomolecular, forensic, laboratory animals and animal models of human infections are considered.

AUTHOR INDEX

- Adi, AAAM... 271
Agustina, GC... 244
Ahsan, MM... 256
Al-Anshori, AA... 145
Aliza, D... 256
Amri, IA... 262
Amrullah, MF... 209
Anisa, AK... 262
Anwar, A... 256
Batan, IW... 303
Belgania, RH... 209
Bulu, PM... 155
Cahyani, AA... 244
Cahyanissa, AR... 262
Dharmayudha, AAGO... 216
Diana, KLM... 303
Dinana, Z... 191
Eriani, K... 256
Estoepangestie, ATS... 180
Fahrodi, DU... 173
Fasya, AH... 250
Gading, BMWT... 173
Geoputri, KM... 262
Gunawan, IWNF... 288
Hafizuddin, H... 256
Hardian, AB... 262
Hendrawan, VF... 244
Hernawati, T... 162
Hina, CYR... 297
Husnurrizal, H... 256
Ihsan, B... 185
Imlani, A... 250
Indarjulianto, S... 288, 297
Ismi, AN... 145
Jayanti, PD... 288, 303
Kenconojeti, H... 250
Kholifah, Y... 209
Kristanto, D... 237
Kusnoto, K... 191
Lamadi, A... 250
Lasakar, AS... 155
Lesmana, MA... 262
Mahdi, DA... 180
Mariah, SR... 250
Marsudi, M... 173
Maslachah, L... 145
Merdana, IM... 216
Mufasirin, M... 230
Mukti, AT... 250
Mustofa, I... 162, 191, 209
Nugroho, W... 244
Nurdianti, N... 230
Oktanella, Y... 244
Paga, A... 155
Plumeriastuti, H... 145
Primarizky, H... 180
Priyowidodo, D... 297
Purnawan, AB... 162
Putri, AN... 145
Rahmahani, J... 191
Rantam, FA... 191
Rimayanti, R... 162
Rizqy, AN... 197
Sabrina, AN... 250
Safitri, E... 162
Said, NS... 173
Salmin, S... 173
Samsuri, S... 216
Sandhika, IMGS... 197
Saputra, MGAS... 216
Sardjana, IKW... 180
Septiyani, S... 237
Sewoyo, PS... 271
Siregar, TN... 256
Sitinjak, RS... 185
Soegianto, A... 197
Sriningsih, AP... 297
Suandhika, P... 297
Suciyono, S... 250
Sudira, IW... 216
Sudisma, IGN... 216
Suhud, MK... 145
Sukoco, H... 173
Susanti, AR... 297
Susilowati, S... 162
Sutriana, A... 256
Suwarno, S... 191
Triakoso, N... 180
Ulkhahq, MF... 250
Utomo, B... 209
Wahyuni, S... 256
Wera, E... 155
Widhiantara, IG... 197
Winaya, IBO... 271
Wiradana, PA... 197
Wirata, IW... 271
Yanuartono, Y... 297
Yudaniayanti, IS... 180

Yulianto, B... 197

Yunus, M... 230

KEYWORDS INDEX

- Acute dermal toxicity... 216
African swine fever... 155
Albendazole... 297
Anemia... 288
Angiogenesis... 271
Ashitaba leaves... 145
Biodiversity... 250
Bornean orangutan... 297
Buffalo... 173
Burns... 145
Cat... 288
Cats... 180
Cattle... 191
Coccidiosis... 230
Color brightness... 250
Ctenocephalides felis... 288
Cultivation... 185
Dairy farm... 244
Dogs... 271
Ectoparasites... 185
Ehrlichiosis... 303
Eimeria spp.... 230
Environmental health... 197
Epidermal thickness... 262
Ethosomal gel... 145
Fat-tailed sheep... 230
Feed nutrition... 180
Fibroblast... 262
Foot and mouth disease... 244
Foot and mouth diseases... 191
Fresh milk... 244
Friesian holstein... 162
Gastrointestinal endoparasites... 173
Gembrong goat... 256
Genetic resources... 209
Goat... 209
Goldfish... 250
Growth... 250
Haemoplasmosis... 288
Health risks... 197
Hematology levels... 237
Hibiscus... 216
Husbandry... 155
Identification... 185
Intensity... 185
Kupang... 155
Lactoscan... 244
Light spectrum... 250
Mammary tumors... 271
Management... 155
Melanocortin receptor type 4... 209
Microplastics... 197
Motility... 162
Mycoplasma sp.... 288
Nanoparticles... 145
Ointment... 216
Ongole crossbreed... 237
Oregano ointment... 262
Origanum vulgare... 262
Pig... 155
Plasma membrane integrity... 162
Polewali mandar... 173
Polymerase chain reaction... 209
Prevalence... 173
Prostaglandin f₂α... 256
Red fermented rice... 303
Reverse transcription polymerase chain reaction... 191
Rhipicephalus sanguineus... 303
Semen... 209
Semi-intensive rearing... 237
Seminal plasma... 256
Shellfish... 197
Simmental-ongole crossbreed... 237
Storage periods... 162
Strongyloides sp.... 297
Strongyloidiasis... 297
Testosterone... 256
Therapeutic targets... 271
Thrombocytopenia... 303
Tilapia... 185
Traditional markets... 197
Urolithiasis... 180
Viability... 162
Wound healing... 145

SUBSCRIBED FORM

AREA	Issue* (give sign √)		
	1 year	2 years	3 years
East Java	<input type="checkbox"/> Rp.550.000,-	<input type="checkbox"/> Rp.800.000,-	<input type="checkbox"/> Rp.1.050.000,-
Other provinces	<input type="checkbox"/> Rp.600.000,-	<input type="checkbox"/> Rp.850.000,-	<input type="checkbox"/> Rp.1.100.000,-
Other countries	<input type="checkbox"/> US\$ 100	<input type="checkbox"/> US\$ 150	<input type="checkbox"/> US\$ 200

*(published biannually year)

I would like to become a Jurnal Medik Veteriner subscriber.

Name:

Institution:

Office address and Phone No:

.....

.....

Home address and Phone No:

.....

.....

Country:

Fax:

Email:

Postal code:

Date:

Signature:

I'll use the following to pay for my journal subscription: (give sign √)

Western Union Cheque with MTCN No:

Bank transfer / online to:

Bank Mandiri

Acc No. **896680000000714**

an. **Universitas Airlangga**

Bank BNI

Acc No. **9883030300000444**

an. **Universitas Airlangga**

Bank CIMB NIAGA Syariah

Acc No. **761 279 139 100**

an. **Muhammad Thohawi Elziyad**

Kindly email the subscription form and proof of payment to jmv@psdku.unair.ac.id

AUTHOR'S GUIDELINES

The author submit draft manuscript to the JMV editor through the open journal system (OJS). Draft manuscript typed using Microsoft Word programs, figures in a minimum JPEG format of 300 dpi. Figures are arranged on separate sheets and given sequence numbers and captions. The table is also typed on a separate sheet and numbered along with the table title.

The manuscript is typed using single-spaced with Times New Roman size font 12. Each manuscript does not exceed 8000 words or 20 pages of A4 size. The manuscripts are arranged according to JMV format in the following order:

A. Manuscript of Original Research

Title: Short, informative, and clear, written in capital letters except the Latin term or binomial nomenclature.

Author Identity: Full name (not abbreviated) without the title. If the author is more than one, with different affiliations, then behind each name is given an index of Arabic numerals. The author's address is written under the name of the author, including laboratories, institutions, and complete addresses with telephone/facsimile numbers and e-mail. An additional index (*) is given to the author who acts as the corresponding author.

Abstract: Abstract contains a summary of the manuscript, aim, brief method, result, and conclusion covering all manuscripts without specifying each part. Avoid using abbreviations. Abstracts include 3-5 keywords sorted according to their importance.

Keywords: first, second, third

Introduction: Contains the scope, background of the problem, research contributions, and research implications. This section should provide background and statement of the problem so that the reader can understand and assess the results of the study without reading previous reports relating to the topic. Provide literature that can support discussion.

Materials and Methods: Describe in detail and clearly the design of the study, the number of samples, the treatment method, the materials used, and the method of work carried out, including statistical methods and an explanation of the animal's ethical behavior certificate if necessary. The work methods submitted must contain enough information to enable the study to be repeated successfully.

Results and Discussions: Presented jointly and discussed clearly the results of the study. The results of the research can be presented in written form in a script, table, or picture. Reduce the use of graphics if it can be explained in the text. Limit the use of photos and present photos that clearly describe the results obtained. Pictures and tables must be numbered and quoted in the text. Photos can be sent in JPG, JPEG, and PNG formats. The result of processing data is sent in a file separate from the scientific script file and accompanied by the name of the program and basic data for compiling the graph. The discussion presented should contain an interpretation of the results obtained and the discussion relating to previous reports. Avoid repeating statements that have been conveyed to methods, results, and other information that has been presented in the introduction.

Conclusion: Must be specific, clear, and answer the problem. Presented separately from the results and discussion.

Acknowledgments: Aimed at those who fund research and acknowledge institutions and individuals who have helped research or scientific writing processes.

References: Alphabetically sorted by name and year of publication in APA Style format. Journal abbreviations are based on the procedure used by each journal. Reference composition, i.e. 80% of

journals and 20% of textbooks, others. The latest level of up to 10 years is recommended. Example of reference writing:

Journal:

Cheng, Q., & Sun, D. W. (2018). Factors affecting the water holding capacity of red meat products: a review of recent research advances. *Critical reviews in food science and nutrition*, 48(2), 137-159.

Book:

Aberle, E. D., Forrest, J. C., Gerrard, D. E., & Mills, E. W. (2021). Principles of Meat Science. 4th edition. Kendal/Hunt Publishing Company, pp: 144-145.

Book Chapter:

Johnson, C. A. (2015). Cystic endometrial hyperplasia, pyometra, and infertility. In Ettinger, S.J., Feldman, E.C. (Ed) Textbook of veterinary internal medicine, disease of dog and cat. Tokyo: WB Saunders Co, pp: 1636-1642.

Abstract:

Anil, M. H., Love, S., Helps, C. R., & Habour, D. A. (2012). Potential for carcass contamination with brain tissue following stunning and slaughter in cattle and sheep. Abstract 5rd International Congress on Veterinary Virology, Switzerland Sept, 4-7.

Conference Proceedings:

Agbeniga, B., & Webb, E. C. (2014). Influence of electrical stimulation on carcass and meat quality of Kosher and conventionally slaughtered cattle. Amies, France, 23-26 Oct 1989, pp: 199-231.

Thesis / Dissertation:

Rahmaningtyas, I. H. (2018). Aktivitas Antibakteri Ekstrak Kloroform Daun Sirsak (*Annona muricata L.*) Terhadap Pertumbuhan Bakteri *Pseudomonas aeruginosa* Secara In Vitro. [Skripsi]. Fakultas Kedokteran Hewan. Universitas Airlangga. pp: 87.

B. Case Report, Review Article, and Letter to Editor

Manuscripts are written not exceed 3000 words or 6 pages are included in Figures and Tables.

Preparation of manuscripts for Title and Identity of the author as same as the guidelines of original research.

Abstract: Consisting of at least 100 words and a maximum of 250 words

The composition of the manuscript includes an Abstract, Introduction, Material and Methods, Results and Discussion, Conclusion, Acknowledgments, and References.

- Manuscript submission must be accompanied by a letter of originality which can be downloaded on the website. The letter must clearly state the author who can be contacted, complete mailing address, and telephone number. The correspondence author is responsible for the originality of the research and the contents of the manuscript. All authors must have approved the contents of the submitted manuscript.
- Processing articles are charged to the correspondence author in the amount of IDR.550,000,- or USD.100. Authors can send article processing or subscription fees via transfer to one of the following bank accounts:

Bank **Mandiri**
Acc No. **896680000000714**
an. **Universitas Airlangga**

Bank **BNI**
Acc No. **988303030000444**
an. **Universitas Airlangga**

Bank **CIMB NIAGA Syariah**
Acc No. **761 279 139 100**
an. **Muhammad Thohawi Elziyad**

Table of Contents:

Page:

Original Research

Efficacy of Transdermal Delivery Nano Ethosomal Gel from Ashitaba Leaves on In-vivo Burn Wound Healing in Albino Rats Akhmad Afifudin Al-Anshori, Anandia Nafisah Putri, Alif Noviana Ismi, Mohamad Kharis Suhud, Hani Plumeriastuti, Lilik Maslachah.....	145-154
Pig Farm Management and Its Contribution to The African Swine Fever Incidences in Kupang, Indonesia Petrus Malo Bulu, Agustinus Paga, Anita S. Lasakar, Ewaldus Wera.....	155-161
Evaluation of Motility, Viability, and Integrity Plasma Membranes of Frozen Semen in Friesian Holstein with Storage Periods of 33, 30, 27, and 24 Years Ahmad Budi Purnawan, Rimayanti, Suherni Susilowati, Imam Mustofa, Tatik Hornawati, Erma Safitri.....	162-172
Prevalence of Gastrointestinal Endoparasites of Swamp Buffaloes (<i>Bubalus bubalis</i>) in Polewali Mandar Hendro Sukoco, Deka Uli Fahrudi, Salmin, Nur Saidah Said, Marsudi, Besse Mahbuba We Tenri Gading.....	173-179
An Evaluation of Nutritional Factors on The Prevalence of Urolithiasis in Cats at The Veterinary Teaching Hospital, Universitas Airlangga During 2017-2019 Daffa Amanul Mahdi, I Komang Wiarsa Sardjana, Ira Sari Yudaniyanti, Agnes Theresia Soelih Estocpangestic, Nurdianto Triakoso, Hardany Primarizky.....	180-181
Prevalence of Ectoparasites in Tilapia (<i>Oreochromis niloticus</i>) in Tarakan Burhamiddin Ihsan, Rini Septriananda Sitingjak.....	185-190
Detection of Foot and Mouth Disease Virus in Cattle in Lamongan and Surabaya, Indonesia Using RT-PCR Method Zayyin Dinana, Fedik Abdul Rantam, Suwarno, Imam Mustofa, Jola Rahmahani, Kusnoto.....	191-196
Contaminants and Human Health Risks Associated with Exposure to Microplastic Ingestion of Green Mussels (<i>Perna viridis</i>) Collected from The Kedonganan Fish Market, Bali Putu Angga Wiradana, I Made Gde Sudyadnyana Sandhika, I Gede Widhiantara, Aimatun Nisfia Rizqy, Agoes Soegianto, Bambang Yulianto.....	197-208
Detection of Melanocortin Receptor Type 4 (MC4R) Gene in Semen of Etawah Crossbreed and Senduro Goats Ristaqul Husna Belgaria, Budi Utomo, Imam Mustofa, Yayuk Kholifah, Muhammad Fajar Anrullah.....	209-215
Evaluation of Acute Dermal Toxicity of Hibiscus Leaves as Simplicial Ointment on Albino Rats Made Gode Adi Surya Saputra, I Wayan Sudira, Samsuri, I Made Mardana, Anak Agung Gde Oka Dharmayudha, I Gusti Ngurah Sudisma.....	216-229
Incidence of <i>Eimeria</i> spp. in Fat-Tailed Sheep Breed in Malang, Indonesia Nurdianti, Muchammad Yunus, Mufasirin.....	230-236
Comparison of Hematological Levels of Simmental-Ongole Crossbreed (SimPO) and Ongole Crossbreed (PO) Cattle Dwi Kristanto, Septiyani.....	237-243
Foot and Mouth Disease Impact on Milk Productivity and Quality in KUD Kertajaya, Kediri, Indonesia Yudit Oktanella, Ayunda Ageng Cahyani, Viski Fitri Hendrawan, Widi Nugroho, Galuh Chandra Agustina.....	241-249
Color Brightness and Growth Levels of Goldfish (<i>Carassius auratus</i>) Reared with Different Light Spectrums Annisa Nur Sabrina, Akhmad Taufiq Mukti, Suciyono, Hapsari Kenconoajati, Mohammad Faizal Ulkhaq, Arif Habib Pasya, Aralik Lamadi, Ainulyakin Imlani, Sharven Rao Mariah.....	250-255
Amelioration of Seminal Plasma Testosterone Concentration in Gembrong Goats after In Vivo Administration Hafizuddin, Husnurrisal, Tongku Nizwan Siregar, Kartini Eriani, Sri Wahyuni, Muhammad Maulana Ahsan, Amalia Sutriana, Anwar, Dwinna Aliza.....	256-261
Efficacy of Oregano Extract Ointment on Fibroblast Cells and Epidermis in Albino Rats with Excisional Wound Muhammad Arfan Lesmana, Indah Amalia Amri, Ardilla Rachma Cahyanissa, Kartika Myrindari Geoputri, Agri Kaltaria Anisa, Andreas Bandang Hardian.....	262-270

Literature Study

Mammary Tumors in Dogs, Recent Perspectives and Antiangiogenesis as a Therapeutic Strategy: Literature Study Palagan Senopati Sewoyo, Anak Agung Ayu Mirah Adi, Ida Bagus Oka Winaya, I Wayan Wirata.....	271-287
---------------------------------------------------------------------------------------------------------------------------------------------------------------------------------------------------------------------	---------


Case Report

Haemoplasmosis in A Hypoalbuminemic Cat: A Case Report Putu Devi Jayanti, I Wayan Nico Fajar Gunawan, Soedarmanto Indarjulianto.....	288-296
Strongyloidiasis in Bornean Orangutan: A Case Report Putu Suandhika, Agatha Ria Susanti, Agnes Pratamiutami Sriningsih, Carlo Yuniur Ray Hina, Yanuarlono, Soedarmanto Indarjulianto, Dwi Priyowidodo.....	297-302
<i>Rhipicephalus sanguineus</i> Infestation with Ehrlichiosis in Shitzu-Pomeranian Crossbred Dogs Treated using Red Fermented Rice: A Case Report Kadek Leni Martha Diana, Putu Devi Jayanti, I Wayan Batan.....	303-311

Indexed in:



Similarity Check:



Reference Management:



School of Health and Life Sciences
 Universitas Airlangga
 Jalan Wijaya Kusuma No.113, Giri, Banyuwangi, 68425
 Email: jmv@psdku.unair.ac.id
 Website: <https://e-journal.unair.ac.id/JMV/index>

Evaluation of Acute Dermal Toxicity of Hibiscus Leaves as Simplicial Ointment on Albino Rats

Made Gede Adi Surya Saputra¹, I Wayan Sudira^{2*}, Samsuri²,
I Made Merdana², Anak Agung Gde Oka Dharmayudha³,
I Gusti Ngurah Sudisma³

¹Veterinary Medicine Study Program, Faculty of Veterinary Medicine, Udayana University, Denpasar, Bali, Indonesia, ²Veterinary Physiology, Pharmacy and Pharmacology Laboratory, Faculty of Veterinary Medicine, Udayana University, Denpasar, Bali, Indonesia, ³Veterinary Clinic Department, Faculty of Veterinary Medicine, Udayana University, Denpasar, Bali, Indonesia.

*Corresponding author: wayan.sudira@unud.ac.id

Abstract

Hibiscus is a plant that has been shown to contain substances that may be used as sunscreen to protect the skin from UV radiation. In terms of their potential as sunscreens, flavonoids, tannins, and quinone chemicals are crucial because they are antioxidants that can reduce the negative effects of UV radiation and boost photoprotective activity. This study aimed to investigate the acute dermal toxicity potential of hibiscus leaves simplicial ointment 40% on female albino rats. The evaluation method referred to The OECD Guideline for Testing of Chemicals – No. Test: 402, Acute Dermal Toxicity-Fixed Doses Procedure. Based on the Globally Harmonized System compared to this study reported that acute dermal median lethal dose (LD50) was > 2000 mg/kg. It can be concluded that hibiscus leaves simplicial ointment 40% has safe to apply topically and doesn't produce acute skin toxicity.

Keywords: acute dermal toxicity, hibiscus, ointment

Received: 7 March 2023

Revised: 28 May 2023

Accepted: 4 July 2023

INTRODUCTION

Hibiscus (*Hibiscus rosa sinensis* L.) is a plant that is known to have compounds that have the efficacy of sunscreen so that it can protect the skin from solar radiation (Al-Snafi, 2018). Flavonoid, tannin, and quinone compounds play an important role in terms of their potential as a sunscreen because they are antioxidants that can prevent the negative effects of ultraviolet radiation and increase photoprotective activity (Pratiwi and Husni, 2017; Petruk et al., 2018). Antioxidants can generally be obtained naturally from fruits and plants, or synthetically derived from the synthesis of a chemical reaction (Rahmi, 2017; Prasetya et al., 2020).

Providing antioxidants can be done topically or systemically (Soejanto, 2017). Topical ointments that are often used on the skin are semi-solid forms. Medically, the use of ointment or unguentum is local and is generally used for topical cases (Lazuardi, 2019). Producing ointments requires a base and active ingredients

that dissolve in the ointment. One of the active ingredients that can be used is vegetable simplicial (Simaremare et al., 2015). Herbal simplicial is a natural material in the form of whole plants, parts of plants, or plant exudates used as medicine that has not undergone any processing and is a dried material (Endarini, 2016).

The use of herbal as medicine has been developing in several studies, but its use has not been well documented (Yassir and Asnah, 2018). According to Lestaridewi et al (2017), the number of people who use traditional medicine remains high even though Indonesia has developed modern health services. The prevalence of traditional medicine use is influenced by a person's level of knowledge. According to Adiyasa and Meiyanti (2021), limited knowledge and a lot of inappropriate information received by the public are new problems related to the consumption of traditional medicine. This condition is supported that traditional medicines are safer without side effects and are also easier

to obtain without a prescription (Sudira *et al.*, 2019). In reality, plants used for traditional medicine still need to be evaluated preclinically and clinically, because medicinal plants still have the potential to be toxic at certain levels or doses (Mappasomba *et al.*, 2019; Ridwan *et al.*, 2020; Siregar *et al.*, 2020).

Merdana *et al.* (2020b) declared in their study regarding the acute dermal toxicity of rajas oil in Wistar rats, that the acute dermal toxicity test was one of the tests carried out in the early stages of preclinical trials. The dermal acute toxicity test aims to determine the toxic power of a chemical substance through skin contact (Zulfiana, 2014). Toxicity testing is important to carry out because it will be used to consider determining dosage, administration time, and application as well as to determine the efficacy, safety, and potential toxicity of a drug (Merdana *et al.*, 2020a; Sasmito *et al.*, 2015). Basically, saponins and alkaloids are two active compounds contained in hibiscus that can trigger skin irritation (Brandenburg, 2018; Janjic, 2021).

Several studies suggest that hibiscus has the potential for oral toxicity. Nath and Yadav (2014) found that administering hibiscus leaf extract with dose of 800 mg/kg, there was an increase in the levels of the alanine aminotransferase (ALT) and aspartate aminotransferase (AST) enzymes as well as an increase in total bilirubin, urea, and creatine. In the meantime, Meena *et al.* (2014) assessed the hibiscus flower extract's toxicity on mice and discovered that it had hazardous potential, as evidenced by a 20% fatality rate at 1600 mg/kg. It is necessary to explore the potential for topical toxicity through an assessment of acute dermal toxicity.

MATERIALS AND METHODS

Ethical Approval

All procedures for using experimental animals have received approval from the Animal Ethics Committee, Faculty of Veterinary Medicine, Udayana University, with Animal Ethics Approval Certificate Number: B/1/UN14.2.9/PT.01.04/2023. This study was carried out at the Veterinary Physiology,

Pharmacy and Pharmacology Laboratory, Faculty of Veterinary Medicine, Udayana University with the support of the Bali-BRIN "Eka Karya" Botanical Garden Characterization Laboratory, Tabanan, and Medicinal Plant Post-Harvest Processing Center (P4TO), Tabanan and the Technology Laboratory, Faculty of Pharmacy, Mahasaraswati University Denpasar, Bali, Indonesia.

Experimental Design

This study was an experimental design using a qualitative descriptive analysis approach. The acute dermal toxicity test method used refers to The OECD Guideline for Testing of Chemicals – No. Test: 402, Acute Dermal Toxicity-Fixed Doses Procedure. The consideration for choosing this method was based on optimizing the study design by minimizing the number of experimental animals used and this method has been accepted and recognized internationally.

Plant Determination

Determination of the hibiscus leaf samples used in this research was carried out at the Bali-BRIN "Eka Karya" Botanical Garden Characterization Laboratory. The determination results showed that the leaf samples used were of the *Hibiscus rosa-sinensis L.*

Simplicial Production

Hibiscus leaves were air-dried at 25°C for 7–14 days (Davis *et al.*, 2022; Simaremare *et al.*, 2015) and kept from direct sunlight to avoid damage or loss of desired chemical content (Rivai *et al.*, 2013). Dried simplicial was collected to obtain high antioxidant levels with lower water loss levels (Dharma *et al.*, 2020). Drying generally functions to reduce water content which can inhibit the growth of bacteria and mold so that the material is more durable and easier to store, and also makes subsequent treatment easier (Handoyo and Pranoto, 2020). The leaves were then mashed and filtered using sieve number 100. The pollination process was carried out at the Medicinal Plant Post-Harvest Processing Center (P4TO), Tabanan. Simplicial powder was then

stored at a cool temperature in a clean and airtight container such as aluminum foil.

Ointment Production

The ointment was produced using a hydrocarbon base, i.e., vaseline album. The choice of ointment base was based on research by Davis *et al* (2022) and Trisnajayanti (2013), namely that the hydrocarbon base has good physical properties seen from the adhesion test and protection test, in addition to the hydrocarbon base having a longer contact time with the skin, so it was expected that penetration of the material more active into the skin layers (Mukhlisah *et al.*, 2016). A total of 60 g vaseline album was mixed with 40 g of simplicial into the mortar, then grinded until homogeneous. The ointment formulation has produced a semisolid consistency, a deep green color, and a distinctive aroma of hibiscus leaves.

Experimental Animals

This study used adult and nulliparous female Wistar albino rats. Rats were healthy, 12–16 weeks old, weighing 200–300 g. Animals were acclimatized for a minimum of 5 days in the experimental room in individual cages, with a base area of 350 cm² and a height of 18 cm covered with husk with a wire cover. The room temperature was around 25°C, humidity 60–70%, and a 12-hour dark/light lighting cycle was provided. Animals were given laboratory standard commercial pellet feed of 20 g/day and provided with drinking water *ad libitum*, as well as a minimum stressful environment. All cages and test animals were numbered and randomized before treatment started. The above conditions meet the standard maintenance environmental parameters (Liu and Fan, 2018). The success of acclimatization of experimental animals can be seen by measuring normal physiological parameters such as changes in body weight, heart rate, body temperature, and behavior (Arts *et al.*, 2014; Triana *et al.*, 2020).

Preparation of Experimental Animals

The hair on the dorsal part was shaved 24-hour before treatment in an area of 6 x 8 cm² (at

least 10% of the body surface area) for exposure to the test material. During the shaving process, the test animals were given ketamine-xylazine anesthesia at a dose of 50–100 mg/kg BW ketamine (Ket-A-100®, Agrovet Market Animal Health, Peru) and 5–12,5 mg/kg BW xylazine (Xyla®, Interchemie, Netherlands) (Krissanti *et al.*, 2023) and carried out carefully so as not to cause injury to the dermis. Giving anesthesia aimed to reduce stress during the shaving process. Only animals with healthy, intact skin were used in this study.

Dermal Acute Toxicity Test Procedure

The acute dermal toxicity test stage was divided into two, i.e., the preliminary test (dose search), and then proceed to the main test stage. In stage 1, a preliminary test uses one experimental animal, the evaluation steps were performed as in Figure 1. If there was no information regarding the test material, it was recommended to start testing with a dose of 200 mg/kg BW, but if there was enough information, it could be started with a dose of 1000 mg/kg BW (OECD, 2017). In this study, an initial dose of 1000 mg/kg BW was used. The test material was applied to the specified skin, covered with sterile gauze, and wrapped with a non-irritating plaster to ensure the test material remained in contact with the skin for 24-hour and there was no chance of the test material being ingested by the test animal. At the end of the exposure period, the plaster was removed and the remaining test material was rinsed using distilled water or another neutral solvent. Then observations were carried out during the 0, 24, 48, and 72-hours after exposure to the test material, and continued until the 14-day. Observations include clinical assessment, weight loss, observation of skin anatomy pathology, and death. If the test animal experiences symptoms of severe toxicity or death, then evaluation continues using a lower dose with a new test animal. Evaluation was stopped if the lowest dose test showed death or symptoms of severe toxicity (Solikhah *et al.*, 2022). The highest dose that does not cause death or does not show signs of severe toxicity will be used in the main evaluation phase (Puspitasari *et al.*, 2021).

In the main stage, the same procedure was carried out as shown in Figure 2. The evaluation was carried out with a predetermined dose with the addition of two new experimental animals for respective treatment and control groups. In this study, the treatment group was applied topically with hibiscus simplicial ointment, and the control group was given a placebo in the same amount as the treatment.

Clinical Observation

Observations were performed on both groups clinically immediately after the exposure period. Special attention to hourly checks is carried out in the first 6-hour and monitored for 24-hour, then continued once every day until the 14-day. Observations carried out included weighing the rat's body weight, visual clinical observations, and the death of test animals. All data including toxic signs, time to appearance, duration of toxicity and recovery time, changes in body weight, and time to death were recorded systematically, and compared with the control group. It was necessary to pay attention to the symptoms of tremors, seizures, drooling, diarrhea, lethargy, sleep, and coma. Observations should include changes in the skin, hair, eyes, mucous membranes, respiratory system, blood circulation, central and autonomic nervous systems, somatomotor activity, and changes in behavioral patterns. Observations were generally carried out once a day in the morning because mice will become aggressive during the day. Rats become aggressive during the day because rats are nocturnal animals that are active at night and sleep during the day (Al-Idrus *et al.*, 2014). Body weight was measured before treatment, and then carried out every day until the end of the observation period. Animals found to be dying, showing severe pain, or signs of permanent physical injury should be sacrificed immediately.

Observation of Skin Anatomy Pathology

Anatomical pathology observations were carried out on the treated skin areas, carried out at 24, 48, and 72-hours after the exposure period for the appearance of irritation symptoms such as erythema and edema. Scoring uses an arbitrary

scale (Krismayogi *et al.*, 2018), i.e., (0) no erythema, (1) very little erythema (diameter < 25 mm), (2) clearly visible erythema (diameter 25–30 mm), (3) moderate erythema (diameter 30–35 mm), (4) severe erythema (diameter > 35 mm). (0) Lightly edema, (1) very light edema, (2) slight edema (clear edges and enlargement), (3) moderate edema (thickness \pm 1 mm), (4) severe edema (thickness >1 mm). The data obtained were analyzed to obtain a primary irritation index (PII) using the PII formula: The sum of all erythema and edema values at the time of observation divided by the number of mice multiplied by the number of times observations (Kuncari *et al.*, 2015). The level of irritation was assessed based on the Draize Test, i.e., (< 0,5) not irritating, (0,5–2,0) slightly irritating, (2,0–5,0) moderate irritation, (5,0–8,0) highly irritating (Baldisserotto *et al.*, 2018).

Assessment of Acute Dermal Toxicity

Determination of the LD50 of test preparations was based on the Global Harmonized System of Classification and Labeling of Chemicals (Table 1). The LD50 value was calculated statistically using the Thompson-Weil method.

Data Analysis

Data from non-parametric observations will be presented descriptively. Overall data are expressed as mean ($x \pm SD$). Statistical analysis of LD50 values was carried out using the Thompson-Weil test with a 95% confidence interval. Changes in body weight before and after treatment were analyzed using the paired t-test ($p < 0,05$ was declared significant). The primary irritation index was classified based on the Amended Draize Test. Conclusions were declared based on descriptive analysis of the analysis of results of the respective parameters.

RESULTS AND DISCUSSION

Preliminary Test

The test was performed with an initial dose of 1000 mg/kg BW because the compound of the test material was known, then continued with a

dose of 2000 mg/kg BW which reported no symptoms of toxicity or death in the main evaluation (Table 2).

In this study, a dose of 1000 mg/kg BW was used as the initial dose in the preliminary test because there was sufficient information regarding the chemistry of hibiscus leaves. The evaluation was performed on the respective dose. After observing and evaluating clinical signs, irritation, and changes in body weight, it was found that this dose was still safe for use as seen from the absence of signs of toxicity, weight loss, or death in terms of the OECD Guideline for The Chemical Testing of Chemicals No. 402 (2017) so that it is continued with a dose of 2000 mg/kg BW. The same results were also obtained in the evaluation with this dose, therefore a dose of 2000 mg/kg BW was used in the main acute dermal toxicity test. The results of this preliminary test are similar to the findings of Samirana *et al.* (2018) in their study regarding the preliminary test of the acute dermal toxicity of a 70% ethanol extract ointment preparation from binahong leaves which showed that a dose of 5000 mg/kg BW, was still safe to apply to the skin in the form of ointments or extracts.

Clinical Observation

The mortality rate is presented in Table 3 and clinical observations of the toxicity symptoms of hibiscus leaf simplicial ointment are shown in Table 4. The results of clinical observations in the main evaluation reported that the experimental animals at the beginning of the exposure period experienced decreased activity, and looked stressed, lethargic, and immobility. Then it returned to showing normal activity 24-hour after exposure until the 14-day. Experimental animals did not show any symptoms of toxicity such as deviations from normal activities, tremors, seizures, and diarrhea. The eyes and mucous membranes as well as the respiratory system appear normal, with no abnormalities. The mortality rate was obtained at 0% because there were no deaths in the treatment and control groups. The skin changes appeared reddish like erythema on the 0-hour to the 3-day of observation and disappeared on the 4-day as

measured by the degree of irritation based on the Draize test. The variability of hair growth in test animals began to appear on the 2-day of observation in all test animals. On the 14-day, hair growth looked like before treatment, but there were several points that were still shorter.

The results of this study were similar to the findings of Zahi *et al.* (2015) in testing the acute dermal toxicity of noni fruit extract which showed that when administered doses of 2000 mg/kg BW and 5000 mg/kg BW there were no visible symptoms of toxicity and a mortality rate. A study by Merdana *et al.* (2020b) regarding the potential for acute dermal toxicity of Rajas Oil also showed that there was no death and the reversibility of hair growth in experimental animals began to appear on the 3 and 14-day it looked like before treatment but the size was still shorter than the initial condition.

The changes in behavior that occurred at the beginning of the exposure period in this study were thought to be due to the influence of bandaging during treatment so the animals felt less comfortable due to changes in lifestyle habits. Various factors can influence stress in animals, such as drastic changes in habits such as eating and drinking, transportation, moving cages, the presence of predators, rough handling, treatment, and climate change (Efendy, 2018). The findings of Zulfiana (2014) in testing the acute toxicity of dermal biolarvicide also showed similar results, namely the absence of deaths and changes in behavior up to the first 2-hour of the exposure period. Sari *et al.* (2016) in their study also found behavior changes in the first 2 hours of the exposure period up to 30 minutes after the exposure period is over. The difference in the duration of changes in behavior is thought to be caused by differences in the size of the administration dose.

Observation of Skin Anatomy Pathology

The results of observation and evaluation of skin anatomy pathology showed that both groups showed mild irritation (Figure 3) and the classification is presented in Table 5. Based on anatomical skin pathology observations, it was found that there were indications of erythema at

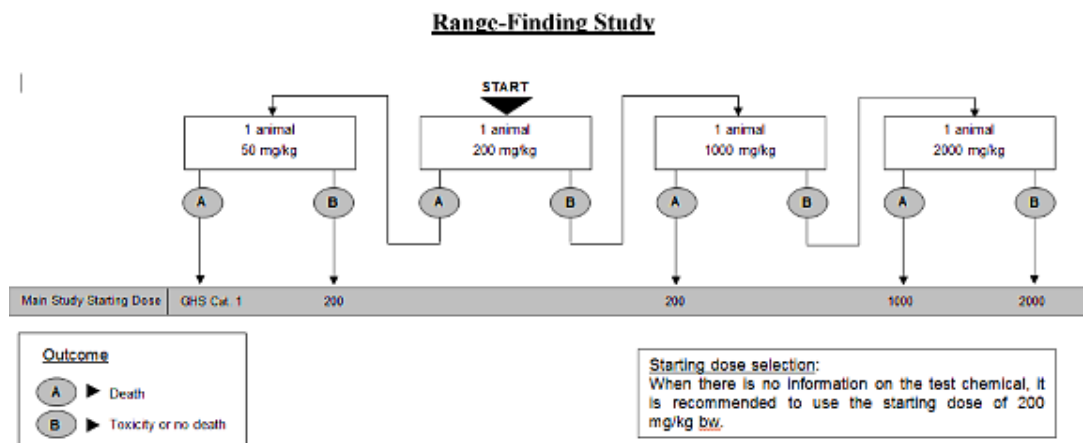


Figure 1. Preliminary evaluation stages (OECD, 2017).

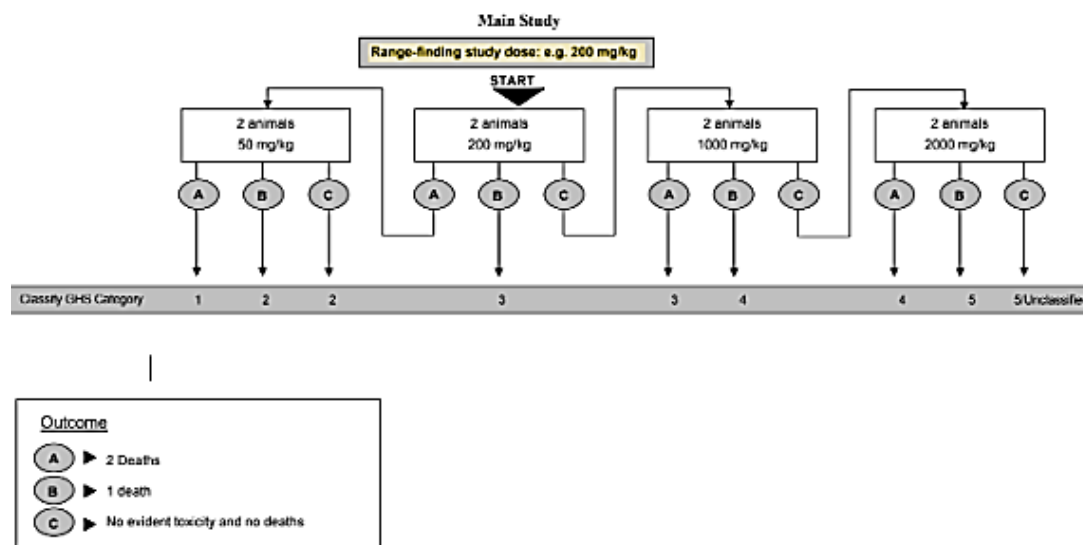


Figure 2. Main evaluation stages (OECD, 2017).

Table 1. Classification of Dermal Acute Toxicity (United Nations, 2011)

Category	Value	Danger Level
1	$0 < \text{mg/kg BW} \leq 50$	Fatal in contact with skin
2	$50 < \text{mg/kg BW} \leq 200$	Fatal in contact with skin
3	$200 < \text{mg/kg BW} \leq 1000$	Toxic in contact with skin
4	$1000 < \text{mg/kg BW} \leq 2000$	Dangerous in contact with skin
5	$2000 < \text{mg/kg BW} \leq 5000$	May be dangerous in contact with skin

Table 2. Results of observations and preliminary test evaluation

Parameter	Dose	
	1000 mg/kg BW	2000 mg/kg BW
Clinical observation	There were no mortality or visible clinical symptoms	There were no mortality or visible clinical symptoms
Primary irritation index	0 (Not irritating)	0 (Not irritating)
Body weight (g)	(+) 15,09	(+) 18,82
Interpretation	Followed by a higher dose	Doses used in the main evaluation

Table 3. Mortality rate of experimental animals

Group	Mortality rate (%)
P0	0
P1	0

(P0) Placebo (Vaseline alba/ointment base), (P1) Simplicial ointment 40% 2000 mg/kg BW.

Table 4. Clinical signs and behavioral patterns of experimental animals

Parameter	Control		Treatment	
	P0 (6-Hour)	P0 (24-Hour)	P1 (6-Hour)	P1 (24-Hour)
Skin and hair changes	+	+	+	+
Eyes and mucous membranes	-	-	-	-
Respiratory system	Normal	Normal	Normal	Normal
Changes in behavior	-	-	-	-
Somatomotor activity	Normal	Normal	Normal	Normal
Toxicity symptoms	-	-	-	-

(P0) Placebo (Vaseline alba/ointment base), (P1) Simplicial ointment 40% 2000 mg/kg BW.

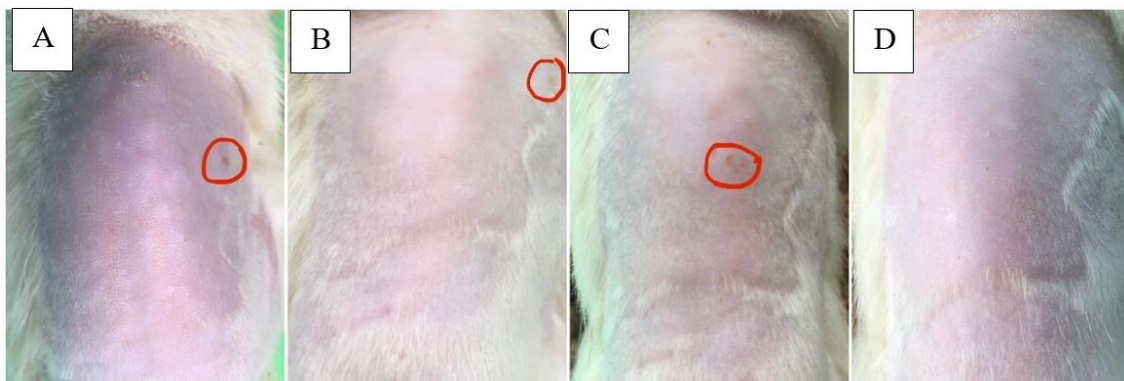


Figure 3. Observation of skin anatomical pathology in (P1) 2nd animal treatment group. (A) 0-hour observation, (B) 24-hour observation, (C) 48-hour observation, (D) 72-hour observation.

Table 5. Irritation index scoring according to the Amended Draize System

Group	Animal No.	Irritation score	
		Erythema	Edema
P0	1	2	0
	2	4	0
P1	1	4	0
	2	4	0
Total score (P0 — P1)		6	8
PII (P0 — P1)		0,75	1
Results (P0 — P1)		Slightly irritating	Slightly irritating

(P0) Placebo (Vaseline alba/ointment base), (P1) Simplicial ointment 40% 2000 mg/kg BW, (PII) Primary Irritation Index.

Table 6. Rat body weight before and after evaluation

Group	Initial weight (g)	$\bar{x} \pm SD$	Final weight (g)	$\bar{x} \pm SD$	ΔBW
P0	225,18	223,41 ± 2,51	230,27	231,20 ± 1,31	7,79 ± 3,82*
	221,63		232,12		
P1	234,15	243,75 ± 13,58	240,78	253,48 ± 17,96	9,73 ± 4,38
	253,35		266,18		

*not significantly different ($p > 0,05$) when compared with the treatment group.

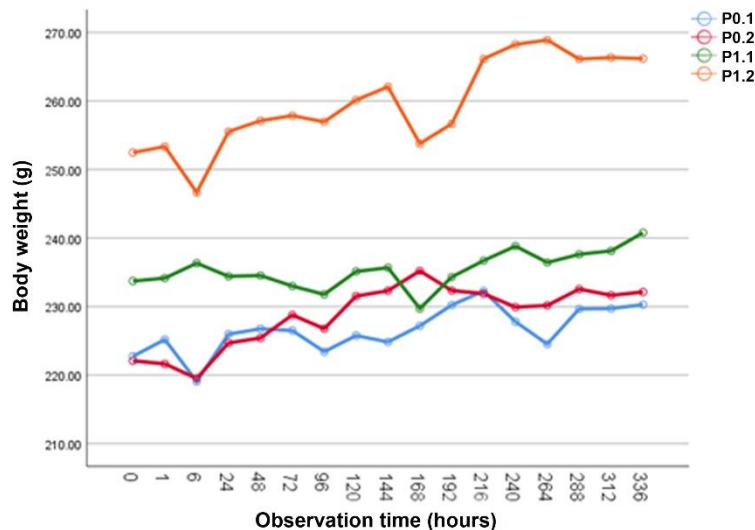


Figure 4. Body weight of experimental animals during 14-days of observation.

0, 24, 48, and 72-hours of observation. At each observation an assessment was carried out, and a score was given as shown in Table 5. The results of calculating the Primary Irritation Index (PII) showed that the control group and the treatment group had values that were not very different and were classified as experiencing mild irritation.

These results indicate that there were false positives shown in the control group who experienced erythema, which is difficult to happen because only an ointment base, namely vaseline album, was applied. Vaseline has long been known to be used as the most effective treatment for dry skin because it can retain water in the skin so that the skin remains moist and the skin barrier remains healthy (Hamishehkar *et al.*, 2015). Vaseline also strongly modulates antimicrobial action and helps the skin barrier in blocking invading pathogens (Czarnowicki *et al.*, 2015). According to Ordonez-Toro *et al.* (2022), vaseline can reduce erythema. Maarouf *et al.* (2019), also suggested the use of vaseline to improve the skin barrier and erythema. Zahara *et al.* (2016) in their article also stated that Vaseline

is safe to use on the skin. Vaseline can be dangerous if swallowed or in contact with the eyes (Heller, 2021). Based on this description, it is known that vaseline does not have toxic potential which can cause irritation if used appropriately, this is also supported by research results from Maru and Lahoti (2019), Nareswari and Kuncoro (2016), and Mukhlisah *et al.* (2016) which showed that album vaseline did not show skin irritating potential.

The occurrence of erythema in this test is thought to be caused by an imbalance in the skin's normal microflora which causes increased skin sensitivity. According to Seite and Misery (2018), there is a relationship between normal skin microflora, skin barrier function, and skin sensitivity, including skin care products that can improve everything. Skin can be influenced by the environment, genetics, diet, and lifestyle (Pratiwi and Susanti, 2021). This imbalance can also be influenced by the presence of external parasites such as mites, fleas, ticks, or fleas because they can also have toxic effects (Guner *et al.*, 2021; Krol *et al.*, 2019). Erythema is thought

to also occur due to the possibility that the test animal's skin was scratched during shaving so that the skin was injured, causing the skin barrier to be disrupted and causing permeability to increase so that the ointment was absorbed percutaneously, which should be indicated for topical use, similar to what was declared by Hakim *et al.* (2018).

Simplicial ointment which is based on vaseline album is an epidermal ointment that after being applied topically to the skin will not be absorbed and only produces local effects and is intended to protect the skin (Djarami, 2022). The saponin contained in the preparation can trigger irritation of mucous membranes such as skin at certain levels because of its nature as an irritant (Brandenburg, 2018; Janjic, 2021). Laras *et al.* (2014), also declared that the saponin contained in the mangosteen rind extract is capable of causing irritation to the skin due to the activity of saponin as a surfactant, however, the results of their research show an irritation index of 0 which is thought to be caused by the concentration of the saponin contained being still in the tolerable range. According to Zeng *et al.* (2020), saponins from *Periploca forrestii* can induce Atopic Dermatitis by modulating macrophage activation. Based on the description above, saponin content at certain concentrations can trigger erythema, however, in this study, false positives occurred so further research needs to be carried out to ensure that the saponin concentration is still within a tolerable range so that it does not affect the emergence of skin irritation reactions or modulate macrophage activation such as in cases of atopic dermatitis.

Body Weight Evaluation

The results of this study showed that there was no weight loss at the end of the observation period which is presented in Table 6, this indicates the absence of systemic toxicity (Merdana *et al.*, 2020b). Based on the paired t-test, a significance value of 0,129 ($p > 0,05$) was obtained, which means that the change in body weight between the treatment group and the control group was not significantly different, indicating that there was no effect of treatment on body weight. These results are in line with the

research results of Zahi *et al.* (2015), on noni fruit extract and Banerjee *et al.* (2013), on transdermal patch prophylaxis against Anatoxin-A poison. In general, changes in a mouse's body weight will reflect death after exposure to harmful substances. Changes in body weight are a marker of the adverse effects of drugs and chemicals which will be a concern if there is a weight loss of more than 10% of the initial weight (Zahi *et al.*, 2015). In the first 6-hour of observation, it was seen that almost all the test animals experienced weight loss (Figure 4), this was thought to be influenced by stress due to the restraint applied during bandaging and removing the bandage after the 24-hour period of exposure to the test material. Guedri *et al.* (2017), stated that there is a relationship between stress due to restraint and weight loss, which can refer to a decrease in food intake and consumption of energy reserves. This is also supported by the findings of Sari *et al.* (2016), in their research regarding the acute dermal toxicity of areca nut extract at a dose of 15.000 mg/kg BW that there was a decrease on the 2-day of observation which was thought to be due to stress due to bandaging during treatment.

Dermal Acute Toxicity Assessment

In this study, a dose of 2000 mg/kg BW was the highest dose used based on The OECD Guideline for Testing of Chemicals – No. Test: 402. During the evaluation, no abnormal behavioral changes were found indicating toxicity, no mortality occurred, and reversibility was achieved as seen from hair growth at the end of the observation period. Based on the analysis of the erythema and edema scoring results, the PII was 0,75 in the control group and 1,00 in the treatment group so it was categorized as slightly irritating based on the Amended Draize Test. The PII calculation results were invalid because there were false positives so it could be assumed that hibiscus leaf simplicial ointment was not irritating because the PII value was not much different from the control group. The acute dermal LD50 value could not be analyzed using the Thompson-Weil method because there were no deaths during the test so only the pseudo acute dermal LD50 could be obtained. LD50 is declared as pseudo LD50 if

the maximum dose given to test animals does not cause death (Hafid and Rahayu, 2022). Based on the description above, according to the Globally Harmonized system, hibiscus leaf simplicial ointment 40% is classified into category 5/unclassified with an acute dermal LD50 value of > 2000 mg/kg BW, which means the test material may be dangerous if it comes into contact with the skin (OECD, 2017).

CONCLUSION

It can be concluded that hibiscus leaf simplicial ointment with a concentration of 40% was safe to use topically on the skin with the highest dose that can still be administered being > 2000 mg/kg BW.

ACKNOWLEDGEMENTS

The author would like to thank the Faculty of Veterinary Medicine, Udayana University, the Bali "Eka Karya" Botanical Garden Characterization Laboratory at the National Research and Innovation Agency (BRIN), the Tabanan Center for Post-Harvest Processing of Medicinal Plants (P4TO), and the Technology Laboratory, Faculty of Pharmacy, Mahasaraswati University, Denpasar.

REFERENCES

- Adiyasa, M. R., & Meiyanti. (2021). Review Article: Pemanfaatan obat tradisional di Indonesia: distribusi dan faktor demografis yang berpengaruh. *Jurnal Biomedika dan Kesehatan*, 4(3), 130–138.
- Al-Idrus, H. R., Iswahyudi, I., & Wahdaningsih, S. (2014). Uji Aktivitas Antioksidan Ekstrak Etanol Daun Bawang Mekah (*Eleutherine americana* Merr.) Terhadap Gambaran Histopatologi Paru Tikus (*Rattus norvegicus*) Wistar Jantan Pasca Paparan Asap Rokok. *Jurnal Fitofarmaka Indonesia*, 1(2), 51–60.
- Al-Snafi, A. E. (2018). Chemical constituents, pharmacological effects and therapeutic importance of *Hibiscus rosa-sinensis*-A review. *IOSR Journal of Pharmacy*, 8(7), 101–119.
- Arts, J. W. M., Kramer, K., Arndt, S. S., & Ohl, F. (2014). Sex Differences in Physiological Acclimatization after Transfer in Wistar Rats. *Animals*, 4, 693–711.
- Baldisserotto, A., Buso, P., Radice, M., Dissette, V., Lampronti, I., Gambari, R., Manfredini, S., & Vertuani, S. (2018). *Moringa oleifera* Leaf Extracts as Multifunctional Ingredients for "Natural and Organic" Sunscreens and Photoprotective Preparations. *Molecules*, 23(664), 1–16.
- Banerjee, S., Chattopadhyay, P., Ghosh, A., Pathak, M. P., Singh, S., & Veer, V. (2013). Acute Dermal Irritation, Sensitization, and Acute Toxicity Studies of a Transdermal Patch for Prophylaxis Against (+) Anatoxin-A Poisoning. *International Journal of Toxicology*, 32(4), 308–313.
- Brandenburg, W. E. (2018). Phytodermatitis: A Brief Review of Human Skin Reactions Caused by The Kindom Plantae. *Journal of Plant Pathology Research*, 1(1), 1–5.
- Czarnowicki, T., Malajian, D., Khattri, S., Rosa, J. C., Dutt, R., Finney, R., Dhingra, N., Xiangyu, P., Xu, H., Estrada, Y., Zheng, X., Gilleaudeau, P., Sullivan-Whalen, M., Suarez-Farinas, M., Shemer, A., Krueger, J. G., & Guttman-Yassky, E. (2015). Petrolatum: Barrier repair and antimicrobial responses underlying this "inert" moisturizer. *Journal Allergy Clinical Immunology*, 137(4), 1091–1102.
- Davis, S. E., Tulandi, S. S., Datu, O. S., Sangande, F., & Pareta, D. N. (2022). Formulasi dan Pengujian Sediaan Salep Ekstrak Etanol Daun Kembang Sepatu (*Hibiscus rosa-sinensis* L.) Dengan Berbagai

- Variasi Basis Salep. *Jurnal Biofarmasetikal Tropis*, 5(1), 66–73.
- Dharma, M. A., Nocianitri, K. A., & Yusasrini, N. L. A. (2020). Pengaruh Metode Pengeringan Simplisia Terhadap Kapasitas Antioksidan Wedang Uwuh. *Jurnal Ilmu dan Teknologi Pangan*, 9(1), 88–95.
- Djarami, J. (2022). Penyuluhan Tentang Obat Sediaan Salep kepada Masyarakat di Desa Hila. *Jurnal JPIKES*, 2(1), 53–55.
- Efendy, J. (2018). Aktivitas Harian dan Deteksi Stress Pada Sapi Peranakan Ongole (PO). *Maduranch*, 3(2), 53–58.
- Endarini, L. H. (2016). Farmakognisi dan Fitokimia. Edisi 1. Kementerian Kesehatan, pp: 11–15.
- Guedri, K., Frih, H., Chettoum, A., & Rouabhi, R. Chronic Restraint Stress Induced Neurobehavioral Alterations and Histological Changes in Rat. *Toxicology Environment Health Science*, 9(2), 123–129.
- Guner, R. Y., Tosun, M., Akyol, M., & Hayta, S. B. (2021). Demodex infestation as a cause of sensitive skin in a dermatology outpatient clinic. *Journal Cosmetic Dermatology*, 1–6.
- Hafid, M., & Rahayu. (2022). Uji Toksisitas Akut (LD50) Ekstrak Etanol Daun Gedi Merah (*Abelmoschus manihot*) Asal Sorong Selatan terhadap Mencit (*Mus musculus*). *Fito Medicine: Journal Pharmacy and Sciences*, 12(2), 84–87.
- Hakim, Z. R., Purbarini, K. A., & Tjiptasurasa, T. T. (2018). Uji Iritasi Akut Dermal Pada Hewan Uji Kelinci Albino Terhadap Sediaan Body Lotion Ekstrak Kulit Biji Pinang (*Areca catechu L.*). *Farmaka*, 18(1), 1–13.
- Hamishehkar, H., Same, S., Adibkia, K., Zarza, K., Shokri, J., Taghaee, M., & Kouhsoltani, M. (2015). A comparative histological study on the skin occlusion performance of a cream made of solid lipid nanoparticles and Vaseline. *Research in Pharmaceutical Sciences*, 10(5), 378–387.
- Handoyo, D. L. Y., & Pranoto, M. E. (2020). Pengaruh Variasi Suhu Pengeringan Terhadap Pembuatan Simplisia Daun Mimba (*Azadirachta Indica*). *Jurnal Farmasi Tinctura*, 1(2), 45–54.
- Heller, J. L., Emeritus, Zieve, D., & Conaway B. (2021). Petroleum jelly overdose. MedlinePlus.
- Janjic, V. (2021). Plant-Caused Skin Disorders. Edisi 1. Cambridge Scholars Publishing.
- Krismayogi, G. A., Ratnayanti, I. G. A.D., Linawati, N. M., Wiryawan, I. G. N. S., Sugiritama, I. W., Wahyuniari, I. A. I., & Arijana, I. G. K. N. (2018). Purple Cabbage Extract Cream Effect on Erythema Score of Male Wistar Rat's Back Skin Exposed To UV-B Radiation. *Biomedical & Pharmacology Journal*, 11(1), 343–351.
- Krissanti, I., Hanifa, R., & Dwiwina, R. G. (2023). Efektivitas dan Pengaruh Kombinasi Anestesi Ketamine-Xylazine pada Tikus (*Rattus norvegicus*). *Gunung Djati Conferences Series*, 245–252.
- Krol, G., Tomaszewska, A., Wrobel, G., Paprocka, P., Durnas, B., Piktel, E., & Bucki, R. (2019). Toxicity of Parasites and their unconventional use in medicine. *Annals of Agricultural and Environmental Medicine*, 26(4), 523–531.
- Kuncari, E. S., Iskandarsyah, & Praptiwi. (2015). Uji Iritasi dan Aktivitas Pertumbuhan Rambut Tikus Putih: Efek Sediaan Gel Apigenin dan Perasan Herba Seledri (*Apium graveolens L.*). *Media Litbangkes*, 25(1), 15–22.

- Laras, A. A. I. S., Swastini, D. A., Wardana, M., & Wijayanti, N. P. A. D. (2014). Uji Iritasi Ekstrak Etanol Kulit Buah Manggis (*Garcinia mangostana L.*). *Jurnal Farmasi Udayana*, 3(1), 74–77.
- Lazuardi, M. (2019). Bagian Khusus Ilmu Farmasi Veteriner. Edisi 1. Airlangga University Press, pp: 59–75.
- Lestari Dewi, N. K., Jamhari, M., & Isnainar. (2017). Study of Plant Utilization as Traditional Medicines at Tolai Village, Torue Subdistric, Parigi Moutong District. *E-JIP BIOL*, 5(2), 92–108.
- Liu, E., & Fan, J. (2018). Fundamentals of Laboratory Animal Science. Edisi 1. CRC Press.
- Maarouf, M., Kromenacker, B. W., Brucks, E. E., & Shi, V. Y. (2019). Expedited Resolution of 5-Fluorouracil-Induced Reaction and Barrier Dysfunction with White Petrolatum. *SKIN The Journal of Cutaneous Medicine*, 3(4), 279–282.
- Mappasomba, M., Wirasmanto, B., Malaka, M. H., Wahyuni, & Sahidin. (2019). Penapisan Fitokimia dan Uji Toksisitas Akut Ekstrak Metanol Beberapa Tanaman Obat Terhadap Larva Udang *Artemia Salina* Leach. *Pharmauho*, 5(2), 30–34.
- Maru, A. D., & Lahoti, S. (2019). Formulation and Evaluation of Ointment Containing Sunflower Wax. *Asian Journal of Pharmaceutical and Clinical Research*, 12(8), 115–120.
- Meena, A. K., Jain, A., Pandey, K., & Singh, R. K. (2014). Acute Toxicity and Genotoxic Activity of *Hibiscus rosa sinensis* Flower Extract. *American Journal of Phytomedicine and Clinical Therapeutics*, 2(4), 524–529.
- Merdana, I. M., Arjana, A. A. G., Widyastuti, S. K., Tetrania, T., Budiasa, K., Sudimartini, L. M., & Sudira, I. W. (2020a). Assesment of the Dermal Acute Irritation Potential of Natural Veterinary Medicine Minyak Rajas in Albino Rabbits. *Journal of Pharmaceutical Research International*, 32(10), 17–24.
- Merdana, I. M., Azizati, S. T. K. N., Arjana, A. A. G., Adi, A. A. A. M., & Sudira, I. W. (2020b). Penilaian Potensi Toksisitas Akut Dermal Obat Hewan Alami Minyak Rajas pada Tikus Wistar. *Buletin Veteriner Udayana*, 12(2), 205–214.
- Mukhlisah, N. R. I., Sugihartini, N., & Yuwono, T. (2016). Daya Iritasi dan Sifat Fisik Sediaan Salep Minyak Atsiri Bunga Cengkeh (*Syzygium aromaticum*) pada Basis Hidrokarbon. *Majalah Farmaseutik*, 12(1), 372–376.
- Nareswari, N., & Kuncoro, A. (2016). Pembuatan Salep Minyak Atsiri Daun Jeruk Limau (*Citrus amblycarpa*) dan Uji Stabilitas Terhadap Tipe Basis yang Digunakan. *Biofarmasi*, 14(2), 63–68.
- Nath, P., & Yadav, A. K. (2014). Acute and sub-acute oral toxicity assessment of the methanolic extract from leaves of *Hibiscus rosa-sinensis L.* in mice. *Journal of Intercultural Ethnopharmacology*, 4(1), 70–73.
- OECD. (2017). Test No. 402: OECD Guideline for The Testing of Chemical – Acute Dermal Toxicity: Fixed Doses Procedure. OECD Publishing.
- Ordóñez-Toro, A., Montero-Vilchez, T., Muñoz-Baeza, J., Sanabria-De-la-Torre, R., Buendía-Eisman, A., & Arias-Santiago, S. (2022). The Assessment of Skin Homeostatic Changes after Using Different Types of Excipients in Healthy Individuals. *International Journal of Environmental Research and Public Health*, 19(16678), 1–11.

- Petruk, G., Giudice, R. D., Rigano, M. M., & Monti, D. M. (2018). Antioxidants from Plants Protect against Skin Photoaging. *Oxidative Medicine and Cellular Longevity*, 1–11.
- Prasetya, I. P. D., Arijana, I. G. K. N., Linawati, N. M., Sugiritama, I. W., & Sudarmaja, I. M. (2020). Krim Ekstrak Kulit Buah Naga Super Merah (*Hylocereus costaricensis*) Meningkatkan Kelembapan Kulit Tikus Wistar (*Rattus norvegicus*) yang Dipapar Sinar Ultraviolet B. *Jurnal Medika Udayana*, 10(8), 86–91.
- Pratiwi, E. D., & Susanti. (2021). Manfaat Probiotik dalam Perawatan Kulit: Review. *Majalah Farmasetika*, 6(4), 359–374.
- Pratiwi, S., & Husni, P. (2017). Artikel Tinjauan: Potensi Penggunaan Fitokonstituen Tanaman Indonesia sebagai Bahan Aktif Tabir Surya. *Farmaka*, 15(4), 18–25.
- Puspitasari, V., Wahjuni, R. S., Saputro, A. L., Hamid, I. S., & Wibawati, P. A. (2021). Effectiveness of Clove Flower Extract (*Syzygium Aromaticum L.*) as Analgesic on Licking Time Reaction in Male Mice with Formalin Induction. *Jurnal Medik Veteriner*, 4(2), 226–230.
- Rahmi, H. (2017). Review: Aktivitas Antioksidan dari Berbagai Sumber Buah-buahan di Indonesia. *Jurnal Agrotek Indonesia*, 2(1), 34–38.
- Ridwan, Y., Satrija, F., & Handharyani, E. (2020). Toksisitas Akut Ekstrak Daun Miana (*Coleus Blumei Benth*) pada Mencit Mus Musculus. *Acta Veterinaria Indonesia*, 8(1), 55–61.
- Rivai, H., Wahyuni, A. H., & Fadhilah, H. (2013). Pembuatan dan Karakterisasi Ekstrak Kering Simplisia Jati Belanda (*Guazuma ulmifolia Lamk*). *Jurnal Farmasi Higea*, 5(1), 1–8.
- Samirana, P. O., Pratiwi, D. M. N., Musdwiyuni, N. W., Andhini, D. A. A., Mahendra, A. M. Mahendra, A. M., & Yadnya-Putra, A. A. G. R. (2018). Uji Pendahuluan Toksisitas Akut Dermal Sediaan Salep Ekstrak Etanol 70% Daun Binahong (*Anredera scandens (L.) Moq.*) Tersandar. *Jurnal Kimia*, 12(2), 107–112.
- Sari, L. M., Suyatna, F. D., Subita, G. P., & Auerkari, E. I. (2016). Acute Dermal Toxicity Study of *Areca catechu Linn.* Extract in Sprague-Dawley Rats. *Asian Journal of Pharmaceutical and Clinical Research*, 9(3), 1–3.
- Sasmito, W. A., Wijayanti, A. D., Fitriana, I., & Sari, P. W. (2015). Pengujian Toksisitas Akut Obat Herbal Pada Mencit Berdasarkan Organization for Economic Co-operation and Development (OECD). *Jurnal Sain Veteriner*, 33(2), 234–239.
- Seite, S., & Misery, L. (2018). Hypothesis Letter-Skin sensitivity and skin microbiota: Is there a link?. *Experimental Dermatology*, 27, 1061–1064.
- Simaremare, E. S., Holle, E., Budi, I. M., & Yabansabra, Y. Y. (2015). Analisis Perbandingan Efektifitas Antinyeri Salep Daun Gatal dari Simplisia *Laportea decumana* dan *Laportea sp.* *Pharmacy*, 12(1), 1–10.
- Siregar, R. S., Tanjung, A. F., Siregar, A. F., Salsabila, Bangun, I. H., & Mulya, M. O. (2020). Studi Literatur Tentang Pemanfaatan Tanaman Obat Tradisional. *Seminar of Social Sciences Engineering & Humaniora*, 385–391.
- Soejanto, A. S. (2017). Pemberian Krim Ekstrak Metanolik Buah Delima Merah (*Punica granatum*) Menghambat Penurunan Jumlah Kolagen Dermis Kulit Mencit (*Mus musculus*) yang Dipapar Sinar Ultraviolet B.

- E-JURNAL Indonesian Journal of Anti Aging Medicine*, 1(1), 1–9.
- Solikhah, T., Rani, C. A. M., Septiani, M., Putra, Y. A. S., Rachmah, Q., Solikhah, G. P., Agustono, B., Yunita, M. N., & Purnama, M. T. E. (2022). Antidiabetic of *Hylocereus polyrhizus* peel ethanolic extract on alloxan induced diabetic mice. *Iraqi Journal of Veterinary Sciences*, 36(3), 797–802.
- Sudira, I. W., Merdana, I. M., & Qurani, S. N. (2019). Preliminary Phitochemical Analysis of Guava Leaves (*Psidium guajava L.*) as Antidiarrheal in Calves. *Advances in Tropical Biodiversity and Environmental Sciences*, 3(2), 21–24.
- Triana, N. M., Wilujeng, E., Putri, M. W. H., Yuda, D. M. P., Hardiono, A. L., Purnama, M. T. E., & Fikri, F. (2020). Antiproliferation effects of *Glycine max Linn* ethanolic extract on induced mammary gland carcinoma in albino rats. *In IOP Conference Series: Earth and Environmental Science*, 441(1), 012103.
- Trisnajayanti, I. (2013). Pengaruh Basis Salep Hidrokarbon dan Basis Salep Serap Terhadap Sediaan Salep Ekstrak Daun Bunga Sepatu (*Hibiscus rosa-sinensis L.*). Parapemikir: *Jurnal Ilmiah Farmasi*, 2(3).
- United Nations. (2011). Globally Harmonized System of Classification and Labelling of Chemicals (GHS).
- Yassir, M., & Asnah. (2018). Pemanfaatan Jenis Tumbuhan Obat Tradisional di Desa Batu Hamparan Kabupaten Aceh Tenggara. *Jurnal Biotik*, 6(1), 17–34.
- Zahara, Y., Dewi, R., & Saptarini, E. (2016). Efektivitas Penggunaan White Petroleum Jelly untuk Perawatan Luka Tekan Stage 1 di Ruang di Rawat Inap Siloam Hospital Lippo Village. *Indonesian Journal of Nursing Health Science*, 1(1), 15–32.
- Zahi, A. K., Hamzah, H., Hutheyfa, S., Shaari, M. R., Sithambaram, S., & Othman, H. H. (2015). Acute and Sub-Acute Dermal Toxicity Studies of *Morinda citrifolia L.* Fruit Extract in Sparague Dawley Rats. *Asian Journal of Pharmaceutical and Clinical Research*, 8(2), 400–408.
- Zeng, L., Liu, Y., Xing, C., Huang, Y., Sun, X., & Sun, G. (2020). Saponin from *Periploca forrestii* Schltr Mitigates Oxazolone-Induced Atopic Dermatitis via Modulating Macrophage Activation. *Hindawi*, 1–13.
- Zulfiana, D. (2014). Pengujian Toksisitas Akut Oral dan Dermal pada Biolarvasida *Metarhizium anisopliae* Terhadap Tikus Putih Sprague Dawley. *Al-Kauniyah Jurnal Biologi*, 7(1), 1–8.
