

DOI: 10.4274/jtad.galenos.2023.27247

J Turk Acad Dermatol 2023;17(2):54-58

Telangiectasia Macularis Eruptiva Perstans: a Case Report and Review Literature

© Nyoman Suryawati¹, © Herman Saputra²

¹Udayana University Faculty of Medicine, Prof. dr. I.G.N.G. Ngoerah General Hospital Denpasar, Department of Dermatology and Venereology, Bali, Indonesia

²Udayana University Faculty of Medicine, Prof. dr. I.G.N.G. Ngoerah General Hospital Denpasar, Department of Pathology Anatomy, Bali, Indonesia

ABSTRACT

Telangiectasia macularis eruptiva perstans (TMEP) is a rare variant of cutaneous mastocytosis with adults predominantly. It is characterized by erythematous or yellow-brown macules with telangiectasias on the trunk and upper limbs. Diagnosis is based on the appearance of skin lesions and histopathological findings. Dermoscopy is a useful diagnostic tool, as it can show a characteristic reticular pattern. We will report a TMEP case, focusing on clinical findings, dermoscopy, histopathology, and immunohistochemistry examination.

Keywords: Telangiectasia macularis eruptiva perstans, Dermoscopy, Histopathology, Immunohistochemistry

Introduction

Mastocytosis is a group of diseases characterized by abnormal proliferation and accumulation of mast cells within various organs [1]. These cells release histamine and other inflammatory mediators, which can result in pruritus, flushing, nausea, vomiting, abdominal pain, diarrhea, vascular instability, and headache [1,2]. Mastocytosis can be classified as either cutaneous mastocytosis (CM) or systemic mastocytosis, the latter of which can affect the bone marrow, liver, spleen, lymph nodes, and digestive tract [1,2,3,4].

CM is characterized by the proliferation and accumulation of mast cells in the skin [5,6,7,8]. There are three main types: maculopapular cutaneous mastocytosis (MPCM), diffuse CM, and solitary mastocytoma [1,7]. Maculopapular CM is further divided into papular/plaque variants, urticaria pigmentosa (UP), and telangiectasia macularis eruptiva perstans (TMEP) [4]. The diagnosis of CM is confirmed by dermal infiltration of mast cells, visualized with hematoxylin and eosin staining, or by using special stains such as Giemsa, Toluidin blue, or Astra blue [1,3,4].

TMEP is a rare variant of skin mastocytosis, occurring in <1% of patients. It most commonly occurs in adults, although some cases have been reported in children [6,9]. Diagnosis of TMEP is based on clinical findings and histological examination, with the final diagnosis by immunohistochemistry with tryptase and c-kit [7]. Recently, dermoscopy was reported as diagnostic equipment [3] because it reveals a characteristic reticular pattern [4,7,9]. Here, we describe a case of TMEP focusing on clinical, dermoscopic, histopathological, and immunohistochemical findings.

Case Report

A 51-year-old man has been experiencing an erythematous skin rash on his chest, back, and upper limbs for 11 years. The lesions typically improve within a few months, but leave hyperchromic lesions. He reports no itchiness associated with the rash. He denies experiencing fever, chest pain, abdominal pain, weight loss, diarrhea, syncope, bone pain, joint pain, or oral ulcers. He has been treated with anti-allergic and antihistamine tablets, as well as corticosteroid cream,



Address for Correspondence: Nyoman Suryawati MD, Udayana University Faculty of Medicine, Department of Dermatology and Venereology, Prof. dr. I.G.N.G. Ngoerah General Hospital Denpasar, Bali, Indonesia

Phone: +62 817447279 **E-mail:** suryawati@unud.ac.id **ORCID ID:** orcid.org/0000-0002-5959-3934

Received: 09.01.2023 **Accepted:** 01.03.2023



© Copyright 2023 by the Society of Academy of Cosmetology and Dermatology / Journal of the Turkish Academy of Dermatology published by Galenos Publishing House. Licensed under a Creative Commons Attribution-NonCommercial-NoDerivatives 4.0 (CC BY-NC-ND) International License.

with no improvement. He has no personal history of allergies, nor are there any allergies reported in his family. He has a history of hypertension and has been on amlodipine for the past three years. The physical examination revealed no abnormalities.

Dermatological status on the chest, back, and upper limbs showed erythematous-brownish macules with size 0.5 to 3 cm, confluent residual hyperchromic macules, and telangiectasia (Figures 1, 2, 3). Darier's sign is negative, and dermoscopy reveals mild erythema, thin tortuous linear vessels, and a delicate pigment network on a yellow-brown background (Figure 4). There was no abnormality on a blood, renal, or liver function test. Histopathology revealed edema in the superficial dermis with inflammatory cells containing lymphocyte and mast cells in the blood vessel's perivascular, periadnexal, and telangiectasia (Figures 5, 6). Giemsa stain showed mast cells in perivascular and periadnexal (Figure 7), highlighted on CD117 immunohistochemical stain (Figures 8, 9).

The patient was diagnosed with TMEP and received treatment with cetirizine 10 mg once daily and ketotifen 1 mg twice daily. Additionally, the patient was advised to avoid histamine-releasing agents such as alcohol, anticholinergic drugs, aspirin, non-steroidal anti-inflammatory drugs, heat, friction, and opioids. Although the patient showed improvement with medication, further evaluation is needed to determine the possibility of systemic involvement. Written informed consent was obtained from the patient.

Discussion

The skin manifestation in TMEP is non-pruritic and tends to be confluent and persistent. Darier's sign is usually negative or weakly positive because of the lesion's lower density of mast cells [6,10]. The mechanism of telangiectasia and erythematous lesions in TMEP is a local release of mediators and angiogenic factors from activated mast cells, which cause permanent vasodilation [4]. The molecular pathogenesis of TMEP remains unclear; several studies have reported

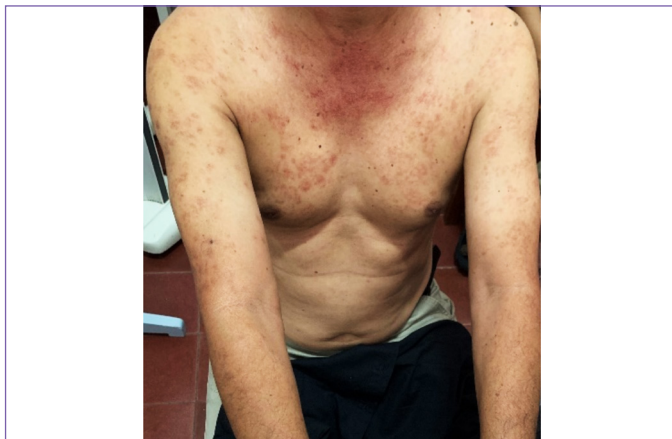

Figure 1. Dermatological status on the chest and upper limb showed erythematous-brownish macules

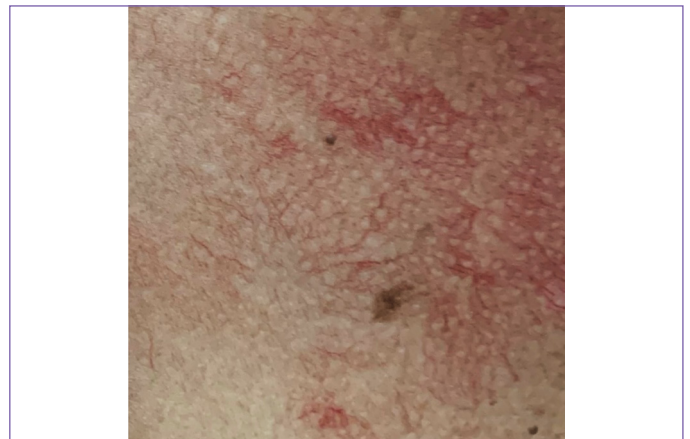

Figure 3. A close-up view of a skin lesion on the chest showed multiple telangiectases

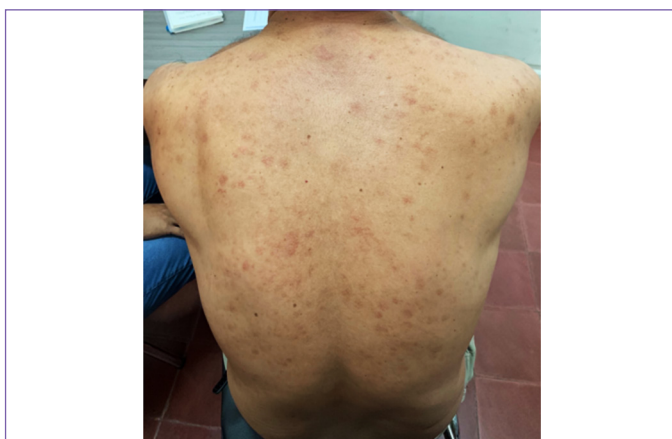

Figure 2. Dermatological status on the back showed erythematous-brownish macules

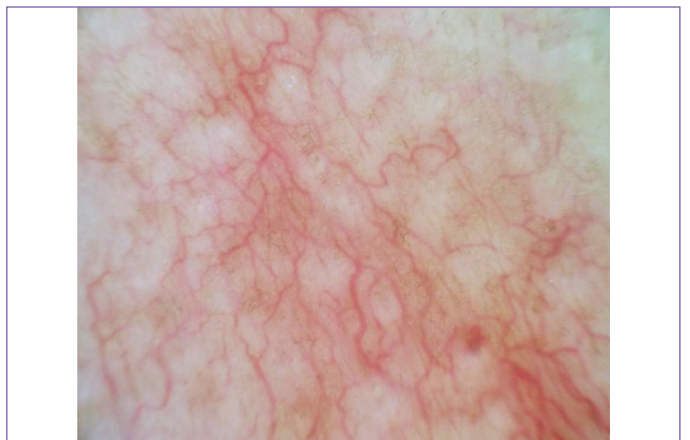

Figure 4. Dermoscopy reveals mild erythema, thin tortuous linear vessels, and a delicate pigment network on a yellow-brown background

point mutations in the *KIT* gene [5,10]. *KIT* is a type III tyrosinase kinase expressed on mast cells and melanocytes and is a major growth factor of mast cells. A cohort study of 34 TMEP patients detected that 12 patients (35.3%) show the *KIT* mutations at codon 816 [10].

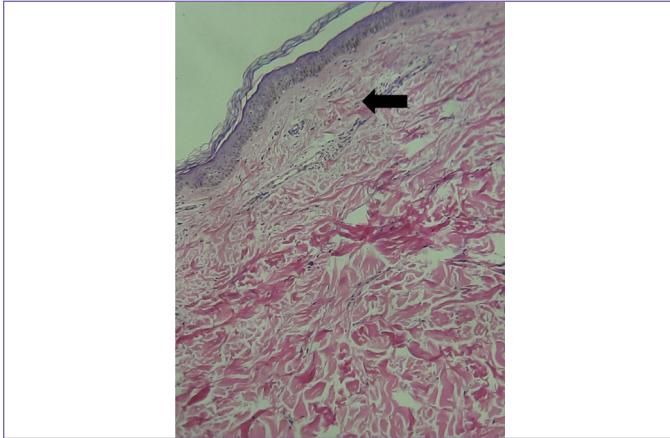


Figure 5. The histopathologic finding with hematoxylin-eosin staining (magnification 100x) revealed edema in the superficial dermis with inflammatory cells containing lymphocyte and mast cells in the perivascular, periadnexal, and telangiectatic vein

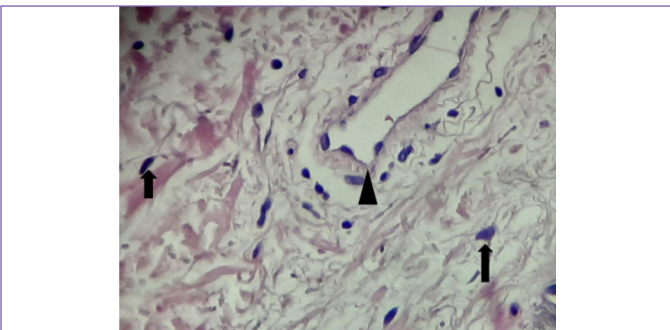


Figure 6. A close-up view showed the mast cell and dilated blood vessel (magnification 400x)

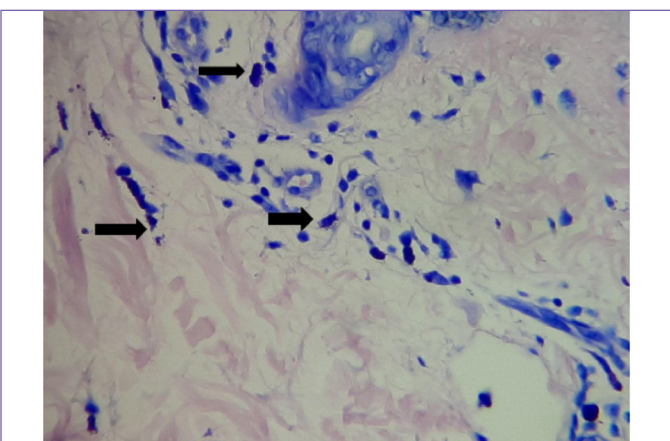


Figure 7. Giemsa stain showed mast cells in perivascular and periadnexal

Dermoscopy, *in vivo* epiluminescence microscopy, is a non-invasive method that provides a rapid and easy evaluation of the color and microstructure of the epidermis, dermo-epidermal junction, and papillary dermis [3,7]. This method not only aids in diagnosing CM but can also differentiate between TMEP and CM variants or other exanthematous skin diseases [3,4]. Akay et al. [4] reported dermoscopy patterns of CM with pigmented network and reticular vascular patterns [9]. The pigmented network was observed mainly in MPCM and UP cases. The reticular vascular pattern was in the TMEP case, corresponding to dilatation and vascular proliferation associated with mast cells in the dermis [4,6,7,9].

Histopathologically the mast cell infiltration of TMEP is predominantly located in the upper third of the dermis and usually clusters around dilated capillaries and superficial venule plexuses [1,4,6]. When the mast cell numbers were within the normal range, the specific stain highlighted these cells, including

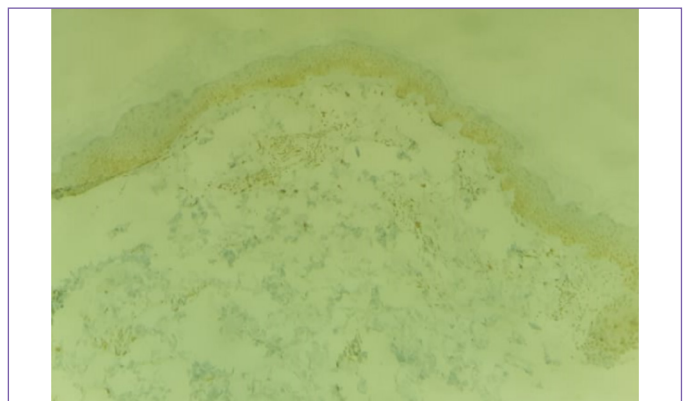


Figure 8. Mast cell was highlighted with CD117 immunohistochemical stain (magnification 100x)

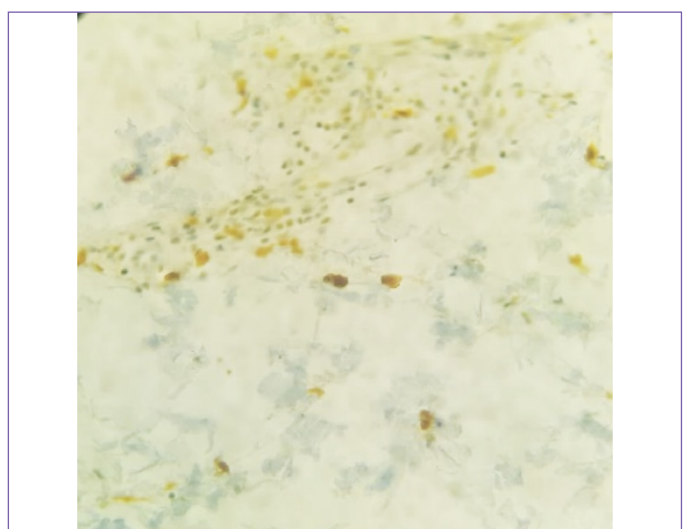


Figure 9. Mast cell was highlighted with CD117 immunohistochemical stain (magnification 400x)

Giemsa and immunohistochemistry with CD117 [6]. Mast cells constitutively express type III receptor tyrosine kinase *KIT* (CD117). It is encoded by *c-kit* proto-oncogene and is involved in mast cell development and survival. *KIT* activation changes result in mast cell accumulation, abnormal migration, and activation in various tissues. This mutation in CM indicates a condition of more aggressive mastocytosis [6].

Diagnosis of TMEP, in our case, is according to the correlation between clinical manifestation, dermoscopic examination, histopathological results, and immunohistochemistry. The clinical finding showed small, irregular reddish-brown telangiectatic macules on the predilection areas (chest, back, and upper limbs), with dermoscopy findings matching the pattern in the TMEP case. The biopsy result showed mast cell infiltration in the upper third of the dermis and around dilated capillaries, highlighted by Giemsa and immunochemistry with CD117 staining.

CM management aims to avoid and to treat symptoms caused by mast cell mediator release [6]. An essential first step is to avoid provocative events such as certain foods, sunlight, heat, cold, alcohol, drugs, or allergens [1,8]. First-line agents include systemic antihistamines [6]. Ketotifen, an antihistamine and mast-cell stabilizer, one of the best treatments for CM, was given once every evening due to its sedative effect. Bilastine, the second generation of H1-antihistamine, was given as a substitutive every morning due to its higher affinity for histamine H1 receptor than cetirizine, lack of cardiac toxicity, and sedation [6]. Second-line treatments include topical calcineurin inhibitors, oral sodium cromolyn, phototherapy, and mast cell degranulation inhibitors [1,6]. Topical glucocorticoids improve pruritus, whealing, and infiltration and can use for limited symptomatic lesions [6,8]. Phototherapy with psoralen ultraviolet A or ultraviolet B therapy can help reduce pruritus and skin symptoms [8]. Total body electron beam therapy has also been reported effective for TMEP treatment [8]. Five hundred eighty-five nm flashlamp-pulsed dye laser reduces the lesions' vascularity [6,8]. The leukotriene antagonists, such as montelukast, have been used for pediatric cases and have shown promising results [1,8].

Most cases of TMEP are confined to the skin; however, systemic involvement may occur in 35-50% of patients within six years or more after onset. The risk increases with age, so it is necessary to monitor patients regularly [5,6]. Several laboratory tests and diagnostic imaging studies can assist in the routine evaluation and establish systemic involvement. Diagnostic recommendations for baseline evaluation of adult mastocytosis patients are complete blood count, liver function tests, serum chemistry and tryptase, bone marrow biopsy, and aspirate. Abdominal ultrasound or CT scan, gastrointestinal endoscopy, bone X-ray, or scan are additional

investigations for the initial evaluation of a mastocytosis patient, especially if a systemic involvement is suspected [2]. In our case, TMEP still needs further evaluation possibility of systemic involvement.

Conclusion

In this case, the diagnosis of TMEP is according to the correlation between clinical findings, dermoscopic examination, histopathological results, and immunohistochemistry with CD117. Our case was treated with cetirizine and ketotifen, and we were also advised to avoid histamine-releasing substances. Although the patient showed improvement with medication, further evaluation is needed to assess the possibility of systemic involvement.

Ethics

Informed Consent: Written informed consent was obtained from the patient.

Peer-review: Internally peer-reviewed.

Authorship Contributions

Surgical and Medical Practices: N.S., Concept: N.S., H.S., Design: N.S., Data Collection or Processing: N.S., H.S., Analysis or Interpretation: N.S., H.S., Literature Search: N.S., H.S., Writing: N.S.

Conflict of Interest: No conflict of interest was declared by the authors.

Financial Disclosure: The authors declared that this study received no financial support.

References

1. Wilmas K, Wohlmuth-Wieser I, Duvic M. Telangiectasia macularis eruptiva perstans: an old terminology, still frequently used. *Dermatol Online J* 2017;23:13030/qt6zx243zm.
2. Turchin I, Barankin B, Schloss E. Unusual cutaneous findings of urticaria pigmentosa and telangiectasia macularis eruptiva perstans associated with marked myelofibrosis. *Int J Dermatol* 2006;45:1215-1217.
3. Miller MD, Nery NS, Gripp AC, Maceira JP, Nascimento GM. Dermatoscopic findings of urticaria pigmentosa. *An Bras Dermatol* 2013;88:986-988.
4. Akay BN, Kittler H, Sanli H, Harmankaya K, Anadolu R. Dermatoscopic findings of cutaneous mastocytosis. *Dermatology* 2009;218:226-230.
5. Severino M, Chandresris MO, Barete S, Tournier E, Sans B, Laurent C, Apoil PA, Lamant L, Mailhol C, Laroche M, Fraitag S, Hanssens K, Dubreuil P, Hermine O, Paul C, Bulai Livideanu C. Telangiectasia macularis eruptiva perstans (TMEP): A form of cutaneous mastocytosis with potential systemic involvement. *J Am Acad Dermatol* 2016;74:885-91.e1.
6. Bintanjoyo L, Mae M, Cruz H, Dayrit J. Telangiectasia macularis eruptiva perstans in an Indian man: Correlation between clinical, dermoscopic, histopathological, and immunohistochemical findings. *J Phil Dermatol Soc* 2017;88-90.
7. Vano-Galvan S, Alvarez-Twose I, De las Heras E, Morgado JM, Matito A, Sánchez-Muñoz L, Plana MN, Jaén P, Orfao A, Escribano L. Dermatoscopic

- features of skin lesions in patients with mastocytosis. Arch Dermatol 2011;147:932-940.
8. Alsubait S, Deeb A, Zimmermann N, Bhaskaran J, Salkeni M. Resolution of Telangiectasia Macularis Eruptiva Perstans with Successful Treatment of Synchronous Large Granular Lymphocytic Leukemia. Ann Hematol Oncol 2015;2:1052.
 9. Malakar S, Mukherjee SS. Telangiectasia macularis eruptiva perstans under the dermoscope in the skin of color. Our Dermatology Online. 2018;9:458-459.
 10. Jia QN, Fang K, Qu T. Unilateral telangiectasia macularis eruptiva perstans with an unusual clinical presentation. J Dermatol 2018;45:e201-e202.