

OPEN ACCESS MACEDONIAN
JOURNAL OF MEDICAL SCIENCES

oa
mjms eISSN 1857-9655
<https://www.id-press.eu/mjms>

Open Access Maced J Med Sci. 2019 Feb 28; 7(4):507-698



Open Access Maced J Med Sci (OAMJMS) is an international peer-reviewed, Open Access journal published four times per year. **Indexed in:** Bielefeld Academic Search Engine (BASE), CAB Direct, CiteFactor, CNKI Scholar, CrossRef DOI, DeepDyve, Directory of Open Access Journals (DOAJ), Directory of Open Access scholarly Resources (ROAD), Europe PMC, Global Health database, Global Impact Factor (GIF), Google Scholar, Harvard Library [HOLLIS +], HINARI Access to Research Initiative, JournalTOCs, Mendeley, NLM Catalog, OpenAIRE, Open Academic Journals Index (OAJI), Open Access Library (OALib), pubget, PubMed, PubMed Central, PubMed Central CANADA, SciLit, SciRew, Scopus, SouthEast European Science Advanced through Evaluation (SEESAmE), The Knowledge Network, Virtual Library of Macedonia (COBISS.MK), Western Theological Seminary, WorldCat. **Publisher:** ID Design Press, Rajko Zhinzifov No. 48, 1000 Skopje, Republic of Macedonia. OAMJMS Online (eISSN 1857-9655) offers free access to all articles at <https://www.id-design.eu/mjms/>

Editorial Team

Editors-in-Chief

Prof. Dr Mirko Zhivko Spiroski, Faculty of Medicine, Ss Cyril and Methodius University of Skopje, Skopje, Republic of Macedonia, Republic of Macedonia

Prof. Dr Doncho Donev, Institute of Social Medicine, Medical Faculty, Ss Cyril and Methodius University of Skopje, Skopje, Republic of Macedonia

Prof. Dr Olivera Stojceva-Taneva, University Clinic of Nephrology, Republic of Macedonia

Deputy Editors-in-Chief

Dr Borislav D Dimitrov, Academic Unit of Primary Care and Population Sciences Faculty of Medicine University of Southampton South Academic Block (Level C) Southampton General Hospital Southampton SO166YD England, UK

MD, MSc, PhD, MRCPsych Elizabeta Mukaetova-Ladinska, Old Age Psychiatry, Newcastle University, United Kingdom

MD, PhD candidate Marko Spasov, University Clinic of Traumatology, Orthopaedics, Anesthesia, Reanimation, Intensive Care and Emergency Department; Medical Faculty, Skopje., Republic of Macedonia

MD, MSc Sasho Stoileski, Institute for Occupational Health of Republic of Macedonia - Skopje, WHO Collaborating Center, GA2LEN Collaborating Center, II Makedonska brigada 43, 1000 Skopje, Republic of Macedonia

Layout Editor and Electronic Publishing

MSc, Eng Ivo Spiroski, ID Design 2012, Skopje, Republic of Macedonia

Evidence Based Medicine

Prof. Dr. Katarina Stavric, Children Hospital Skopje, Macedonia, Vodnjanska 17, University "Ss Cyril and Methodius", Skopje, Republic of Macedonia

Editorial Board

DDS, MS, PhD, Associate Professor Nikola Angelov, Director of the Pre-Doctoral Periodontics Clinic, Loma Linda University School of Dentistry, Department of Periodontics. Loma Linda, CA, 92350, United States

Assist. Prof. Dr. Ramush Bejiqi, University Clinical Centre of Kosovo, Paediatric Clinic, Albania

Prof. Semra Čavaljuga, Department of Epidemiology and Biostatistics, Faculty of Medicine, Sarajevo, Bosnia and Herzegovina

MD Pei-Yi Chu, Diagnostic and research pathologist, Department of Surgical Pathology, Changhua Christian Hospital, Taiwan. Address: 135 Nan-Shiao Street, Changhua 500-06., Taiwan, Province of China

MD, PhD Ivo Donkov, Staff Urologist, Lincoln County Hospital, United Kingdom

Prof. Dr. Aleksandar Dimovski, Institute of Pharmaceutical Chemistry, Faculty of Pharmacy, University "Ss Kiril and Metodij", Skopje, Republic of Macedonia

MD, PhD Andrew J. Dwork, Departments of Pathology and Cell Biology and Psychiatry, College of Physicians and Surgeons of Columbia University; Division of Molecular Imaging and Neuropathology, New York State Psychiatric Institute, Unit 62, 722 West 168th Street, New York, NY 10032, United States

MD, PhD Dimitar G. Efremov, Molecular Hematology, International Centre for Genetic Engineering and Biotechnology (ICGEB), Rome, Italy

Adriana Galan, Department of Health Programmes and Health Promotion, Institute of Public Health, Bucharest, Romania

Prof. Tania Santos Giani, Estacio de Sa University, in Health Sciences, Brazil

PhD Iva Ivanovska, Harvard Medical School, Department of Genetics, 77 Avenue Louis Pasteur, NRB room 239, Boston, MA 02115, United States

MD, PhD Jerzy Jablęcki, Associate Professor, Division of General Surgery St. Jadwiga of Silesia Hospital, Trzebnica; Head, Subdepartment of Hand Surgery an Replantation St Jadwiga of Silesia Hospital, Trzebnica; Professor,

Department of Public Health, State Higher Professional Medical School, Opole, Poland. 55-100 Trzebnica, ul. Prusicka 53, Poland

MD Mehrdad Jalalian Hosseini, Khorasan-e Razavi Blood Center, Mashhad, Iran, Islamic Republic of

PhD Radka Kaneva, Department of Medical Chemistry and Biochemistry, Medical University - Sofia, Bulgaria

Prof. Dr. Kostandina Leonida Kometi-Pekevskaa, Ss Cyril and Methodius University of Skopje, Faculty of Medicine, Skopje, Republic of Macedonia

MD, PhD Branko Malenica, Department of Immunology, Clinical Hospital Center Zagreb, Zagreb University School of Medicine, Zagreb, Croatia

Prof. Dr. Elida Mitevska, Institute of Histology and Embriology, Faculty of Medicine, Ss Cyril and Methodius University of Skopje, Skopje, Republic of Macedonia

MD, PhD Marija Mostarica-Stojković, Institute of Microbiology and Immunology, University of Belgrade School of Medicine, Belgrade, Serbia

PhD Vesna Nikolova-Krsteovski, Harvard Institutes of Medicine, HIM-201, 4 Blackfan Circle, Boston, MA, 02134, United States

Prof. Dr. Nikola Panovski, Institute of Microbiology and Parasitology, Faculty of Medicine, Skopje, Republic of Macedonia

MD, BIDMC Iva Petkovska, Beth Israel Deaconess Medical CenterRadiology W CC - 3 330 Brookline Ave. Boston, MA 02215, United States

Prof. Dr. Gordana Petrushevska, Institute of Pathology, Medical Faculty, University of "Ss. Cyril and Methodius" – Skopje, Republic of Macedonia

Prof. Enver Roshi, Dean of Faculty of Public Health, Medical University of Tirane, Chief of Epidemiological Observatory, National Institute of Public Health. Address: Rruga e Dibrës, Str. 371, Tirana, Albania

MD, PhD Gorazd B. Rosoklija, Professor at Columbia University and member of the Macedonian Academy of Sciences and Arts, United States

Prof. Dr. Aleksandar Sikole, University Clinic for Nephrology, Faculty of Medicine, Ss Cyril and Methodius University of Skopje, Skopje, Republic of Macedonia

MD, FESC Gianfranco Sinagra, Department of Cardiology, "Ospedali Riuniti" and University of Trieste, Ospedale Cattinara – Strada di Fiume, 447, 34149 – Trieste, Italy

MD, PhD Rumen Stefanov, Information Centre for Rare Diseases and Orphan Drugs (ICRDOD), Bulgaria; Department of Social Medicine, Medical University of Plovdiv, Bulgaria

Prof. Dr. Vesna Velikj-Stefanovska, Department of Epidemiology and Biostatistics with Medical Informatics, Medical Faculty, UKIM, Skopje, Republic of Macedonia

MD, MBA Milenko Tanasijevic, Director, Clinical Laboratories Division and Clinical Program Development, Pathology Department, Brigham and Women's Hospital, Dana Farber Cancer Institute, Associate Professor of Pathology, Harvard Medical School, United States

PhD Mirko Trajkovski, ETH Zürich, Wolfgang-Pauli-Str. 16/HPT D57, 8093 Zürich-CH, Switzerland

MD, FRCPC Kiril Trpkov, Associate Professor, University of Calgary, Department of Pathology and Laboratory Medicine, Calgary Laboratory Services. 7007 14 st, Calgary SW, Canada

MD, PhD Igor Tulevski, Department of Cardiology, Academic Medical Center, Amsterdam, 1100 DD, T 020 707 2930; F 020 707 2931, Netherlands

PhD Zoran Zdravkovski, Institute of Chemistry, Faculty of Natural Sciences and Mathematics, Ss Cyril and Methodius University of Skopje, Skopje, Republic of Macedonia

Editorial Office

ID Design 2012/DOOEL Skopje, Rajko Zhinzifov No. 48, 1000 Skopje, Republic of Macedonia | Telephone: +389 70 255155. | e-mail: mspiroski@id-design.eu | URL: <http://www.id-design.eu/mjms/>

Publisher

ID Design Press, Rajko Zhinzifov No. 48, 1000 Skopje, Republic of Macedonia

CASE REPORT

Single - Door Cervical Laminoplasty Using Basket Laminoplasty Device: A Case Report

Tjokorda Gde Bagus Mahadewa, Dewa PW Wardhana, Sri Maliawan, Junichi Mizuno, I Putu Eka Widyadharma

603-605



PDF



ONLINEFIRST

Giant Bowen's Disease on the Face: Case Report and Review of the Literature

Nina Caca-Biljanovska, Irina Arsovska-Bezhoska, Marija V'lickova-Laskoska

606-609



PDF



ONLINEFIRST

Chronic Osteomyelitis after Seven Years Neglected Bone Exposed in 12-Year-Old Boy: A Case Report

- Handayani, Faldi Yaputra, Berkat Hia, Victor Telaumbanua, I Putu Eka Widyadharma

610-613



PDF



ONLINEFIRST

BRIEF COMMUNICATION

Weight Gain in Pregnancy and Weight Retention after Birth

Ivka Djaković, Hrvojka Soljačić-Vraneš, Krunoslav Kuna

614-616



PDF



ONLINEFIRST

DENTAL SCIENCE



Open Access Macedonian Journal of Medical Sciences

Country[Macedonia](#) -  [SJR Ranking of Macedonia](#)**Subject Area and Category**[Medicine](#)
[Medicine \(miscellaneous\)](#)**Publisher**[ID Design Press](#)**Publication type**[Journals](#)**ISSN**

18579655

Coverage

2014-ongoing

[Join the conversation about this journal](#)

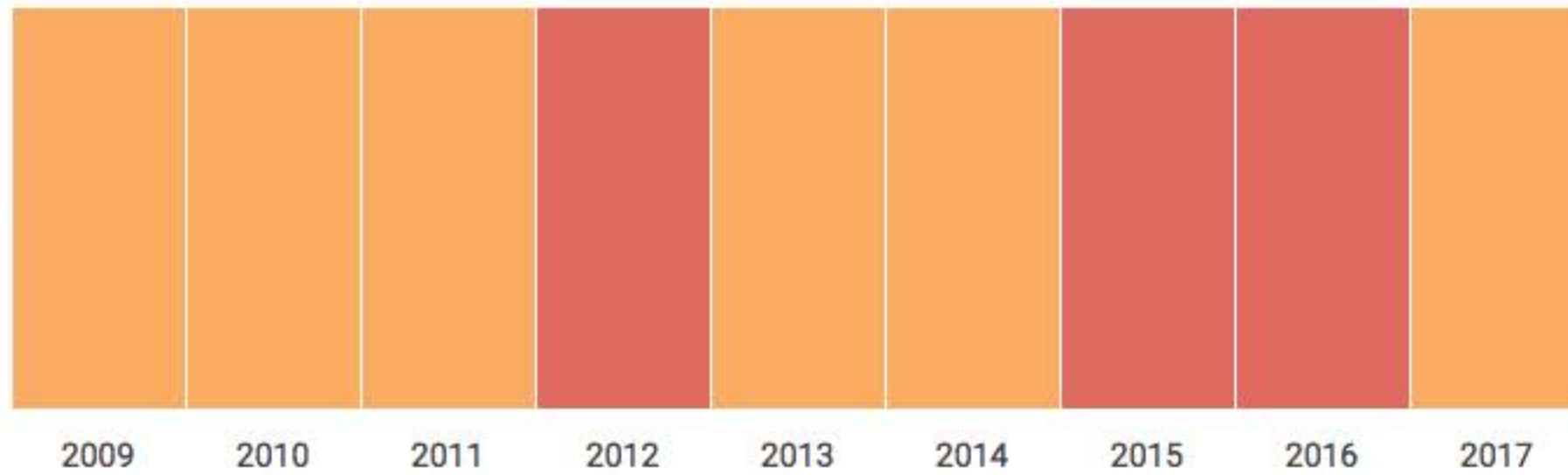
8

H Index

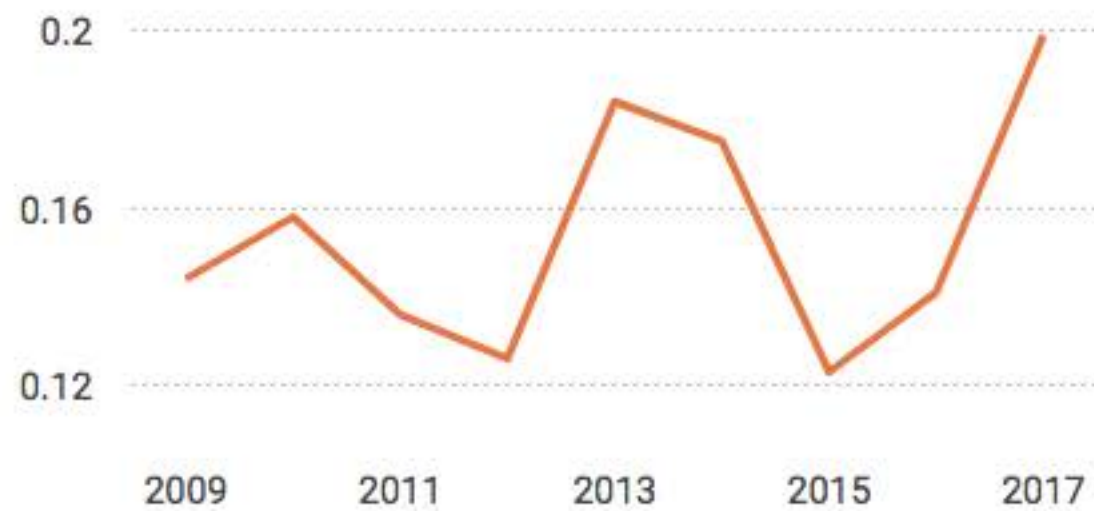Quartiles



Medicine (miscellaneous)



● SJR

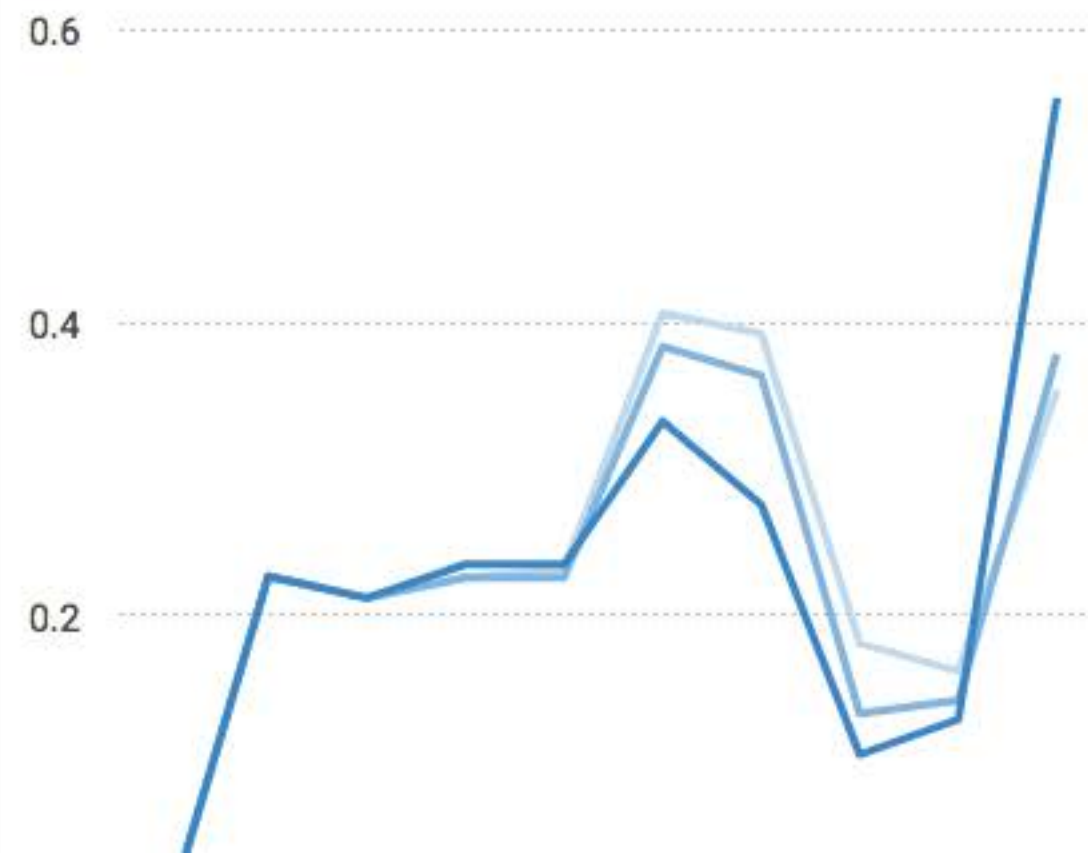

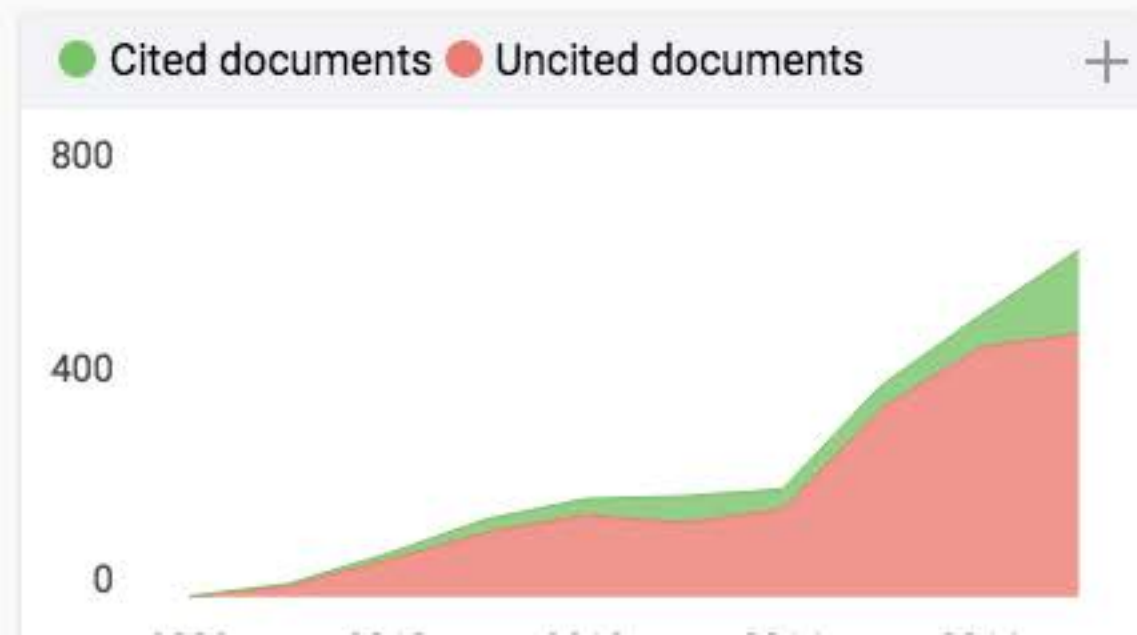
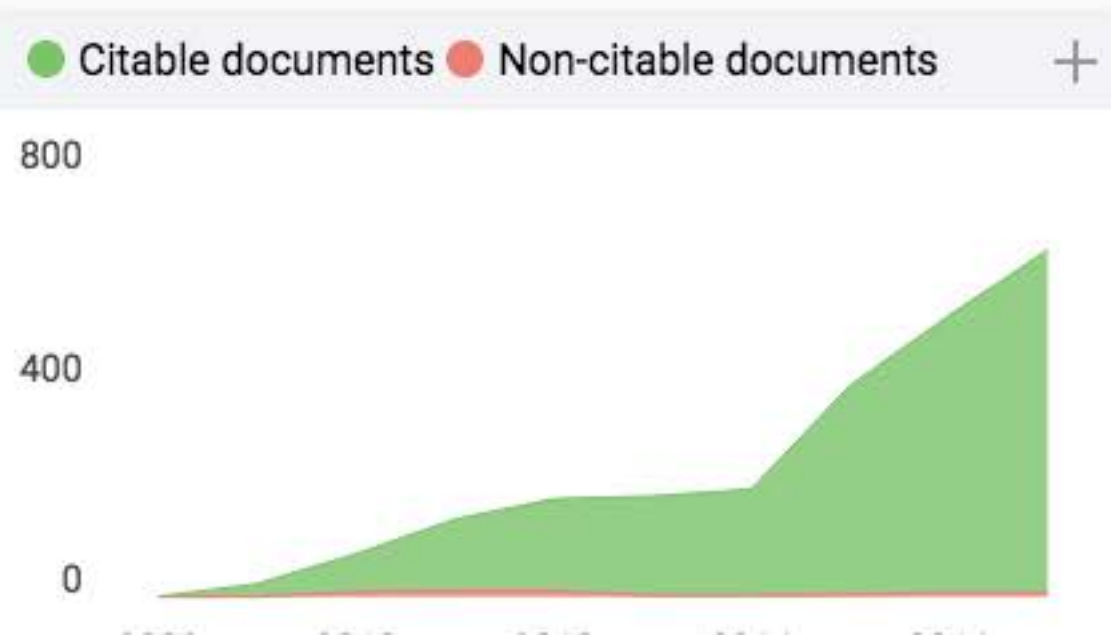
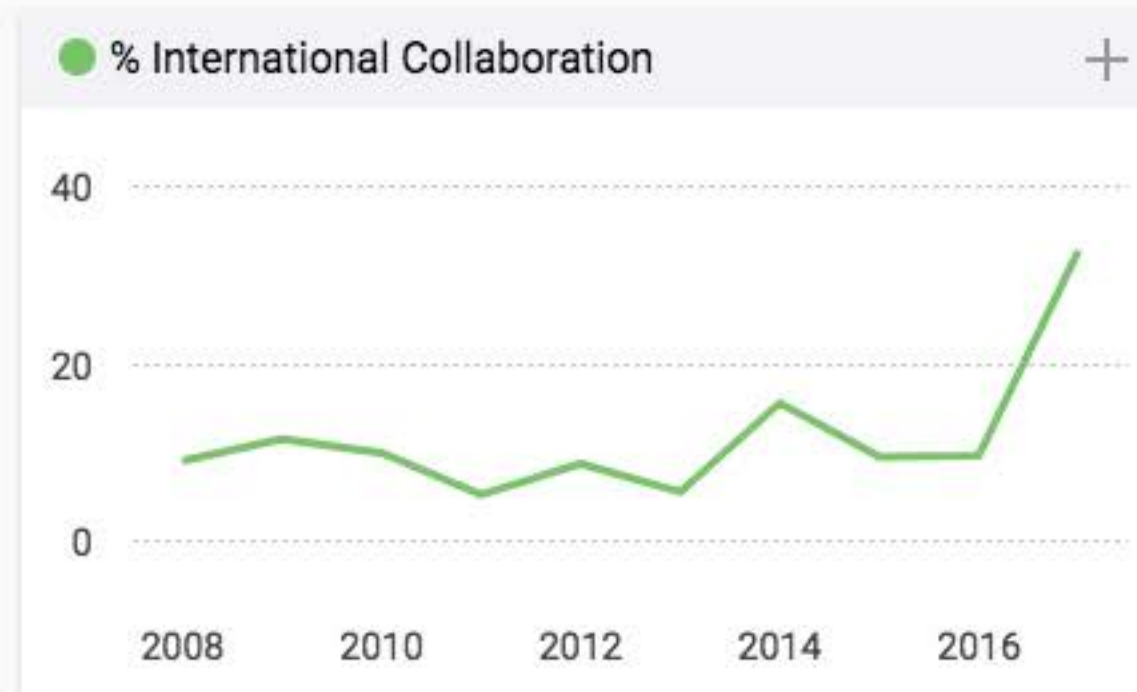
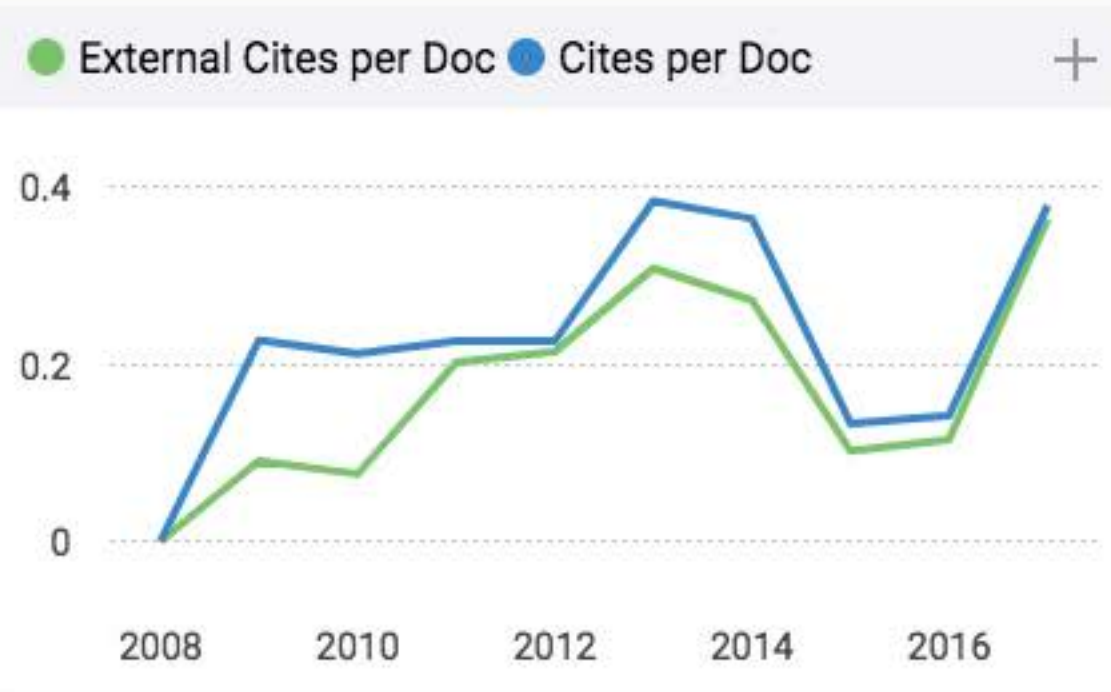
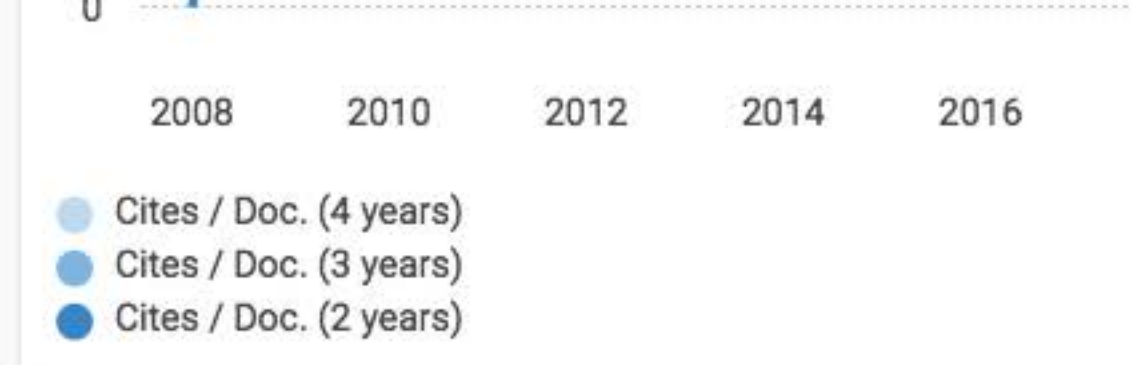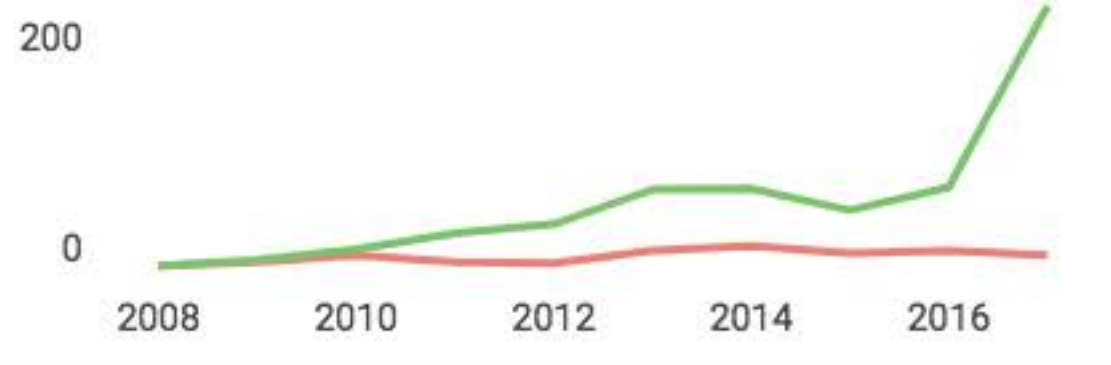
● Total Cites ● Self-Cites

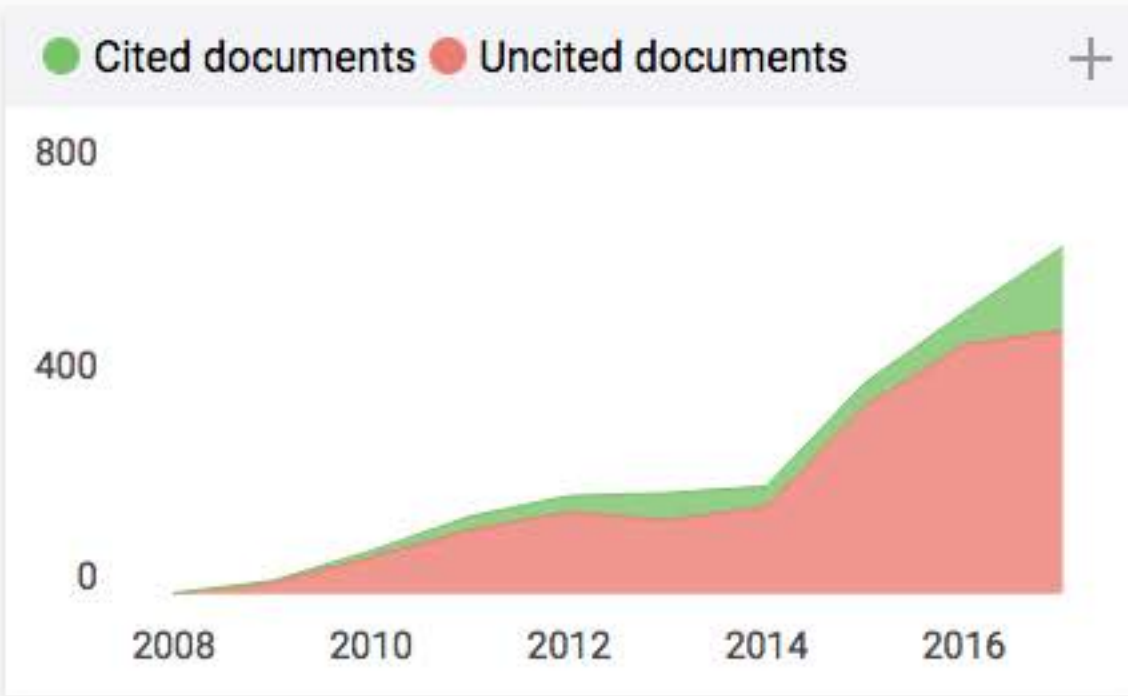
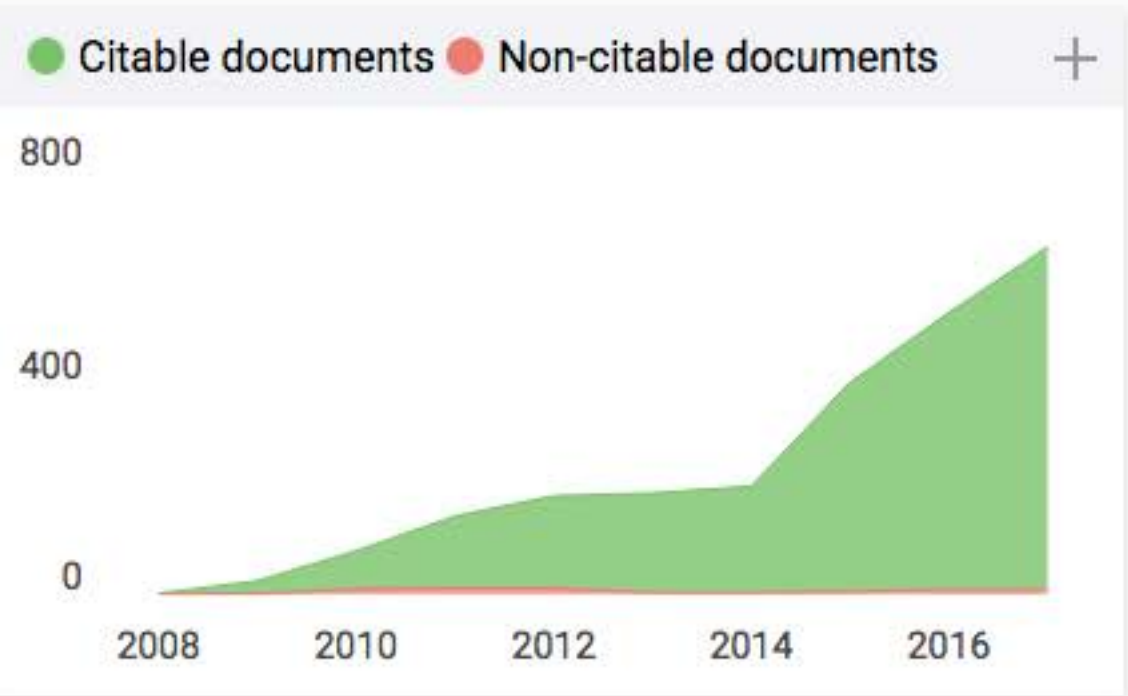
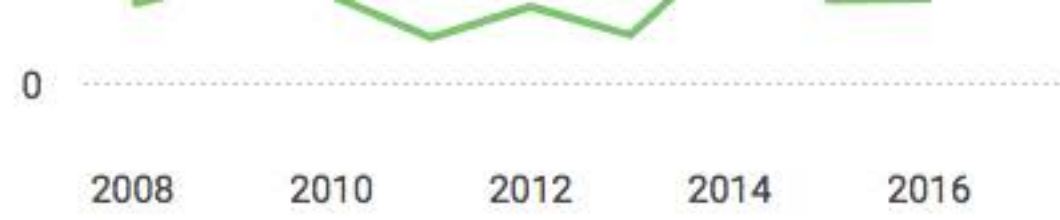

400

Citations per document







Open Access Macedonian Journal of Medical Sciences

Q3

Medicine (miscellaneous)

best quartile

SJR 2017

0.2

powered by scimagojr.com

← Show this widget in your own website

Just copy the code below and paste within your html code:

```
<a href="https://www.scimagojr.c
```

Chronic Osteomyelitis after Seven Years Neglected Bone Exposed in 12-Year-Old Boy: A Case Report

Handayani^{1*}, Faldi Yaputra², Berkat Hia³, Victor Telaumbanua⁴, I Putu Eka Widyadharma²

¹Department of Pediatrics, Gunungsitoli General Hospital, Nias, North Sumatera, Indonesia; ²Department of Neurology, Faculty of Medicine, Udayana University, Sanglah General Hospital, Bali, Indonesia; ³Department of Neurology, Gunungsitoli General Hospital, Nias, North Sumatera, Indonesia; ⁴Department of Surgery, Gunungsitoli General Hospital, Nias, North Sumatera, Indonesia

Abstract

Citation: Handayani, Yaputra F, Hia B, Telaumbanua V, Widyadharma IPE. Chronic Osteomyelitis after Seven Years Neglected Bone Exposed in 12-Year-Old Boy: A Case Report. Open Access Maced J Med Sci. 2019 Feb 28; 7(4):610-613.
<https://doi.org/10.3889/oamjms.2019.100>

Keywords: Bone Exposed; Chronic Post Traumatic Osteomyelitis; Neglected; Radial Nerve Injury

***Correspondence:** Handayani, Department of Pediatrics, Gunungsitoli General Hospital, Nias, North Sumatera, Indonesia. E-mail: handa566725@gmail.com

Received: 15-Nov-2018; **Revised:** 08-Jan-2019; **Accepted:** 09-Jan-2019; **Online first:** 25-Feb-2019

Copyright: © 2019 Handayani, Faldi Yaputra, Berkat Hia, Victor Telaumbanua, I Putu Eka Widyadharma. This is an open-access article distributed under the terms of the Creative Commons Attribution-NonCommercial 4.0 International License (CC BY-NC 4.0)

Funding: This research did not receive any financial support

Competing Interests: The authors have declared that no competing interests exist

BACKGROUND: Access to modern medicine is still limited in some rural areas in Indonesia. This is mostly due to lack of people's knowledge and concern for their health, especially in orthopaedic cases. Osteomyelitis is generally described as infection and inflammation of the bone, which results in local bone destruction, necrosis, and apposition of new bone. Chronic post-traumatic osteomyelitis (CPTO) is a complex condition and one of the most challenging problems in orthopaedic surgery that cause considerable morbidity.

CASE PRESENTATION: We present a case of chronic post-traumatic osteomyelitis with radial nerve injury, in which radical surgical debridement and broad-spectrum antibiotic administration were done. A 12-year-old boy with a history of falling from the three-meter-high tree had swollen, deformed, and neglected humerus bone exposed. After stabilisation in the emergency room, surgical limb amputation was scheduled, yet the family refused this medical care and chose debridement instead.

CONCLUSION: This case is an important addition to the literature about chronic post-traumatic osteomyelitis with neglected bone exposed and the lacking of society's concern in regards to orthopaedic cases.

Introduction

Although government health programs, known as BPJS (*Badan Penyelenggara Jaminan Sosial*), has given access to health care, by the subsidised hospital cost and has become a way out for a poor urban's financial problem, the number of neglected fractures has not dwindled in recent years. Thus, fractures are often first treated by traditional bone-setters and healers whose method is not adapted to the management of open fractures. Most patients come to the hospital after a certain delay presenting with severe injuries or sequela that are difficult to cure with the diagnostic and therapeutic means available in traditional local facilities.

Chronic osteomyelitis occurs either after sequelae of acute osteomyelitis in children or secondary osteomyelitis due to trauma involving open fracture. The last entity defines our case which is

post-traumatic osteomyelitis [1], [2], [3]. There are two most well-known classification systems for osteomyelitis, the Cierny-Mader, and the Waldvogel. Recently, new classification systems have been introduced and designed to be more specific to modern diagnostic and management approaches of osteomyelitis [3], [4]. Those important variables used in the new systems are bone involvement, antimicrobial resistance patterns of causative micro-organisms, the need for soft tissue coverage, and host status [4], [5]. Tenderness, effusion, increased warmth, pain with motion, and drainage on the area of the affected bone are signs and symptoms of chronic osteomyelitis [6].

Trauma is one of the risk factor for osteomyelitis [7]. Open fractures are at high risk of transcutaneous contamination of bacteria [8]. The pathophysiology of traumatic osteomyelitis depends on bones involved, initial injury's characteristic, and host condition [9]. Radial nerve injury (particularly radial neuropraxia) as the main presentation of

fracture middle third humerus (diaphyseal fracture), is one of the most aetiology for peripheral nerve palsy associated with humerus bone fracture. The incidence ranges from 1,8% to 22% [10], [11], [12], [13].

Lesions, caused by traumatic injury, can occur anywhere along the radial nerve. Therefore, the anatomy of it is clinically significant. The structures along its course also play an important role in determining the sites at which lesion might occur and in localising the origins of pathological lesions during diagnostic examinations [13], [14], [15], [16]. They are classified as lesions in the axilla (very high lesions), lesions in the arm in the radial groove (high lesions), lesions at the elbow, and lesions of the superficial branch of the radial nerve (low lesions). In our case, it is the high lesions type. The deficit of high lesions type presents brachioradialis weakness, wrist drop, finger drop, thumb drop, and sensory loss [16]. Diagnosis of osteomyelitis can be confirmed by bone scan or MR scan, along with needle aspiration, bone biopsy, elevated erythrocyte sedimentation rate (ESR), elevated C-reactive protein (CRP), elevated WBC count, and culture [6], [7]. Treatment of osteomyelitis is multiple surgical procedures, including surgical debridement of all necrotic bones, soft tissue coverage, the combination of appropriate antibiotics, and long-term follow-up, which are all still a problematic clinical challenge for osteomyelitis [1], [2], [3], [4], [8].

Identification of the pathogen in the bone, through a bone biopsy, is a definitive diagnosis of osteomyelitis. In the selection of antibiotic administration, most studies reported *Staphylococcus aureus* is the aetiology and responsible for 80% to 90% of its cases [7], [8]. Eighty-five to ninety percent of radial nerve lesion can recover spontaneously within three months. Thus, if nerve function doesn't return within three to four months, nerve surgical exploration should be performed [10], [11], [13], [15], [17]. The prognosis of radial nerve injury is influenced by the severity of humeral shaft fracture according to AO/OTA Classification [12].

Hereby we present a case report of a 12-year-old boy with chronic post-traumatic osteomyelitis (CPTO) after seven years of neglected bone exposed. He was successfully treated with radical surgical debridement, broad-spectrum antibiotics, analgesics, neuroprotective agents, and physiotherapy.

Case Report

A 12-year-old boy presented to the emergency department with a chief complaint of bone exposed and bleeding of the upper left arm every time he got minor trauma. It was caused by a past traumatic injury resulting from the impact of falling

from a three-meter-high tree which happened seven years ago. He fell forward with left arm outstretched, struck the ground with shoulder flexed, elbow flexed, forearm pronated, wrist dorsiflexed, resulting in the bone of the upper left arm exposed. His mother admitted due to the fear of having surgery, the exposed bone was never consulted to medical care and was only treated by traditional medicine for seven years.

On clinical examination, of which consists of look, feel, move, the upper left arm was swollen with shortening deformity, contraction, angulation, exposed humerus bone with the size approximately 2,5 cm in diameter, and full thickness tissue loss, which was covered by dry, black eschar on the base of the ulcer on anterior and posterior aspect of the upper left arm. The eschar extended from the middle shaft into the proximal of the upper left arm. There is no slough and yellow-coloured pus seen on the wound base. Bleeding, tenderness and crepitus were presented on the middle shaft upper left arm (Figure 1). Sensation on first dorsal web space of his left hand was weakened. Extension of the left wrist and left fingers including the thumb was also impossible (wrist drop, finger drop, and thumb drop). Yet, radial artery pulsation was still poorly palpated. The left elbow's range of movement (ROM) including flexion and extension was moderately restricted because of deformity and pain. While the ROM of left wrist, particularly on extension movement, was severely restricted.

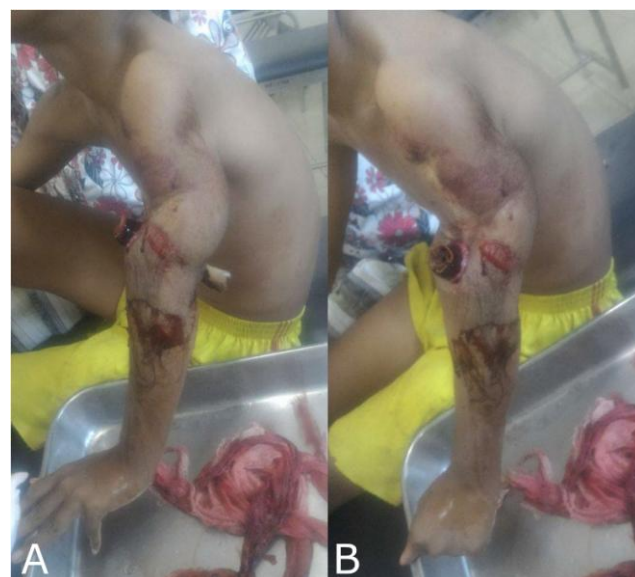

Figure 1: Open fracture of the middle one-third neglected upper left arm in a 12-year-old boy; a) lateral aspect; b) anterior aspect

Blood investigations showed severe anaemia (Hb: 7.3 mg/dL) and leukocytosis (20.200/ μ L). ESR and CRP values weren't investigated due to lack of facilities. Anteroposterior and lateral radiographs of the upper left arm showed both open, complete, transverse fracture on proximal one-third to middle humerus bone with osteomyelitis and a gap between

proximal and distal humerus. There was the irregular contour of the glenoid on the shoulder joint (Figure 2). The patient was managed and stabilised with the administration of normal intravenous saline, one unit of packed red cells (PRC), broad-spectrum antibiotics, analgesics, neuroprotective agents, and surgical debridement, as his family refused to be amputated. He then was followed up for seven days after debridement had been performed.

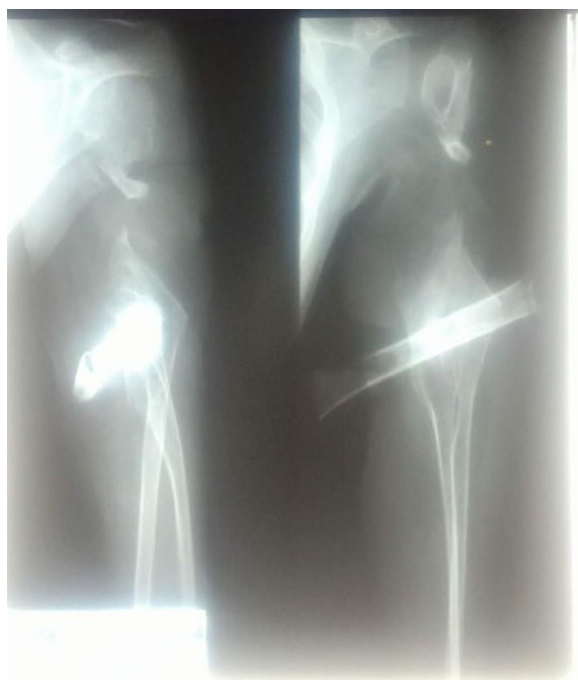

Figure 2: Anteroposterior and lateral X-ray films of the upper left arm. They showed a complete, transverse fragment fracture from proximal one-third to middle humerus bone which is displaced into antero-inferior with the lytic lesion and sclerotic on distal one-third humerus bone

Discussion

The incidence of post-traumatic osteomyelitis is rising recently because of the increased frequency of trauma, whereas the incidence of chronic and neglected cases has not dwindled due to lacking knowledge and concern of our society in regards to orthopaedic cases [10]. Physical examinations of osteomyelitis found on the patient were quite similar to the literature, such as tenderness, effusion, increased warmth, pain with motion, and drainage of the affected area [6].

Based on several classifications, our patient is type IIIB of Gustilo & Anderson's open fracture classification, contiguous type of Waldvogel's osteomyelitis classification, type IV class B host classification with unstable, segmental diaphyseal type of diffuse osteomyelitis defect on Cierny-Mader's osteomyelitis classification, and high lesions type of radial nerve injury's classification [1], [4], [18].

The patient has been diagnosed osteomyelitis based on history taking, physical examination, and has been confirmed by the elevated WBC count on laboratory findings and the appearance of the sclerotic and lytic lesion on proximal one-third humerus in x-ray [5].

His Mangled Extremity Severity Score (MESS) for limb salvage is more than seven, referring to score 4 for the massive energy of injury, score 2 for tready pulses, score 2 for a prolonged shock. His fracture meets the Apley's criteria for amputation, such as dangerous and damned nuisance criteria. We, therefore, suggest amputation to be performed, but his family refused it [3], [5], [8], [19], [20]. Consequently, we performed radical debridement and excision of all avascular scarred and infected granulation tissue, followed by debridement of the infected endosteum, reaming, and the insertion of closed suction drainage system [3], [20], [21].

Determining the appropriate antibiotics has been an issue due to the paucity of instruments (specimen culture). Therefore, we use a broad-spectrum antibiotic to prevent the increase of bacterial resistance cases [5]. Besides, early exploration of the radial nerve is not performed as well due to the lack of instruments and resources.

Although the infection control and satisfactory functional outcome of our patient can finally be achieved, this case proves knowledge and concern of our society in regards to orthopaedic cases is ironically superficial. Most of them are still taboo and afraid to have surgery, particularly amputation. Once the patient's fracture meets the MESS and Apley's criteria, amputation is essential to give the good prognosis to the patient.

In conclusion, this case is an important addition to the literature about chronic post-traumatic osteomyelitis with neglected bone exposed and the lacking of society's concern in regards to orthopaedic cases.

References

1. Haidar R, Der Boghossian A, Atiyeh B. Duration of post-surgical antibiotics in chronic osteomyelitis: empiric or evidence-based? *International Journal of Infectious Diseases*. 2010; 14(9):e752-8. <https://doi.org/10.1016/j.ijid.2010.01.005>
2. Handy ED, Manfo AA, Gonsu KH, Essi MJ, Ngo Nonga B, Sosso MA. Clinical and microbiological profile of post-traumatic osteomyelitis in a tertiary hospital in Yaoundé-Cameroon. *International Journal of Orthopaedics*. 2017; 3(3):1180-4.
3. Prasad DDV, et al. Management of chronic osteomyelitis by wide debridement and closed suction: Drainage technique. *International Journal of Orthopaedics Sciences*. 2017; 3:163-168. <https://doi.org/10.22271/ortho.2017.v3.i2c.25>
4. Hotchen AJ, McNally MA, Sendi P. The classification of long bone osteomyelitis: a systemic review of the literature. *Journal of*

- bone and joint infection. 2017; 2(4):167.
<https://doi.org/10.7150/ijbji.21050> PMCID:PMC5671929
5. Lima AL, Oliveira PR, Carvalho VC, Cimerman S, Savio E. Recommendations for the treatment of osteomyelitis. Brazilian Journal of Infectious Diseases. 2014; 18(5):526-34.
<https://doi.org/10.1016/j.bjid.2013.12.005>
6. Scheri RP. Washington Manual of Surgery 20, 312.
7. van Schuppen J, van Doorn MM, Van Rijn RR. Childhood osteomyelitis: imaging characteristics. Insights into imaging. 2012; 3(5):519-33. <https://doi.org/10.1007/s13244-012-0186-8>
8. Birt MC, Anderson DW, Toby EB, Wang J. Osteomyelitis: Recent advances in pathophysiology and therapeutic strategies. Journal of orthopaedics. 2017; 14(1):45-52.
<https://doi.org/10.1016/j.jor.2016.10.004>
9. Ketonis C, Dwyer J, Ilyas AM. Timing of debridement and infection rates in open fractures of the hand: a systematic review. Hand. 2017; 12(2):119-26.
<https://doi.org/10.1177/1558944716643294> PMid:28344521
10. Pinheiro AC. Radial Nerve Palsy after Humeral Fracture: To Explore or Not to Explore?—A Case Report. Int J Phys Med Rehabil. 2016; 4(326):2. <https://doi.org/10.4172/2329-9096.1000326>
11. Schwab TR, Stillhard PF, Schibli S, Furrer M, Sommer C. Radial nerve palsy in humeral shaft fractures with internal fixation: analysis of management and outcome. European Journal of Trauma and Emergency Surgery. 2018; 44(2):235-43.
<https://doi.org/10.1007/s00068-017-0775-9> PMid:28280873
12. Hoa YY, Chen LW, Yang KC, Hsu KC, Liu WC, Lin CT. Prognostic factors for radial nerve palsy associated with humeral shaft fracture. Formosan Journal of Surgery. 2017; 50(1):1.
https://doi.org/10.4103/fjs.fjs_3_17
13. Bumbasirevic M, Palibrk T, Lesic A, Atkinson HD. Radial nerve palsy. EFORT Open Reviews. 2016; 1:286–294.
<https://doi.org/10.1302/2058-5241.1.000028> PMid:28461960
14. Han BR, Cho YJ, Yang JS, Kang SH, Choi HJ. Clinical features of wrist drop caused by compressive radial neuropathy and its anatomical considerations. Journal of Korean Neurosurgical Society. 2014; 55(3):148.
<https://doi.org/10.3340/jkns.2014.55.3.148>
15. Latef TJ, Bilal M, Vetter M, Iwanaga J, Oskouian RJ, Tubbs RS. Injury of the Radial Nerve in the Arm: A Review. Cureus. 2018; 10(2). <https://doi.org/10.7759/cureus.2199>
16. Wang LH, Weiss MD. Anatomical, clinical, and electrodiagnostic features of radial neuropathies. Physical Medicine and Rehabilitation Clinics. 2013; 24(1):33-47.
<https://doi.org/10.1016/j.pmr.2012.08.018>
17. Giordano V, Belangero W, Pires RE, Labronici PJ, the Clinical Decision Rules Group. Humerus shaft fracture associated with traumatic radial nerve palsy: An international survey among orthopedic trauma surgeons from Latin America and Asia/Pacific. Journal of Orthopaedic Surgery. 2017; 25:230949901772791.
<https://doi.org/10.1177/2309499017727914> PMid:28847240
18. Kim PH, Leopold SS. Gustilo-Anderson Classification. Clinical Orthopaedics and Related Research. 2012; 470(12):3624.
<https://doi.org/10.1007/s11999-012-2642-7>
19. RD. Correlations Between Degree of Limb Ischemia in MESS (Mangled Extremity Severity Score) Score in Predicting Amputation or Limb Salvage in Crush Injury at Hasan Sadikin Hospital, Bandung. Biomedical Journal of Scientific & Technical Research. 2017; 1.
20. Calhoun JH, Manring MM, Shirliff M. Osteomyelitis of the long bones. In: Seminars in plastic surgery 2009 (Vol. 23, No. 2, p. 59). Thieme Medical Publishers.
21. Ryan S, Eward W, Brigman B, Zura R. Chronic Osteomyelitis of the Distal Femur Treated with Resection and Delayed Endoprosthetic Reconstruction: A Report of Three Cases. Case Reports in Orthopedics. 2017; 1–6.
<https://doi.org/10.1155/2017/5141032> PMid:28894615