

# CASE REPORT OF RHIZOBIUM RADIOBACTER NEONATAL SEPSIS IN SANGLAH HOSPITAL

Samantha Celena Triadi <sup>\*,1</sup>, I Dewa Made Sukrama <sup>\*\*</sup> and Ni Made Adi Tarini <sup>\*\*</sup>

\* Clinical Microbiology Specialist Program, Faculty of Medicine and Health Sciences, Udayana University/Sanglah General Hospital Denpasar, Bali, Indonesia ,

\*\* Department of Clinical Microbiology, Faculty of Medicine and Health Sciences, Udayana University/Sanglah General Hospital Denpasar, Bali, Indonesia

**ABSTRACT** Neonatal sepsis is still a problem in the health sector, particularly in developing countries, and the incidence is quite high; therefore requires early detection and proper therapy. We report a rare manifestation of *Rhizobium radiobacter* infection in which sepsis occurred in a newborn infant. In patients with sepsis caused by *R. radiobacter* appropriate antibiotics are needed to prevent worsening. *R. radiobacter* is often a bacterial contaminant and rarely causes infection in humans, but in immunocompromised patients, this microorganism can be an agent in an infection. This study aims to improve understanding of sepsis caused by *R. radiobacter*. This study is a case report of a 27-day-old neonate with sepsis neonatal. From the result of the two-sided blood culture using VITEK 2 Compact on September 28, 2020, *R. radiobacter* was detected. Meropenem was administered intravenously from day 20 in hospital, but the patient's condition gradually deteriorated, and the patient died 28 days after birth. *R. radiobacter* was rarely reported as a pathogen. Immunocompromised patients, delayed detection and inadequate treatment can increase morbidity and mortality.

**KEYWORDS** *Rhizobium radiobacter*, blood culture, sepsis

## Introduction

Infection is the major cause of neonatal deaths in developing countries. This infection can be acquired through exposure to microbes that colonize the maternal genital tract (vertical transmission) or through exposure during treatment in a health care setting[1]. *R. radiobacter* is a member of the genus *Agrobacterium*, formerly known as *Agrobacterium radiobacter*. This bacterium is gram-negative motile rods, non-spore-forming, aerobic, oxidase-positive, saprophytic, and plant pathogens[2]. *Rhizobium radiobacter* infection in neonates leading to neonatal sepsis. Neonatal sepsis is a clinical syndrome of bacteremia characterized by systemic symptoms and signs, especially in the first month of life. This condition is one of the most common causes of death in neonates. One factor is the inappropriate administration of antibiotics which causes an increase in antibiotic resistance. First-

line antibiotic resistance will lead to the administration of newer and more expensive antibiotics. Therefore, the importance of microbiological examination and monitoring of bacterial patterns can improve the management of neonatal sepsis[3]. The incidence of neonatal sepsis in Sanglah Hospital is 5%, with a mortality rate of 30.4%. In contrast, at Cipto Mangunkusumo Hospital, Jakarta, the incidence of neonatal sepsis is still high at 13.7%, with a mortality rate of 14%. Low birth weight and prematurity are associated with mortality in neonatal sepsis. The difficulty in evaluating and optimal treatment of bacterial infection in neonates is caused by the clinical signs of neonatal sepsis, which are often variable and non-specific. Infections caused by *R. radiobacter* are very rare often occur if the patient is immunocompromised and associated with intravascular devices in immunocompetent patients.

## Case Report

A 41-year-old pregnant woman with Congestive Heart Failure and a suspect of Peripartum cardiomyopathy presented in the emergency department delivered a preterm male infant. The clinical examination of the infant showed admission weight 2200 g, the patient was somnolence (GCS 6, E2V2M2), respiratory rate 60/min, heart rate 170/min, capillary refill time 4 s,

Copyright © 2022 by the Bulgarian Association of Young Surgeons  
 DOI: 10.5455/IJMRCR.CASEREPORTOFRHIZOBIUMRADIOBACTERNEONATAL  
 First Received: November 15, 2021  
 Accepted: January 25, 2022  
 Associate Editor: Ivan Inkov (BG);  
<sup>1</sup>Corresponding author: Samantha Celena Triadi; samanthacelena@gmail.com

audible grunting with subcostal and intercostal retraction, nasal flaring, mottling, abdominal distention, normal heart sounds and the infant was born with Apgar scores of 1 at one minute and 2 at five minutes. On chest examination, ronchi were heard. On examination, the eyes, ears, nose and throat, lymph nodes, heart, abdomen, and extremities were within normal limits. On examination, bowel sounds were normal, and there was no enlargement of the liver, spleen, and distention. The diagnosis of this baby was severe asphyxia and suspected sepsis. The infant was started on nasal bubble CPAP (Continuous positive airway pressure) for respiratory system support and was evaluated with a chest radiograph and sepsis screen. The chest X-ray showed homogenous opacity in the right lower and right middle lobe suggesting pneumonia. Because there was a problem in this patient hemodynamic, the infant was started on vasopressors. The sepsis screen revealed an absolute neutrophil count of  $1043/\mu\text{L}$  (neutropenia), platelet count of  $126.000/\mu\text{L}$  (thrombocytopenia), immature neutrophil/total neutrophil (I/T) ratio of 0.299. Blood gas analysis showed acidosis with a pH of 7.30,  $\text{Pco}_2$  25.9 mmHg. The blood culture showed the growth of colonies with a clear appearance, uneven edges, bumpy surfaces and mucoid appearance. The examination continued with identification using the VITEK2 machine (Biomerieux, France), where *R.radiobacter* was identified with the antibiotic sensitivity test showing sensitivity to Levofloxacin only. The patient has been given Ampicillin 110 mg every 12 hours and Amikacin 17 mg every 8 hours, followed by Meropenem. The patient showed no clinical improvement, and at the age of 28 days, the patient died.

## Discussion

*R.radiobacter* is a pathogen that causes tumorigenic disease in plants. This bacterium is often considered non-pathogenic, but it has been found to cause infections in a patient with the immunocompromised condition and chronic diseases in the last decade. One of the factors causing the patient to become infected with this bacterium is the use of invasive devices, especially peritoneal dialysis catheters or central venous catheters. Infection caused by *R.radiobacter* in children has not been reported frequently. Infection is common in pediatric patients who use medical devices such as central venous catheters. The common pathogens that cause infection in central venous catheters are *staphylococci*, Gram-negative bacilli and fungi. Reports of central venous catheter infection caused by *R.radiobacter* are rarely reported. However, several studies show this organism can cause other infections, including endocarditis, urinary tract infections and peritonitis. One of the important factors that increase the risk for *R.radiobacter* infection is the installation of medical devices. *R. radiobacter* is a Gram-negative bacillus that grows aerobically on Blood Agar and MacConkey agar media. These bacteria are motile because they have peritrichous flagella. These bacteria are catalase-positive, oxidase negative and urease-positive. In media containing higher concentrations of carbohydrates, the production of extracellular polysaccharide mucus usually appears. These bacteria have microbiological features similar to *Pseudomonas*, *Alcaligenes* and *Bordetella* but can easily be distinguished by biochemical tests and morphological examination of flagella. Identification of these bacteria can be made by testing the production of 3-ketolactose. If the 3-ketolactose production test cannot be carried out, an alternative test that can be used is the carbohydrate, mannitol, lactose and maltose oxidation test. Based on the phylogenetic effect, bacteria are classified into three species: *Agrobacterium tumefaciens*,

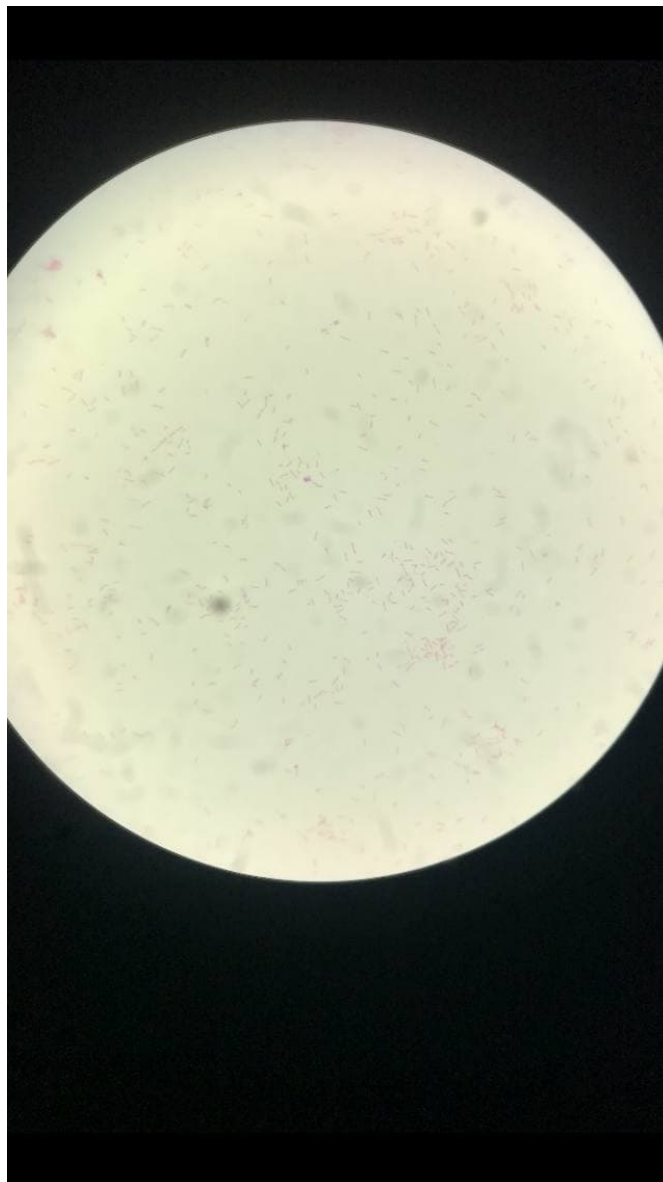


Figure 1:

*Agrobacterium rhizogenes* and *Agrobacterium rubi*. *R. radiobacter* has the character of lacking tumorigenic Ti plasmids, while *A. tumefaciens* is a pathogen that often causes infections in humans. The species name, "radiobacter," is of Greek origin, meaning "ray" because this group of bacteria forms a star. The mechanism of transmission of *R. radiobacter* in humans has not been elucidated. The earliest reports of infection caused by *R. radiobacter* in 1967 considered that this organism was often a contaminant and had weak pathogenic properties[5]. In a study by Plotkin, the first case of *R. radiobacter* infection in humans was endocarditis in a patient following a prosthetic aortic valve in 1980[6]. In adult and pediatric patients, this bacterium is associated with infections associated with the insertion of invasive devices such as CVC. In one study, it was found that more than half of *R. radiobacter* infections were catheter-associated bacteremia[7]. Infection is common in pediatric patients who use medical devices such as central venous catheters. The pathogens that cause infection in central venous catheters are *staphylococci*, Gram-negative bacilli, and fungi. Reports of central venous catheter infection

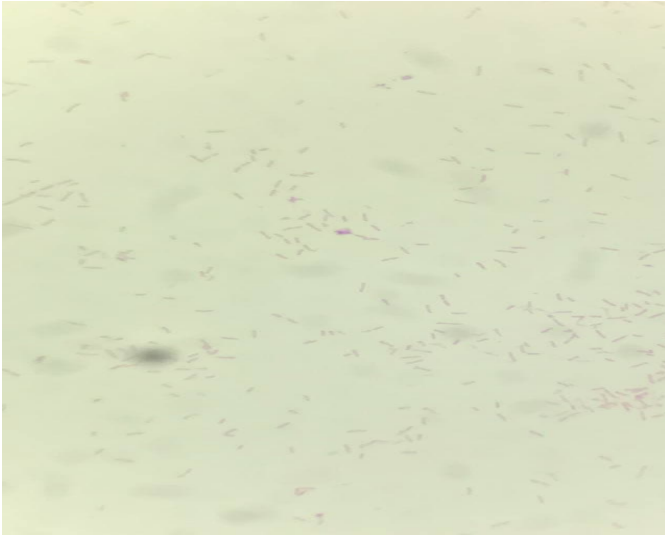


Figure 2:

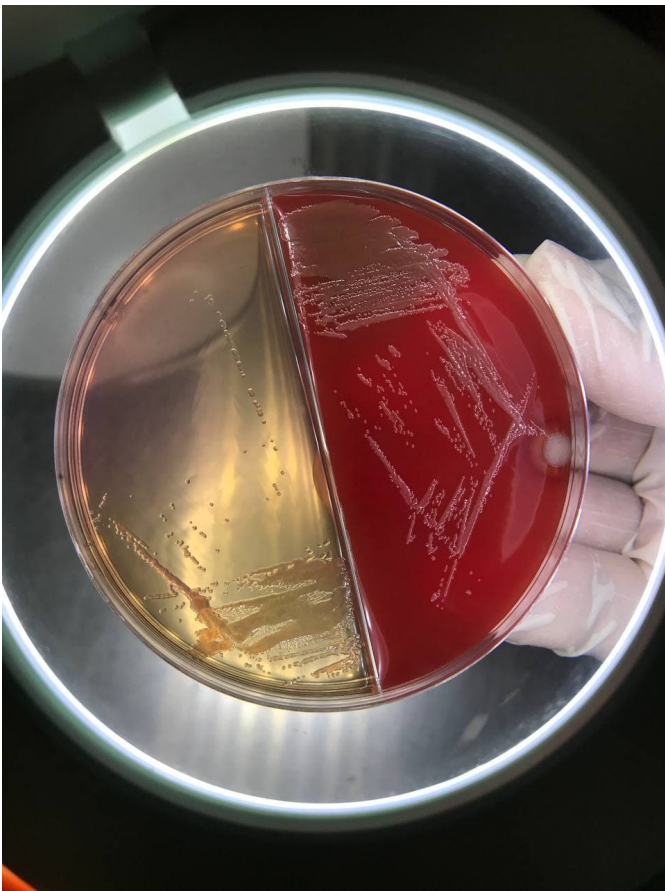


Figure 3:

caused by *R. radiobacter* are rarely reported. These bacteria have low virulence. If these bacteria are identified in the patient, removing or replacing the medical device is an important part of the patient's therapy. This bacteria are sensitive to gentamicin, ceftazidime, amikacin, carbapenems, piperacillin tazobactam, cefepime and polymyxin. There is some prevention for this infection such as removing or replacing medical devices, the appropriate antibiotic is given according to the results of the

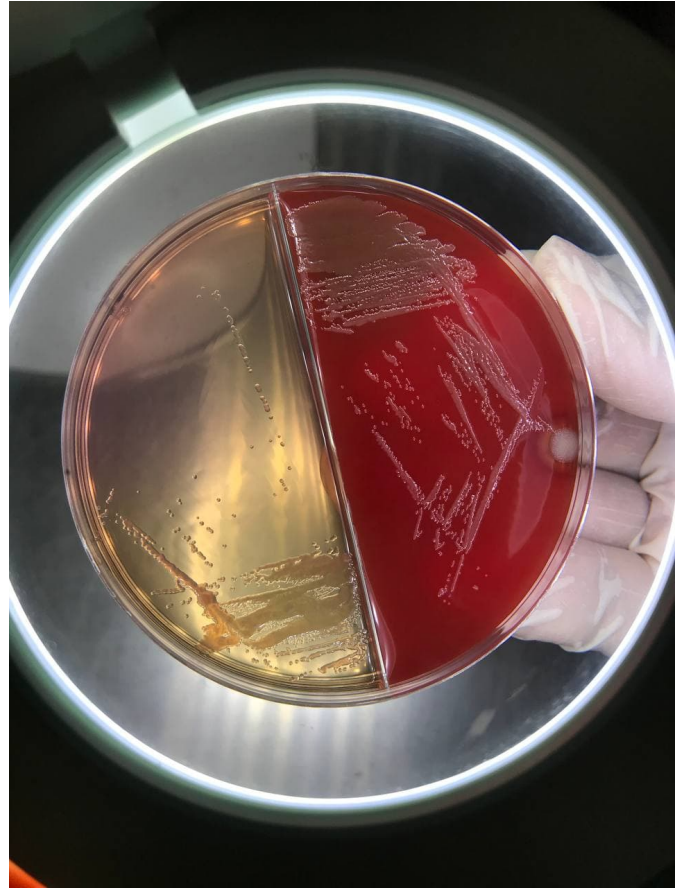


Figure 4:

sensitivity test, minimizing the use of medical devices made of plastic, use of cuff and tunneled CVC or CVC with impregnated chlorhexidine and silver sulfadiazine in patients, giving impregnated antimicrobial to CVC with non-cuff and non tunneled type, considering the patient's condition so that the frequency of CVC installation can be minimized, advise outpatient CVC patients to avoid activities that are directly related to the soil, such as gardening or repairing the house. In summary, we report a case of invasive *R. radiobacter* infection in a newborn infant with a history of central venous access. This case highlights a rare manifestation of *R. radiobacter* infection.

### Conclusion

A male baby was born with severe asphyxia in the emergency department. The patient was treated by CPAP for respiratory support and got evaluated with a chest radiograph, blood culture and sepsis screen. The chest X-ray showed homogenous opacity in the right lower and right middle lobe suggesting pneumonia. The blood culture showed the growth of colonies with a clear appearance, uneven edges, bumpy surfaces and mucoid appearance. The examination continued with the VITEK2 machine (Biomérieux, France), where *R. radiobacter* was identified with the antibiotic sensitivity test showing sensitivity to Levofloxacin only. The infant was started on Ampicillin 110 mg every 12 hours and Amikacin 17 mg every 8 hours, followed by Meropenem. The patient showed no clinical improvement, and at the age of 28 days, the patient died.

## List of abbreviation

<b>I/T ratio</b>	: immature neutrophil/total neutrophil
<b>GCS</b>	: Glasgow Coma Scale
<b>CVC</b>	: Central Venous Catether
<b>CPAP</b>	: Continuous positive airway pressure

## Acknowledgement

We want to thank Ida Sri Iswari (clinical Microbiology medical Doctor, head of Clinical Microbiology Laboratory Department Sanglah General Hospital), Ni Nyoman Sri Budayanti, Clinical Microbiologists and technicians of Clinical Microbiology Installation at Sanglah Hospital, for their support.

## Funding

This work did not receive any grant from funding agencies in the public, commercial, or not-for-profit sectors.

## Conflict Of Interest

There are no conflicts of interest to declare by any of the authors of this study.

## References

1. Wilar, R., Kumalasari, E., Suryanto, D. Y., & Gunawan, S. (2016). Risk factors for early-onset sepsis. *Pediatrics sari*, 12(4), 265-9.
2. Rhizobium radiobacter: A Recently Recognized Cause of Bacterial Keratitis. Nigel H. Barker. *Cornea Journal*. Volume 35, Number 5, May, 2016.
3. Roger G. Finch, David Greenwood, S. Ragnar Norrby, Richard J. Whitley. *Antibiotic and Chemotherapy*. Ninth edition. Elsevier Limited.2010
4. Lai, C. C., Teng, L. J., Hsueh, P. R., Yuan, A., Tsai, K. C., Tang, J. L., & Tien, H. F. (2004). Clinical and Microbiological Characteristics of Rhizobium radiobacter Infections. *Clinical Infectious Diseases*, 38(1), 149–153. <https://doi.org/10.1086/380463>
5. Zaidi, A. K. M., Huskins, W. C., Thaver, D., Bhutta, Z. A., Abbas, Z., & Goldmann, D. A. (2005). Hospital-acquired neonatal infections in developing countries. *Lancet*, 365(9465), 1175–1188. [https://doi.org/10.1016/S0140-6736\(05\)71881-X](https://doi.org/10.1016/S0140-6736(05)71881-X)
6. Nazir, A. (2019). Multidrug-resistant Acinetobacter septicemia in neonates: A study from a teaching hospital of Northern India. *Journal of laboratory physicians*, 11(1), 23.
7. Abarca-Grau, A. M., Burbank, L. P., De Paz, H. D., Crespo-Rivas, J. C., Marco-Noales, E., López, M. M., ... & Penyalver, R. (2012). Role for Rhizobium rhizogenes K84 cell envelope polysaccharides in surface interactions. *Applied and environmental microbiology*, 78(6), 1644-1651.
8. Sawhney, S., Naab, T., & Oneal, P. (2016). Rhizobium radiobacter infection in a 27-year-old african American woman with munchausen syndrome. *Laboratory medicine*, 47(3), e32-e34.
9. Juniatiningsih, A., Aminullah, A., & Firmansyah, A. (2016). Profile of microorganisms causing neonatal sepsis in the Department of Pediatrics, Cipto Mangunkusumo Hospital, Jakarta. *Sari pediatrics*, 10(1), 60-5.
10. Kaselitz, T. B., Hariadi, N. I., LiPuma, J. J., & Weinberg, J. B. (2012). Rhizobium radiobacter bacteremia in a neonate. *Infection*, 40(4), 437-439.
11. Barker, N. H., Thompson, J. M., Mullen, M. G., Weekes, M. A., Nguyen, L. N., Haynes, C. K., & Miller, D. (2016). Rhizobium radiobacter: a recently recognized cause of bacterial keratitis. *Cornea*, 35(5), 679-682.
12. Ponnappula, S., Swanson, J. M., Wood, G. C., Boucher, B. A., Wells, D. L., Croce, M. A., & Fabian, T. C. (2013). Treatment of Rhizobium radiobacter bacteremia in a critically ill trauma patient. *Annals of Pharmacotherapy*, 47(11), 1584-1587.
13. Hamer, D. H., Darmstadt, G. L., Carlin, J. B., Zaidi, A. K., Yeboah-Antwi, K., Saha, S. K., ... & Weber, M. W. (2015). Etiology of bacteremia in young infants in six countries. *The Pediatric infectious disease journal*, 34(1), e1.
14. Sorsa, A. (2019). Epidemiology of neonatal sepsis and associated factors implicated: observational study at neonatal intensive care unit of Arsi University Teaching and Referral Hospital, South East Ethiopia. *Ethiopian journal of health sciences*, 29(3).
15. Pereira, L. A., Chan, D. S. G., Ng, T. M., Lin, R., Jureen, R., Fisher, D. A., & Tambyah, P. A. (2009). Pseudo-outbreak of Rhizobium radiobacter infection resulting from laboratory contamination of saline solution. *Journal of clinical microbiology*, 47(7), 2256-2259.
16. Kanno, Y., Wakabayashi, Y., Ikeda, M., Tatsuno, K., Misawa, Y., Sato, T., & Yotsuyanagi, H. (2017). Catheter-related bloodstream infection caused by Kodamaea ohmeri: a case report and literature review. *Journal of Infection and Chemotherapy*, 23(6), 410-414.
17. Youssef, D., Youssef, I., Marroush, T. S., & Sharma, M. (2019). Gemella endocarditis: A case report and a review of the literature. *Avicenna journal of medicine*, 9(4), 164.



**International  
Journal of  
Medical**  
Reviews and  
Case Reports.

Language: [ [English](#) ]

ALL SUBMISSIONS SCREENED BY:



Contact: [Visit journal's web site](#)

## Author Tools

- [Plagiarism Check](#)

## International Journal of Medical Reviews and Case Reports

**International Journal of Medical Reviews and Case Reports (Int J Med Rev Case Rep)**

**ISSN: 2534-9821**

International Journal of Medical Reviews and Case Reports (Int J Med Rev Case Rep) is a semi-monthly (24 issues per year), an international, single-blinded peer-review journal committed to promoting the highest standards of scientific exchange and education. It attempts to cover various aspects of medicine for its readers.

The journal's full text is available online at <http://www.journalmedicalreports.com> and [www.mdpub.net](http://www.mdpub.net). The journal allows green open access to its contents. International Journal of Medical Reviews and Case Reports (Int J Med Rev Case Rep) is dedicated to publishing reports on all aspects of medicine. The journal is one of the fastest communication journals and articles are published online within a short time after acceptance of manuscripts. The types of articles accepted include original articles, review articles, case reports, point of technique, correspondence, images and video cases. It accepts manuscripts in English, Spanish, French, Italian and Turkish languages.

Submit your manuscript after login in to your account. If you find any difficulty in online submission, alternatively you may submit manuscripts as an e-mail attachment to [inkov@journalmedicalreports.com](mailto:inkov@journalmedicalreports.com).

### About authors:

- 24 issues per year
- iThenticate Plagiarism Detection Software
- 6 days for the first decision
- 10 days for publishing of an accepted manuscript
- Academic SEO for the Articles
- Languages: English, Spanish, French

### Indexing and Abstracting Services

EBSCO A to Z

ProQuest

DOAJ

Bibliomed

Academic Accelerator

Semantic Scholar

Sciencegate

Scopemed

Index Copernicus (ICV 2020 = 98.54)

Google Scholar - [Citations](#)

ResearchBib (Academic Research System)

ESJI - Eurasian Scientific Journal Index

ASI - Advanced Science Index

Dimensions

ReadCube

Researcher.life

Naver Academic

**Scientometric Scores:**

Relative Citation Ratio (Pubmed) = 0.019

H-index = 2

Index Copernicus = 98.54

Information Matrix for the Analysis of Journals - ICDS 2020 =3.7

N Impact Factor = 0.05

**Index table: Articles Citing this journal (2015-2019)**

SCIE = 8 articles

Scopus = 11 articles

**Library**

NLB - National Library of Bulgaria

University of Saskatchewan

Weill Cornell Medicine - Qatar

Maastricht University Library  
Washington State University  
Glasgow Caledonian University  
University of Liverpool, Sydney Jones Library  
Imperial College London  
American University of Sharjah  
Auckland University of Technology Library  
Queensland University of Technology  
University of Pretoria  
University of Twente, University Library  
University of Skövde Library  
University of Groningen Library  
College of Europe Library  
Cardiff University  
University of the West Library  
Medical University of South Carolina Libraries  
University of North Carolina, Charlotte  
Franklin & Marshall College  
University of Maryland Libraries  
Anderson University and more 67 libraries in the world

**Online Resources**

Geneva Foundation for Medical Education and Research (GFMER)  
CrossRef  
SciLit  
Scipers  
ROAD (Directory of Open Access Scholarly Resources)  
JiFactor  
Researchgate  
International Committee of Medical Journal Editors (ICMJE)

**Author Login**

**Log into your account** for registered users

Your Email:

Password:

**I forgot my Password**

Your Email:

**I can't Login**

[Click here for a fresh Login](#)

**New User?**

[Click Here for Registration](#)

**For Authors**

[Submission Instructions](#)

[Login](#)

[International Journal of Medical Reviews and Case Reports Home Page](#)

**Contact Information**

Any correspondence, queries or additional requests for information on the manuscript submission process should be sent to the International Journal of Medical Reviews and Case Reports editorial office as follows:

Bulgarian Association of Young Surgeons (BAYS);

National Center of Public Health and Analyses (NCPHA), floor 2, office № 31, Sofia 1431, Bulgaria.

[inkov@journalmedica.com](mailto:inkov@journalmedica.com)

Financial department is managed by International Sci Ink Press.

It is a company registered in Bulgaria with registered no. 205414288 and registered address at 57 Antim I str., Vazrazhdane, Sofia, 1303, Bulgaria.

Tel: +359883427500

[Author Login](#)  
[Reviewer Login](#)  
[Editor Login](#)  
[I can't Login](#)  
[\(Clear Session\)](#)

This page is provided and maintained by eJManager. Copyright © 2012-2022 eJManager All Rights Reserved. Subject to change without notice from or liability to eJManager.

This site uses cookies in order to work properly. We do not collect information for marketing or advertising purposes.



Search for title, author, keywords etc in any field  Search



# International Journal of Medical Reviews and Case Reports.

2022, Vol: 6, Issue: 4

[Current Issue \(http://www.mdpub.net/?sec=cissue\)](http://www.mdpub.net/?sec=cissue)

6/4

[Online First \(http://www.mdpub.net/?sec=aip\)](http://www.mdpub.net/?sec=aip)

[Archive \(http://www.mdpub.net/?sec=archive\)](http://www.mdpub.net/?sec=archive)

[Aims and Scope \(http://www.mdpub.net/?sec=aimsscope\)](http://www.mdpub.net/?sec=aimsscope)

[Abstracting & Indexing \(http://www.mdpub.net/?sec=jindex\)](http://www.mdpub.net/?sec=jindex)

[Most Accessed Articles \(http://www.mdpub.net/?sec=mosta\)](http://www.mdpub.net/?sec=mosta)

[Most Downloaded Articles \(http://www.mdpub.net/?sec=mostd\)](http://www.mdpub.net/?sec=mostd)

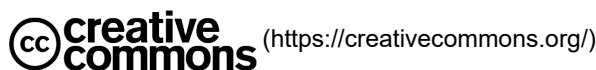[Most Cited Articles \(http://www.mdpub.net/?sec=mostc\)](http://www.mdpub.net/?sec=mostc)

**Required files to be uploaded**

**Copyright Transfer Form** (<https://www.ejmanager.com/mnstemps/172/stdfls/Copyright Transfer Form.doc>)



**Crossref** (<https://www.crossref.org/>)



« Previous Issue (<index.php?iid=2022-6-2.000&jid=172>)

Next Issue » (<index.php?iid=2022-6-4.000&jid=172>)

**Int J Med Rev Case Rep. Year: 2022, Volume: 6, Issue: 3**

**Original Research**

**1. Histopathological Spectrum of CNS Tumors: An Observational Study in a Tertiary Care Centre of North-East India**

Debadrita Sen, Prasenjit Sarkar, Alpana Banerjee, Abhijit Datta

**Int J Med Rev Case Rep. 2022; 6(3): 1-6**

» Abstract (?mno=32206)      » PDF (<index.php?fulltxt=32206&fulltxtj=172&fulltxtp=172-1638334178.pdf>)      » doi:  
10.5455/IJMRCR.HistopathologicalSpectrumofCNSTumors  
(<http://dx.doi.org/10.5455/IJMRCR.HistopathologicalSpectrumofCNSTumors>)

**2. An Epidemiological Survey And Clinical Outcome Of Healthcare-Associated Infection In A Tertiary Care ICU**

Arif S Sheikh

**Int J Med Rev Case Rep. 2022; 6(3): 7-14**

» Abstract (?mno=39464)      » PDF (<index.php?fulltxt=39464&fulltxtj=172&fulltxtp=172-1609707002.pdf>)      » doi:  
10.5455/IJMRCR.EpidemiologicalSurveyAndClinicalOutcomeOfHealth  
(<http://dx.doi.org/10.5455/IJMRCR.EpidemiologicalSurveyAndClinicalOutcomeOfHealth>)

**3. Evaluation of bacteriological profile of pyogenic infections and their susceptibility profiles at a tertiary care hospital**

Wajid M, Shazia Naaz, Syeda Saba Hashmiya

**Int J Med Rev Case Rep. 2022; 6(3): 15-19**

» Abstract (?mno=134485)      » PDF (<index.php?fulltxt=134485&fulltxtj=172&fulltxtp=172-1634739563.pdf>)      » doi:  
10.5455/IJMRCR.EVALUATIONOFBACTERIOLOGICALPROFILEOFPYOGENICINFECTIONS-798  
(<http://dx.doi.org/10.5455/IJMRCR.EVALUATIONOFBACTERIOLOGICALPROFILEOFPYOGENICINFECTIONS-798>)

**4. Laparoscopic management of pancreatic pseudocyst: Our experience in 27 cases**

Shukladhan Suresh Rode, Mahesh Dilip Birajdar, Shrikrishna Motiram Nagargoje, Kartik Chandrakant Gupta

**Int J Med Rev Case Rep. 2022; 6(3): 20-24**

» Abstract (?mno=124399)      » PDF (<index.php?fulltxt=124399&fulltxtj=172&fulltxtp=172-1631553594.pdf>)      » doi:  
10.5455/IJMRCR.LAPAROSCOPICMANAGEMENTOFPANCREATICPSEUDOCYSTOUREXPERIENCEIN27CASES  
(<http://dx.doi.org/10.5455/IJMRCR.LAPAROSCOPICMANAGEMENTOFPANCREATICPSEUDOCYSTOUREXPERIENCEIN27CASES>)

**Case Report**

**5. Activated phosphoinositide 3-kinase delta syndrome in a Portuguese teenager with PIK3R1 variant, a case report**

Lorena Stella, Mariana Sá Pinto, Eduarda Ferreira, Joo Parente Freixo, Isabel Carvalho, Diana Moreira

**Int J Med Rev Case Rep. 2022; 6(3): 25-27**

» Abstract (?mno=5276) » PDF (index.php?fulltxt=5276&fulltxtj=172&fulltxtp=172-1642338468.pdf) » doi:  
 10.5455/IJMRCR.Activatedphosphoinositide3-kinasedeltasynromeinaPortugueseteenagerwithPIK3R1  
 (http://dx.doi.org/10.5455/IJMRCR.Activatedphosphoinositide3-kinasedeltasynromeinaPortugueseteenagerwithPIK3R1)

**Original Research****6. Oral drug challenge in drug hypersensitivity reactions and its safety**

Lorena Stella, Joana Soares, Adriana Ferreira, Fátima Praça, Jorge Romariz, Herculano Costa, Cludia Pedrosa,

**Int J Med Rev Case Rep. 2022; 6(3): 28-30**

» Abstract (?mno=87719) » PDF (index.php?fulltxt=87719&fulltxtj=172&fulltxtp=172-1639996311.pdf) » doi:  
 10.5455/IJMRCR.Oraldrugchallengeindrughypersensitivityreactionsanditsafety  
 (http://dx.doi.org/10.5455/IJMRCR.Oraldrugchallengeindrughypersensitivityreactionsanditsafety)

**Case Report****7. A lung cancer revealing a right aortic arch with a Kommerell diverticulum: A case report**

Hasna Belgadir, Ilias Zakariaa, Sarah Jelloul, Khaoula Fadil, Aicha Merzem, Omar Amriss, Moussali Nadia, Naima Elbenna, Maaroufi Mehdi, Nahid Zaghba

**Int J Med Rev Case Rep. 2022; 6(3): 31-33**

» Abstract (?mno=139022) » PDF (index.php?fulltxt=139022&fulltxtj=172&fulltxtp=172-1636479966.pdf) » doi:  
 10.5455/IJMRCR.AlungcancerrevealingarightaorticarchwithaKommerelldiverticulum  
 (http://dx.doi.org/10.5455/IJMRCR.AlungcancerrevealingarightaorticarchwithaKommerelldiverticulum)

**Original Research****8. Cytogenetic evaluation of antidepressant drug, Sertraline, in vitro**

Rawaa Mohammed Abdo, Sayran Kamal Mohammad Salih, Dian Jamel Salih, Asaad Abdulwahid Alasady

**Int J Med Rev Case Rep. 2022; 6(3): 34-39**

» Abstract (?mno=92249) » PDF (index.php?fulltxt=92249&fulltxtj=172&fulltxtp=172-1625165227.pdf) » doi:  
 10.5455/IJMRCR.Cytogeneticevaluationofantidepressantdrug  
 (http://dx.doi.org/10.5455/IJMRCR.Cytogeneticevaluationofantidepressantdrug)

**Case Series****9. Epidemiological Investigation of two Family clusters of COVID-19 from central Kerala**

Sreedevi C, Shilu Mariam Zachariah, Divyamol N

**Int J Med Rev Case Rep. 2022; 6(3): 40-42**

» Abstract (?mno=8661) » PDF (index.php?fulltxt=8661&fulltxtj=172&fulltxtp=172-1642578740.pdf) » doi:  
 10.5455/IJMRCR.EpidemiologicalInvestigationoftwoFamilyclustersofCOVID-19  
 (http://dx.doi.org/10.5455/IJMRCR.EpidemiologicalInvestigationoftwoFamilyclustersofCOVID-19)

**Original Article****10. Casuistry of a Primary Health Care Internship in an African country**

Sofia Brandão Miranda, Joana Vilaça, Fábica Carvalho

**Int J Med Rev Case Rep. 2022; 6(3): 43-45**

» Abstract (?mno=104389) » PDF (index.php?fulltxt=104389&fulltxtj=172&fulltxtp=172-1627656820.pdf) » doi:  
 10.5455/IJMRCR.CasuistryofaPrimaryHealthCareInternshipinAnAfricanCountry  
 (http://dx.doi.org/10.5455/IJMRCR.CasuistryofaPrimaryHealthCareInternshipinAnAfricanCountry)

**Image****11. Lichen scrofulosorum: a rare clue to Mycobacterium tuberculosis infection**

Ana Luísa Nunes, Daniela Santos, Carolina Figueiredo, Ana Lai, Jandira Lima

**Int J Med Rev Case Rep. 2022; 6(3): 46-48**» Abstract (?mno=139723) » PDF (index.php?fulltxt=139723&fulltxtj=172&fulltxtp=172-1640742870.pdf) » doi:  
10.5455/IJMRCR.Lichenscrofulosorum-139723 (<http://dx.doi.org/10.5455/IJMRCR.Lichenscrofulosorum-139723>)**Case Report****12. A Rare Underlying Cause of Priapism**

Michael Shalaby, Jonathan Morgan, Karen Greenberg

**Int J Med Rev Case Rep. 2022; 6(3): 49-51**» Abstract (?mno=80766) » PDF (index.php?fulltxt=80766&fulltxtj=172&fulltxtp=172-1620773320.pdf) » doi:  
10.5455/IJMRCR.ARareUnderlyingCauseofPriapism (<http://dx.doi.org/10.5455/IJMRCR.ARareUnderlyingCauseofPriapism>)**13. Lytic lesion of a digit could be a metastasis from lung. A rare case report**

Tanveer Ahmed Bhat, Mohsin Mir, Nahida Yousuf, Hatan Mortada, Khadija Mustafa Ahmed

**Int J Med Rev Case Rep. 2022; 6(3): 52-53**» Abstract (?mno=94297) » PDF (index.php?fulltxt=94297&fulltxtj=172&fulltxtp=172-1625665544.pdf) » doi:  
10.5455/IJMRCR.172-1625665544 (<http://dx.doi.org/10.5455/IJMRCR.172-1625665544>)**14. Sarcome d'ewing - une localisation exceptionnelle: le sinus sphenoidal**

Amina Bouziane, Wissal Hassani, Mohamed Iliass Yessoufou, Farid Aasouani, Fatimazharah Farhan, Zenab Alami, Mustapha Maaroufi, Touria Bouhafa

**Int J Med Rev Case Rep. 2022; 6(3): 54-57**» Abstract (?mno=40249) » PDF (index.php?fulltxt=40249&fulltxtj=172&fulltxtp=172-1638906040.pdf) » doi:  
10.5455/IJMRCR.172-1638906040 (<http://dx.doi.org/10.5455/IJMRCR.172-1638906040>)**15. The Burden of Cancer in Bali: An Epidemiology Report 2017-2019**

Putu Erika Paskarani, Ni Putu Sriwidyani, Ni Made Dian Kurniasari, Tanaka, Christine Rosalina Butar Butar

**Int J Med Rev Case Rep. 2022; 6(3): 58-62**» Abstract (?mno=117638) » PDF (index.php?fulltxt=117638&fulltxtj=172&fulltxtp=172-1630315741.pdf) » doi:  
10.5455/IJMRCR.172-1630315741 (<http://dx.doi.org/10.5455/IJMRCR.172-1630315741>)**16. Case report of Rhizobium radiobacter neonatal sepsis in Sanglah hospital**

Samantha Celena Triadi, I Dewa Made Sukrama, Ni Made Adi Tarini

**Int J Med Rev Case Rep. 2022; 6(3): 63-65**» Abstract (?mno=132265) » PDF (index.php?fulltxt=132265&fulltxtj=172&fulltxtp=172-1634007369.pdf) » doi:  
10.5455/IJMRCR.CASEREPOROTFRHIZOBIUMRADIOBACTERNEONATAL  
(<http://dx.doi.org/10.5455/IJMRCR.CASEREPOROTFRHIZOBIUMRADIOBACTERNEONATAL>)**Original Research****17. A one year study of spectrum of ocular lesions in a tertiary care centre**

Ashwini Natekar, Megha Kinake, Shweta Watane, Snehal Chavhan, Sanjay Bijwe

**Int J Med Rev Case Rep. 2022; 6(3): 66-70**» Abstract (?mno=126627) » PDF (index.php?fulltxt=126627&fulltxtj=172&fulltxtp=172-1632391277.pdf) » doi:  
10.5455/IJMRCR.AONEYEARSTUDYOFSPPECTRUMOFOCULARLESIONS  
(<http://dx.doi.org/10.5455/IJMRCR.AONEYEARSTUDYOFSPPECTRUMOFOCULARLESIONS>)

**Case Report****18. Malignant Peritoneal Mesothelioma in a Treated Patient of Pleural Mesothelioma Detected on 18F-Fluorodeoxyglucose Positron Emission Tomography Scan**

Mishal Mumtaz, Muhammad Numair Younis, Abubaker Shahid

**Int J Med Rev Case Rep. 2022; 6(3): 71-73**» Abstract (?mno=79245) » PDF (index.php?fulltxt=79245&fulltxtj=172&fulltxtp=172-1620237775.pdf) » doi:  
10.5455/IJMRCR.172-1620237775 (<http://dx.doi.org/10.5455/IJMRCR.172-1620237775>)**19. Sinonasal Hemangiopericytoma: Late local recurrence, therapeutic difficulties: About a case**

Meryem Belhouari, Hind Zidani, Nezha Tawfik, Mouna Bourhafour, Nadia Benchakroun, Zineb Bouchbika, Hassan Jouhadi, Souha sahraoui, Abdeltif Benider

**Int J Med Rev Case Rep. 2022; 6(3): 74-76**» Abstract (?mno=83446) » PDF (index.php?fulltxt=83446&fulltxtj=172&fulltxtp=172-1621869776.pdf) » doi:  
10.5455/IJMRCR.172-1621869776 (<http://dx.doi.org/10.5455/IJMRCR.172-1621869776>)**20. Safety and Effectiveness of HAL-RAR (Haemorrhoid Arteri Ligation with Recto Anal Repair) With No Doppler Guided Technique on Stage III Internal Haemorrhoid: A Single Operator Experience**

Budhi Ida Bagus, Metria Ida Bagus, Setyawati Ida Ayu

**Int J Med Rev Case Rep. 2022; 6(3): 77-78**» Abstract (?mno=76621) » PDF (index.php?fulltxt=76621&fulltxtj=172&fulltxtp=172-1619419640.pdf) » doi:  
10.5455/IJMRCR.SafetyandEffectivenessofHAL-RAR (<http://dx.doi.org/10.5455/IJMRCR.SafetyandEffectivenessofHAL-RAR>)**eJM****Submit Article**

eJManager.com

[\(http://www.ejmanager.com/my/ijmrcr/\)](http://www.ejmanager.com/my/ijmrcr/)**eJM****Track your Article**

eJManager.com

 [\(http://www.ejmanager.com/my/ijmrcr/submit.php?isl=track\)](http://www.ejmanager.com/my/ijmrcr/submit.php?isl=track)[Author Login \(http://www.ejmanager.com/my/ijmrcr\)](http://www.ejmanager.com/my/ijmrcr/)[Reviewer Login \(https://www.ejmanager.com/reviewers/index.php?isl=login\)](https://www.ejmanager.com/reviewers/index.php?isl=login)[About Publisher \(http://www.mdpub.net/?sec=aboutpublisher\)](http://www.mdpub.net/?sec=aboutpublisher)

[Editorial Policies \(http://www.mdpub.net/?sec=policyeditorial\)](http://www.mdpub.net/?sec=policyeditorial)

[Peer Review Policy \(http://www.mdpub.net/?sec=peerreviewpolicy\)](http://www.mdpub.net/?sec=peerreviewpolicy)

[Editorial & Peer Review Process \(http://www.mdpub.net/?sec=editorialprocess\)](http://www.mdpub.net/?sec=editorialprocess)

[Author's Rights and Obligations \(http://www.mdpub.net/?sec=policyauthorsrights\)](http://www.mdpub.net/?sec=policyauthorsrights)

[Publication Ethics and Publication Malpractice Statement \(http://www.mdpub.net/?sec=policypubethics\)](http://www.mdpub.net/?sec=policypubethics)

[Conflict of Interest Policy \(http://www.mdpub.net/?sec=policycois\)](http://www.mdpub.net/?sec=policycois)

[Plagiarism Policy \(http://www.mdpub.net/?sec=policyplagiarism\)](http://www.mdpub.net/?sec=policyplagiarism)

[Protection of Research Participants \(Statement On Human And Animal Rights\) \(http://www.mdpub.net/?sec=policyhar\)](http://www.mdpub.net/?sec=policyhar)

[Privacy Policy \(http://www.mdpub.net/?sec=policyprivacy\)](http://www.mdpub.net/?sec=policyprivacy)

[Publication Ethics and Publication Malpractice Statement \(http://www.mdpub.net/?sec=policypubethics\)](http://www.mdpub.net/?sec=policypubethics)

[Corrections, Retractions & Expressions of Concern \(http://www.mdpub.net/?sec=correctionretractionconcern\)](http://www.mdpub.net/?sec=correctionretractionconcern)

[Self-Archiving Policies \(http://www.mdpub.net/?sec=selfarchivingpolicy\)](http://www.mdpub.net/?sec=selfarchivingpolicy)

[Statement of Informed Consent \(http://www.mdpub.net/?sec=informedconsent\)](http://www.mdpub.net/?sec=informedconsent)

[Advertising Policy \(http://www.mdpub.net/?sec=policyadvertising\)](http://www.mdpub.net/?sec=policyadvertising)

[Terms of Use \(http://www.mdpub.net/?sec=policytermofuse\)](http://www.mdpub.net/?sec=policytermofuse)

[License Information \(http://www.mdpub.net/?sec=licenseinfo\)](http://www.mdpub.net/?sec=licenseinfo)

[Copyright Information \(http://www.mdpub.net/?sec=copyrightinfo\)](http://www.mdpub.net/?sec=copyrightinfo)



Copyright © 2022 International Journal of Medical Reviews and Case Reports All Rights Reserved. Subject to change without notice from or liability to International Journal of Medical Reviews and Case Reports.

For best results, please use Internet Explorer or Google Chrome

## Contact Information

---

Any correspondence, queries or additional requests for information on the manuscript submission process should be sent to the International Journal of Medical Reviews and Case Reports editorial office as follows:

Bulgarian Association of Young Surgeons (BAYS);

National Center of Public Health and Analyses (NCPHA), floor 2, office № 31, Sofia 1431, Bulgaria.

[inkov@journalmedica.com](mailto:inkov@journalmedica.com) (<mailto:inkov@journalmedica.com>)

---

Financial department is managed by International Sci Ink Press.

It is a company registered in Bulgaria with registered no. 205414288 and registered address at 57 Antim I str., Vazrazhdane, Sofia, 1303, Bulgaria.

Tel: +359883427500