

Neurocysticercosis Diagnosed in a Patient with *Taenia saginata* Taeniasis after Administration of Praziquantel: A Case Study and Review of the Literature

Toni Wandra¹, Raka Sudewi², Ni Made Susilawati², Kadek Swastika³, I Made Sudarmaja³, Luh Putu Eka Diarthini³, Ivan Elisabeth Purba¹, Munehiro Okamoto⁴, Christine M. Budke⁵ and Akira Wandra⁶

¹North Sumatra, Sari Mutiara Indonesia University, Indonesia

²Department of Neurology, Sanglah Hospital, Udayana University, Denpasar, Bali, Indonesia

³Department of Parasitology, Udayana University, Denpasar, Bali, Indonesia

⁴Section of Wildlife Diversity, Center for Human Evolution Modeling Research, Primate Research Institute, Kyoto University, Inuyama, Japan

⁵Department of Veterinary Integrative Biosciences, College of Veterinary Medicine, Biomedical Sciences, Texas A&M University, College Station, TX, USA

⁶Department of Parasitology, Asahikawa Medical University, Asahikawa, Japan

Abstract

Taeniasis, caused by infection with *Taenia saginata* or *Taenia solium*, occurs on Bali due to the consumption of undercooked beef and pork, respectively. Fieldwork conducted on Bali from 2002-2007, identified taeniasis cases due to *T. saginata*. In August 2007, three *T. saginata* tapeworm carriers in the Gianyar district of Bali were treated with a single dose of praziquantel. Within a few hours of treatment, a 47 year old man had a seizure and was admitted to a hospital in the city of Denpasar. A computed tomography (CT) scan revealed two cystic lesions in the man's brain. Serology showed specific antibody responses to *T. solium* metacestode antigens. The patient was, therefore, diagnosed with a dual infection of *T. solium* neurocysticercosis (NCC) and *T. saginata* taeniasis. This case report is illustrative of the risk of veiled NCC in areas where *T. saginata* and *T. solium* are co-endemic. As globalization increases, the possibility of co-infections will continue to rise and researchers and physicians participating in mass drug administration programs will need to be vigilant in their monitoring for adverse effects.

Keywords: Taeniasis; *Taenia saginata*; *Taenia asiatica*; *Taenia solium*; Neurocysticercosis; Praziquantel; Niclosamide; Bali; Indonesia; Asia

Introduction

Taeniasis/cysticercosis, caused by the pork tapeworm, *Taenia solium*, is a parasitic zoonosis found primarily in countries where pigs are raised and meat inspection is lacking [1,2]. The potential for a tapeworm carrier to infect another individual (or themselves via autoinfection), resulting in cysticercosis or neurocysticercosis (NCC), is a risk not only in endemic areas, but also in areas with immigrants from endemic countries [1,3-5]. An example of such an outbreak occurred in an Orthodox Jewish community in New York City when family members were infected by a domestic employee from a *T. solium* endemic country [6]. Such NCC outbreaks have occurred in other developed countries, including countries in the Middle East where people do not consume pork [4,5,7-13].

In Asia, there are three *Taenia* tapeworms that infect humans; *T. solium*, *Taenia saginata* and *Taenia asiatica* [4,5,14-24]. Although adult *T. solium* worms with scoleces are easily differentiated morphologically from other taeniids, it is almost impossible to differentiate adult *T. asiatica* and *T. saginata* [5,22,25,26]. Therefore, molecular differentiation is often required to correctly identify the infecting species [27]. Recent studies have also reported hybrids of *T. saginata* and *T. asiatica* in Thailand and China [5,25,28-32]. This makes mitochondrial and nuclear gene analyses even more important for the differentiation of *T. saginata*, *T. asiatica*, and hybrids of these two species [30-32].

In Indonesia, *T. solium*, *T. saginata* and *T. asiatica* are distributed according to livestock rearing and local food consumption practices [33-40]. Both *T. saginata* and *T. solium* have been confirmed from the island of Bali, where the local inhabitants are known to eat dishes that contain undercooked beef and pork, such as the traditional dish *Babi Gresik*. NCC was considered endemic in Bali more than 20 years ago [41,42]. However, education programs aimed at keeping pigs indoors to prevent access to human faeces and the introduction of improved sanitation

systems and practices substantially reduced the prevalence of NCC during the past 2 decades [35,37,43]. Nevertheless, there are still sporadic NCC cases identified on Bali [40,42-45].

Case Report

Fieldwork conducted on Bali from 2002-2007 resulted in the identification of taeniasis carriers who were treated with a single dose of praziquantel (PZQ) at 15 mg/kg body weight (Table 1). All worms were confirmed to be *T. saginata* by multiplex PCR [36]. In August 2007, a 47 year old male taeniasis carrier from the Gianyar district suffered a single tonic-clonic seizure within a few hours of PZQ administration. The patient was subsequently admitted to the Sanglah Hospital in Denpasar. A computed tomography (CT) scan revealed one viable cystic lesion and one calcified lesion in the right frontal lobe of the brain. At this time, serology (ELISA) was also carried out using partially purified antigens by cation exchange chromatography [46]. The patient was subsequently diagnosed with NCC and treated with albendazole for one month. He was followed serologically through May 2015 (Table 2).

Discussion

Although PZQ has been recommended for the treatment of taeniasis, there are reports of seizures triggered within a few hours of

***Corresponding author:** Toni Wandra, Department of Parasitology, Asahikawa Medical University, Asahikawa, Japan, E-mail: akiraito@asahikawa-med.ac.jp

Received June 03, 2016; **Accepted** July 12, 2016; **Published** July 19, 2016

Citation: Wandra T, Sudewi R, Susilawati NM, Swastika K, Sudarmaja IM, et al. (2016) Neurocysticercosis Diagnosed in a Patient with *Taenia saginata* Taeniasis after Administration of Praziquantel: A Case Study and Review of the Literature. Primary Health Care 6: 231. doi:10.4172/2167-1079.1000231

Copyright: © 2016 Wandra T, et al. This is an open-access article distributed under the terms of the Creative Commons Attribution License, which permits unrestricted use, distribution, and reproduction in any medium, provided the original author and source are credited.

District* (Year)	No. of <i>T. saginata</i> taeniasis cases	No. of <i>T. solium</i> taeniasis cases
Gianyar (2002) [#]	32	0
Gianyar (2004) [#]	14	0
Gianyar (2005) [#]	5	0
Gianyar (2006) [#]	2	0
Gianyar (2007) [#]	3	0
Gianyar (2008)	4	0
Gianyar (2009)	7	0
Gianyar (2010)	18	0
Gianyar (2011)	9	0
Gianyar (Jan 2013)	6	0
Gianyar (Sept 2013)	9	0
Gianyar (2014)	4	0
Badung (2004)	1	0
Denpasar (2004)	9	0
Denpasar (2005)	2	0
Denpasar (2010)	3	0
Karangasem (urban area, 2006)	1	0
Bangli (2007)	0	0
Tabanan (2007)	0	0
Jembrana (2008)	0	0
Klungkung (2009)	0	0
Buleleng (2009)	0	0
Karangasem (rural area, 2011)	0	3
Karangasem (rural area, 2013)	0	6
Karangasem (rural area, 2014)	0	2 [§]
Karangasem (rural area, 2014)	0	2 [§]
Total	129	13

* See Figure 1.
[#] Treated with Praziquantel.
[§] Swastika et al., unpublished.

Table 1: Number of taeniasis cases due to *T. saginata* and *T. solium* in Bali 2002-2014 [11].

drug administration producing an antibody response that can remain for months [2,9,47-52]. PZQ is also the first choice for treatment of trematodiasis, including schistosomiasis and food-borne trematodiasis [53-56]. Therefore, in regions such as Asia where trematode and *T. solium* infections both occur, there is also the risk of a negative reaction if an individual treated for trematodiasis has silent NCC.

Previously asymptomatic NCC may become symptomatic when the parasite(s) are damaged by the host's immune response or by PZQ treatment. Therefore, there is a debate whether NCC patients should be treated with an anthelmintic, such as albendazole, to accelerate the death of the parasite or solely with a steroid to control the inflammatory response [2,9,47-53]. The patient described in this case report had no history of epileptic seizures before PZQ treatment. A single dose of PZQ at 40 mg/kg is typically used for mass drug treatment of trematodiasis, whereas a single dose of PZQ at 10 mg/kg is considered >95% efficacious for treating taeniasis [2,57]. A study conducted in Mexico reported that symptoms associated with NCC could be induced with a single dose of PZQ at 5 mg/kg [58,59].

In Indonesia, taeniasis is primarily caused by *T. saginata*. Even on Bali where the local inhabitants eat both pork and beef, the majority of tapeworms are identified as *T. saginata* (Table 1 and Figure 1). However, since January 2011, a total of 13 *T. solium* tapeworms have been confirmed from 13 villagers from small remote villages located on the eastern slope of Mt. Agung in the Karangasem district of northeastern

Date	Absorbance value	Cut off
August 2007 (before treatment)	0.103	0.022
December 2007 (after treatment)	0.578	
February 2009	0.070	0.038
May 2015	0.016	

Table 2: ELISA results from 2007 until 2015.

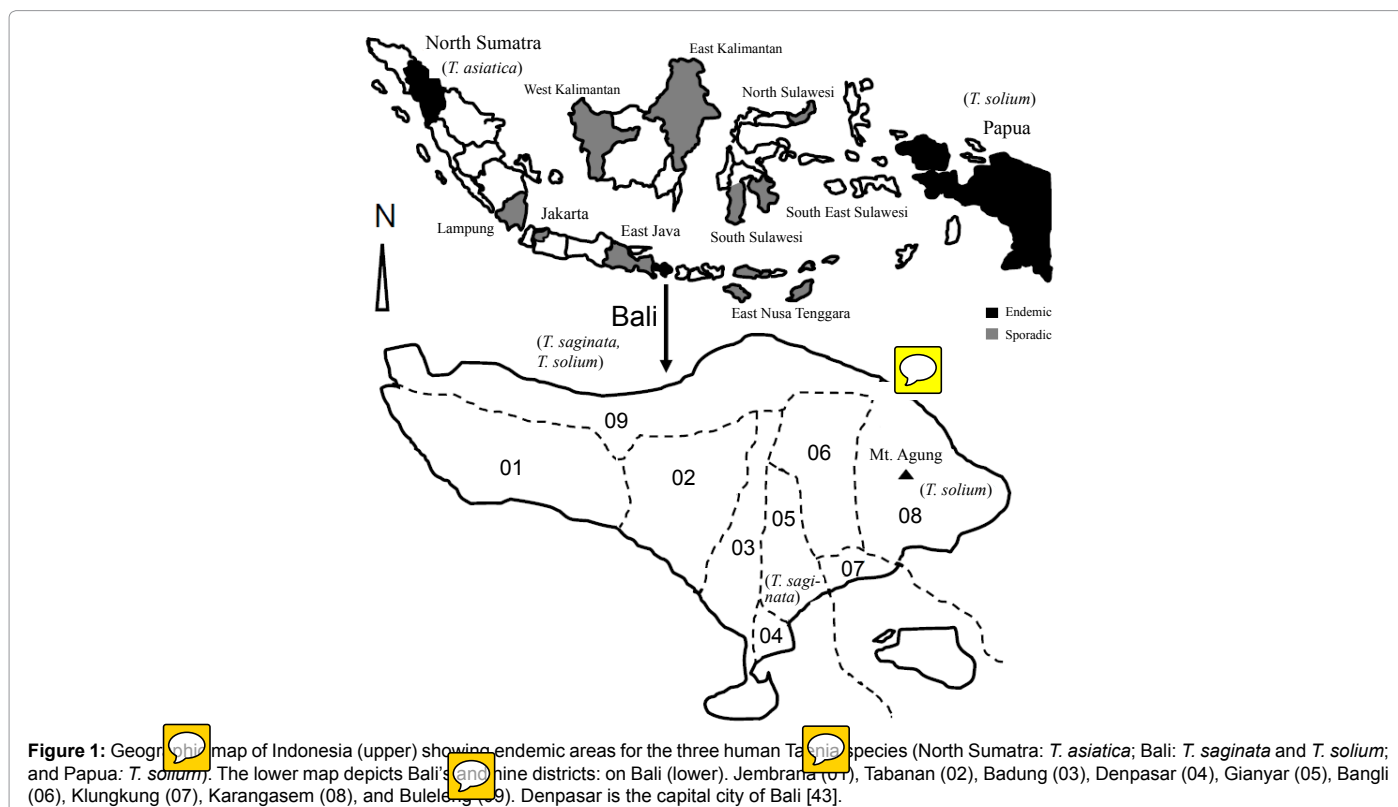


Figure 1: Geographical map of Indonesia (upper) showing endemic areas for the three human Taenia species (North Sumatra: *T. asiatica*; Bali: *T. saginata* and *T. solium*; and Papua: *T. solium*). The lower map depicts Bali's nine districts: on Bali (lower). Jembrana (01), Tabanan (02), Badung (03), Denpasar (04), Gianyar (05), Bangli (06), Klungkung (07), Karangasem (08), and Buleleng (09). Denpasar is the capital city of Bali [43].

Bali (Table 1). The patient described in this case report had no history of visiting Karangasem. Therefore, it is likely that he became infected with *T. solium* eggs in Gianyar or the surrounding area. Additional studies are needed to better elaborate the epidemiology of *T. solium* in Gianyar.

On Bali, *T. saginata* taeniasis is rather common in communities where people like to eat dishes prepared with undercooked beef (Table 1) [11,36,43]. While *T. saginata* taeniasis carriers are not directly a public health threat, *T. solium* taeniasis carriers can potentially infect others (or themselves via autoinfection). This is especially worrisome when considering that populations from known *T. solium* endemic regions of Bali, such as Karangasem, often travel to other parts of the island to find work [11].

If PZQ is recommended for mass drug treatment of trematodiasis or taeniasis where *T. solium* is distributed, seizures related to previously asymptomatic NCC should be anticipated. There are currently two choices for anthelmintic treatment of tapeworm carriers. The first is treatment with PZQ and the second is treatment with niclosamide. Since 2008, all *T. saginata* taeniasis cases (n=57) on Bali have been treated with niclosamide (single dose of 2,000 mg). Thus far, no NCC related clinical manifestations have been reported in response to niclosamide administration, including in 3 patients with confirmed dual infections [40]. Chinese traditional medicine (pumpkin seeds plus areca nut extract) has also been used to expel tapeworms without the risk of causing seizures [26,54,60].

In order to avoid inducing seizures in previously asymptomatic NCC patients, it would be beneficial to test taeniasis carriers for a *T. solium* cysticercosis antibody response prior to treatment in areas where *T. solium* is sympatrically distributed with other human *Taenia* species [60]. For such real-time serodiagnosis in the field, more rapid field-based tests are needed [4]. In the time being, researchers and physicians participating in mass drug administration programs using PZQ should be vigilant in their monitoring for adverse effects of drug administration that may be attributable to previously silent NCC.

Acknowledgement

We sincerely thank Sako Y for technical assistance with the serology.

References

- Schantz PM, Cruz M, Sarti E, Pawlowski Z (1993) Potential eradicability of taeniasis and cysticercosis. Bull Pan Am Health Organ 27: 397-403.
- Pawlowski ZS (2016) Taeniosis/neurocysticercosis control as a medical problem—a discussion paper. World J Neurosci 6: 165-170.
- Kobayashi K, Nakamura-Uchiyama F, Nishiguchi T, Isoda K, Kokubo Y, et al. (2013) Rare case of disseminated cysticercosis and taeniasis in a Japanese traveller after returning from India. Am J Trop Med Hyg 89: 58-61.
- Ito A, Budke CM (2014) Culinary delights and travel? A review of zoonotic cestodiasis and metacestodiasis. Travel Med Infect Dis 12: 582-591.
- Ito A, Yanagida T, Nakao M (2016) Recent advances and perspectives in molecular epidemiology of *Taenia solium* cysticercosis. Infect Genet Evol 40: 357-367.
- Schantz PM, Moore AC, Muñoz JL, Hartman BJ, Schaefer JA, et al. (1992) Neurocysticercosis in an Orthodox Jewish community in New York City. N Engl J Med 327: 692-695.
- Hira PR, Francis I, Abdella NA, Gupta R, Ai-Ali FM, et al. (2004) Cysticercosis: Imported and autochthonous infections in Kuwait. Trans R Soc Trop Med Hyg 98: 233-239.
- Leshem E, Kliens I, Bakon M, Gomori M, Karplus R, et al. (2011) Neurocysticercosis in travellers: A nation-wide study in Israel. J Travel Med 18: 191-197.
- Del Brutto OH (2013) Neurocysticercosis on the Arabian Peninsula, 2003-2011. Emerg Infect Dis 19: 172-174.

- Ito A, Wandra T, Li T, Dekumyoy P, Nkouawa A, et al. (2014) The present situation of human taeniasis and cysticercosis in Asia. Recent Pat Antiinfect Drug Discov 9: 173-185.
- Wandra T, Swastika K, Dharmawan NS (2015) The present situation and towards the prevention and control of cysticercosis on the tropical island, Bali, Indonesia. Parasit Vectors 8: 148.
- Jabbar A, Gauci CG, Lightowlers MW (2016) Diagnosis of human taeniasis. Microbiol Austr 14: 14-16.
- Lightowlers MW, Garcia HH, Gauci CG, Donadeu M, et al. (2016) Monitoring the outcomes of interventions against *Taenia solium*: Options and suggestions. Parasite Immunol 38: 158-169.
- Fan PC (1988) Taiwan taenia and taeniasis. Parasitol Today 4: 86-88.
- Fan PC, Chung WC, Lin CY, Wu CC (1990) The pig as an intermediate host for Taiwan Taenia infection. J Helminthol 64: 223-231.
- Fan PC, Soh CT, Kosin E (1990b) Pig as a favorable intermediate host of a possible new species of *Taenia* in Asia. Yonsei Rep Trop Med 21: 39-58.
- Eom KS, Rim HJ (1993) Morphologic descriptions of *Taenia asiatica* sp. n. Korean J Parasitol 31: 1-6.
- Ito A, Nakao M, Wandra T (2003) Human Taeniasis and cysticercosis in Asia. Lancet 362: 1918-1920.
- Ito A, Wandra T, Yamasaki H, Nakao M, Sako Y, et al. (2004) Cysticercosis/taeniasis in Asia and the Pacific. Vector Borne Zoonotic Dis 4: 95-107.
- Ito A, Nakao M, Wandra T, Suroso T, Okamoto M, et al. (2005) Taeniasis and cysticercosis in Asia and the Pacific: Present state of knowledge and perspectives. Southeast Asian J Trop Med Public Health 36 Suppl 4: 123-130.
- Ito A, Takayanagui OM, Sako Y, Sato MO, Odashima NS, et al. (2006) Neurocysticercosis: Clinical manifestation, neuroimaging, serology and molecular confirmation of histopathological specimens. Southeast Asian J Trop Med Public Health 37: 74-81.
- Flisser A, Craig PS, Ito A (2011) Cysticercosis and taeniasis: *Taenia solium*, *Taenia saginata* and *Taenia asiatica*: Oxford Textbook of Zoonoses. (2nd edn), Oxford University Press, Oxford.
- Aung AK, Spelman DW (2016) *Taenia solium* Taeniasis and Cysticercosis in Southeast Asia. Am J Trop Med Hyg 94: 947-954.
- Chaisiri K, Kusolsuk T, Dekumyoy P, Sanguankiat S, Homsuwan N, et al. (2016) Gastrointestinal helminths and *Taenia* spp. in parenteral tissues of free-roaming pigs (*Sus scrofa indicus*) from hill-tribe village at the western border of Thailand. Trop Biomed: In press.
- Li T, Craig PS, Ito A, Chen X, Qiu D, et al. (2006) Taeniasis/cysticercosis in a Tibetan population in Sichuan Province, China. Acta Trop 100: 223-231.
- Li T, Ito A, Chen X, Long C, Okamoto M, et al. (2012) Usefulness of pumpkin seeds combined with areca nut extract in community-based treatment of human taeniasis in Northwest Sichuan Province, China. Acta Trop 124: 152-157.
- Yamasaki H, Allan JC, Sato MO, Nakao M, Sako Y, et al. (2004) DNA differential diagnosis of taeniasis and cysticercosis by multiplex PCR. J Clin Microbiol 42: 548-553.
- Anantaphruti MT, Yamasaki H, Nakao M, Waikagul J, Watthanakulpanich D, et al. (2007) Sympatric occurrence of *Taenia solium*, *T. saginata* and *T. asiatica*, Thailand. Emerg Infect Dis 13: 1413-1416.
- Anantaphruti MT, Okamoto M, Yoonuan T, Saguankiat S, Kusolsuk T, et al. (2010) Molecular and serological survey on taeniasis and cysticercosis in Kanchanaburi Province, Thailand. Parasitol Int 59: 326-330.
- Okamoto M, Nakao M, Blair D, Anantaphruti MT, Waikagul J, et al. (2010) Evidence of hybridization between *Taenia saginata* and *Taenia asiatica*. Parasitol Int 59: 70-74.
- Yamane K, Suzuki Y, Tachi E, Li T, Chen X, et al. (2012) Recent hybridization between *Taenia asiatica* and *Taenia saginata*. Parasitol Int 61: 351-355.
- Yamane K, Yanagida T, Li T, Chen X, Dekumyoy P, et al. (2013) Genotypic relationships between *Taenia saginata*, *Taenia asiatica* and their hybrids. Parasitology 140: 1595-1601.
- Wandra T, Subahar R, Simanjuntak GM, Margono SS, Suroso T, et al. (2000) Resurgence of cases of epileptic seizures and burns associated with cysticercosis in Assologaima, Jayawijaya, Irian Jaya, Indonesia, 1991-95. Trans R Soc Trop Med Hyg 94: 46-50.

34. Wandra T, Ito A, Yamasaki H, Suroso T, Margono SS (2003) *Taenia solium* Cysticercosis, Irian Jaya, Indonesia. Emerg Infect Dis 9: 884-885.
35. Wandra T, Depary AA, Sutisna P, Margono SS, Suroso T, et al. (2006) Taeniasis and cysticercosis in Bali and North Sumatra, Indonesia. Parasitol Int 55 Suppl: S155-160.
36. Wandra T, Sutisna P, Dharmawan NS, Margono SS, Sudewi R, et al. (2006) High prevalence of *Taenia saginata* taeniasis and status of *Taenia solium* cysticercosis in Bali, Indonesia, 2002-2004. Trans R Soc Trop Med Hyg 100: 346-351.
37. Wandra T, Sudewi AA, Swastika IK, Sutisna P, Dharmawan NS, et al. (2011) Taeniasis/cysticercosis in Bali, Indonesia. Southeast Asian J Trop Med Public Health 42: 793-802.
38. Margono SS, Ito A, Sato MO, Okamoto M, Subahar R, et al. (2003) *Taenia solium* taeniasis/cysticercosis in Papua, Indonesia in 2001: detection of human worm carriers. J Helminthol 77: 39-42.
39. Suroso T, Margono SS, Wandra T, Ito A (2006) Challenges for control of taeniasis/cysticercosis in Indonesia. Parasitol Int 55 Suppl: S161-165.
40. Sudewi AA, Wandra T, Artha A, Nkouawa A, Ito A (2008) *Taenia solium* cysticercosis in Bali, Indonesia: Serology and mtDNA analysis. Trans R Soc Trop Med Hyg 102: 96-98.
41. Theis JH, Goldsmith RS, Flisser A, Koss J, Chioino C, et al. (1994) Detection by immunoblot assay of antibodies to *Taenia solium* cysticerci in sera from residents of rural communities and from epileptic patients in Bali, Indonesia. Southeast Asian J Trop Med Public Health 25: 464-468.
42. Sutisna IP, Fraser A, Kapti IN, Rodriguez-Canul R, Puta Widjana D, et al. (1999) Community prevalence study of taeniasis and cysticercosis in Bali, Indonesia. Trop Med Int Health 4: 288-294.
43. Wandra T, Ito A, Swastika K, Dharmawan NS, Sako Y, et al. (2013) Taeniasis and cysticercosis in Indonesia: Past and present situations. Parasitology 140: 1608-1616.
44. Margono SS, Himawan S, Purnama TA, Subahar R, Hamid, et al. (2002) Multiple cysticercus nodules in skin and brain in a Balinese woman: A case report. Med J Indonesia 11: 169-173.
45. Swastika K, Dewiyani CI, Yanagida T, Sako Y, Sudarmaja M, et al. (2012) An ocular cysticercosis in Bali, Indonesia caused by *Taenia solium* Asian genotype. Parasitol Int 61: 378-380.
46. Sako Y, Itoh S, Okamoto M, Nakaya K, Ito A (2013) Simple and reliable preparation of immunodiagnostic antigens for *Taenia solium* cysticercosis. Parasitology 140: 1589-1594.
47. St Geme JW 3rd, Maldonado YA, Enzmann D, Hotez PJ, Overturf GD, et al. (1993) Consensus: Diagnosis and management of neurocysticercosis in children. Pediatr Infect Dis J 12: 455-461.
48. White AC Jr (1997) Neurocysticercosis: A major cause of neurological disease worldwide. Clin Infect Dis 24: 101-113.
49. Del Brutto OH (2014) Clinical management of neurocysticercosis. Expert Rev Neurother 14: 389-396.
50. Garcia HH, Nash TE, Del Brutto OH (2014) Clinical symptoms, diagnosis and treatment of neurocysticercosis. Lancet Neurol 13: 1202-1215.
51. Garcia HH, Gonzales I, Lescano AG, Bustos JA, Zimic M, et al. (2014b) Efficacy of combined anti-parasitic therapy with praziquantel and albendazole for neurocysticercosis: A double-blind, randomized controlled trial. Lancet Infect Dis 14: 687-695.
52. Nash TE, Garcia HH (2011) Diagnosis and treatment of neurocysticercosis. Nat Rev Neurol 7: 584-594.
53. Nissen S, Nguyen LA, Thamsborg SM, Dalsgaard A, Johansen MV (2014) Reinfection of dogs with fish-borne zoonotic trematodes in northern Vietnam following a single treatment with praziquantel. PLoS Negl Trop Dis 8: e2625.
54. Ito A, Li T, Chen X, Long C, Yanagida T, et al. (2013) Mini review on chemotherapy of taeniasis and cysticercosis due to *Taenia solium* in Asia, and a case report with 20 tapeworms in China. Trop Biomed 30: 164-173.
55. Ouedraogo H, Drabo F, Zongo D, Bagayan M, Bamba I, et al. (2016) Schistosomiasis in school-age children in Burkina Faso after a decade of preventive chemotherapy. Bull World Health Organ 94: 37-45.
56. Budge PJ, Sognikin E, Akosa A, Mathieu EM, Deming M (2016) Accuracy of coverage survey recall following an integrated mass drug administration for lymphatic filariasis, schistosomiasis and soil-transmitted helminthiasis. PLoS Negl Trop Dis 10, e0004358.
57. WHO (2011) Report of the WHO expert consultation on foodborne trematode infections and taeniasis/cysticercosis. Vientiane, Lao People's Democratic Republic. 12-16 October 2009. Geneva: World Health Organization.
58. Flisser A, Madrazo I, Plancarte A, Schantz P, Allan J, et al. (1993) Neurological symptoms in occult neurocysticercosis after single taeniacidal dose of praziquantel. Lancet 342: 748.
59. Sarti E, Schantz PM, Avila G, Ambrosio J, Medina-Santillán R, et al. (2000) Mass treatment against human taeniasis for the control for cysticercosis: A population-based intervention study. Trans R Soc Trop Med Hyg 94: 85-89.
60. Ito A (2013) Nothing is perfect! Trouble-shooting in immunological and molecular studies of cestode infections. Parasitology 140: 1551-1565.

Citation: Wandra T, Sudewi R, Susilawati NM, Swastika K, Sudarmaja IM, et al. (2016) Neurocysticercosis Diagnosed in a Patient with *Taenia saginata* Taeniasis after Administration of Praziquantel: A Case Study and Review of the Literature. Primary Health Care 6: 231. doi:10.4172/2167-1079.1000231

OMICS International: Publication Benefits & Features

Unique features:

- Increased global visibility of articles through worldwide distribution and indexing
- Showcasing recent research output in a timely and updated manner
- Special issues on the current trends of scientific research

Special features:

- 700+ Open Access Journals
- 50,000+ editorial team
- Rapid review process
- Quality and quick editorial, review and publication processing
- Indexing at major indexing services
- Sharing Option: Social Networking Enabled
- Authors, Reviewers and Editors rewarded with online Scientific Credits
- Better discount for your subsequent articles

Submit your manuscript at: <http://www.omicsonline.org/submit>