
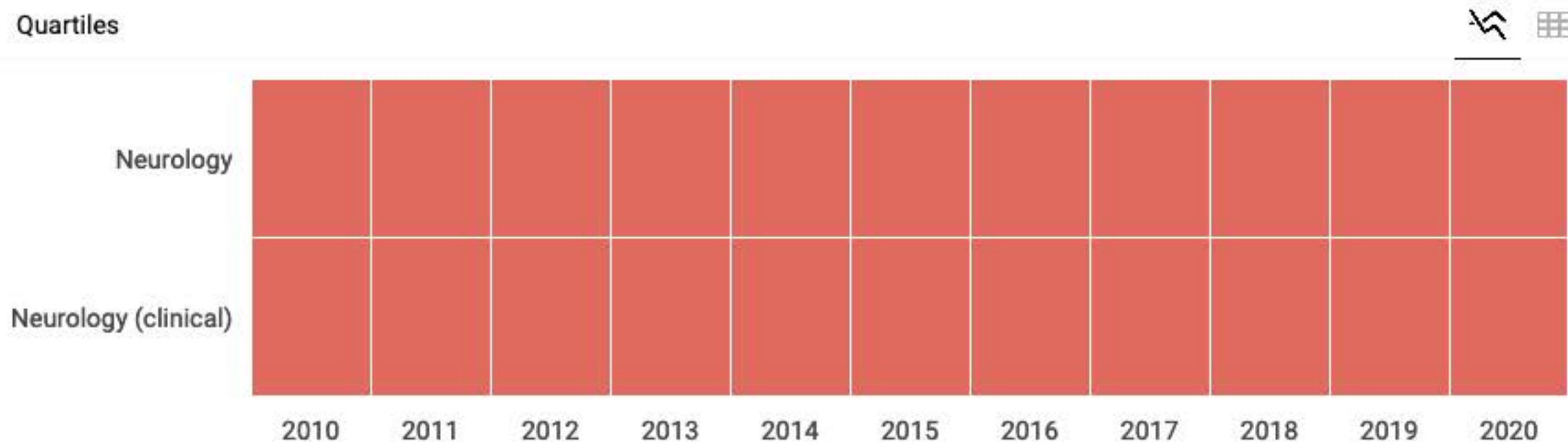


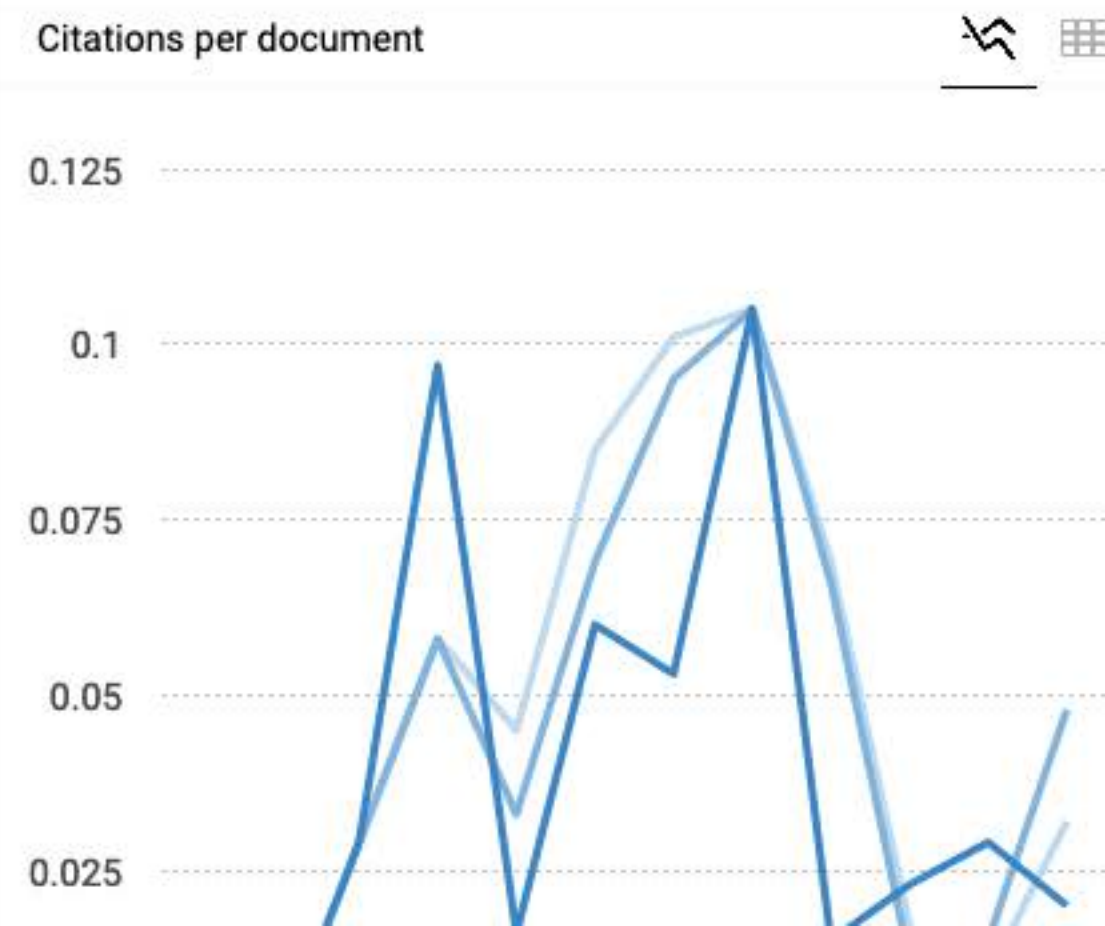
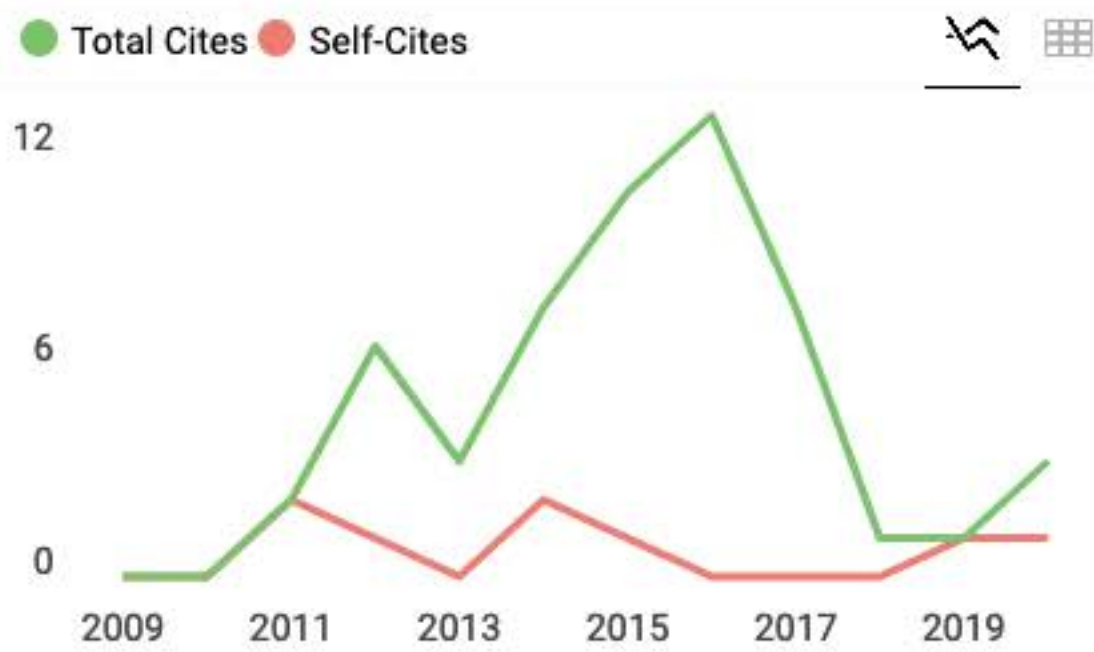
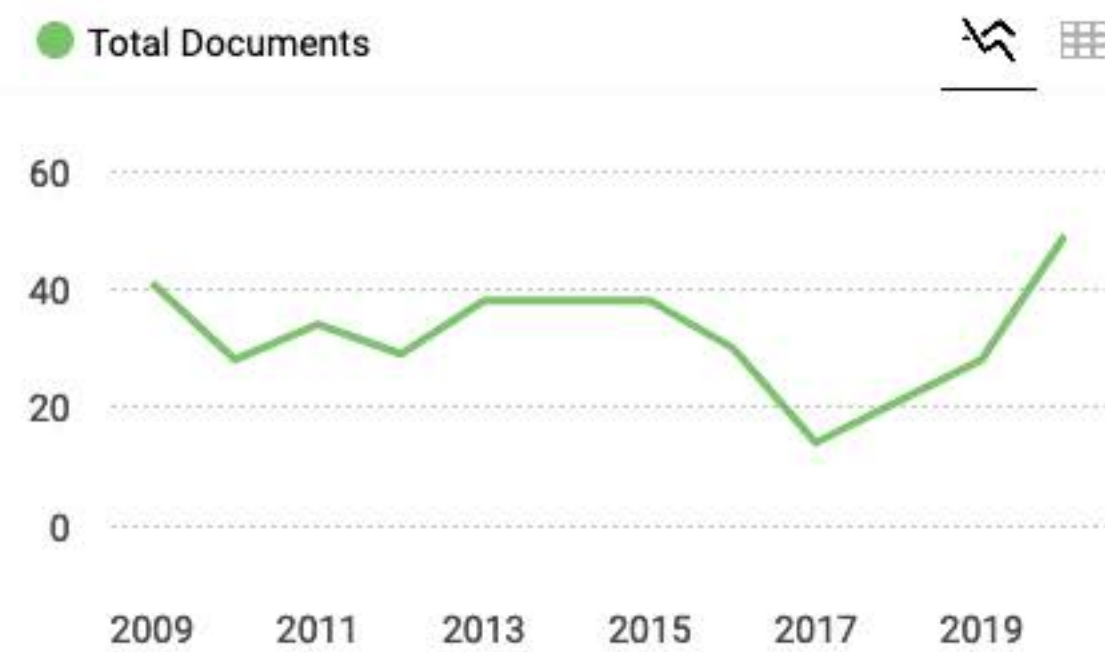
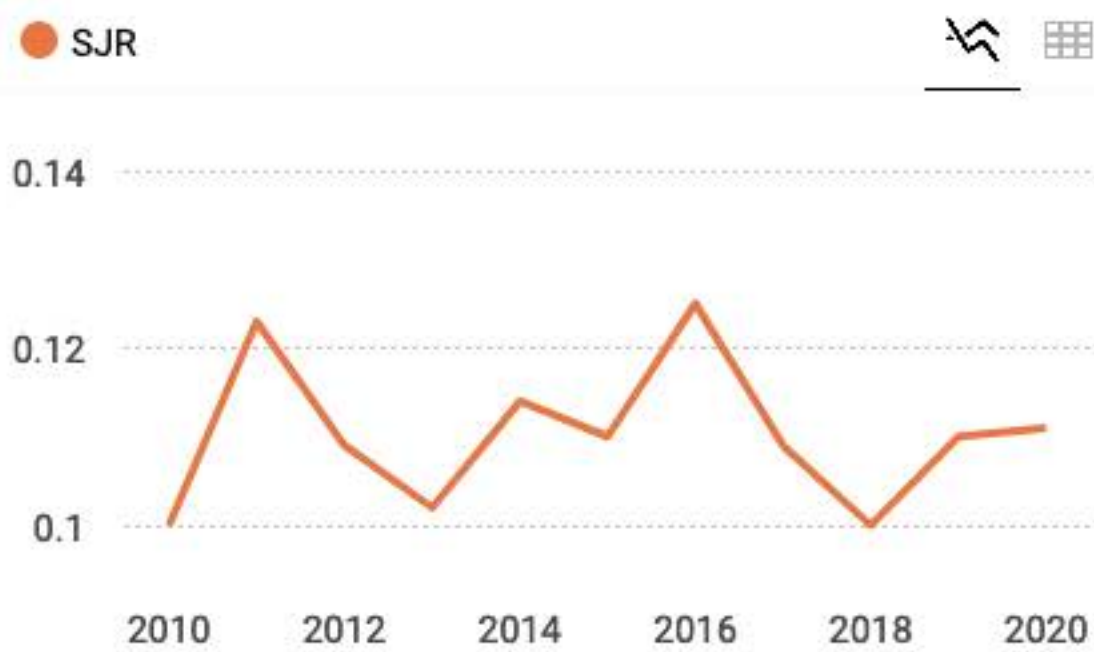Romanian Journal of Neurology/ Revista Romana de Neurologie

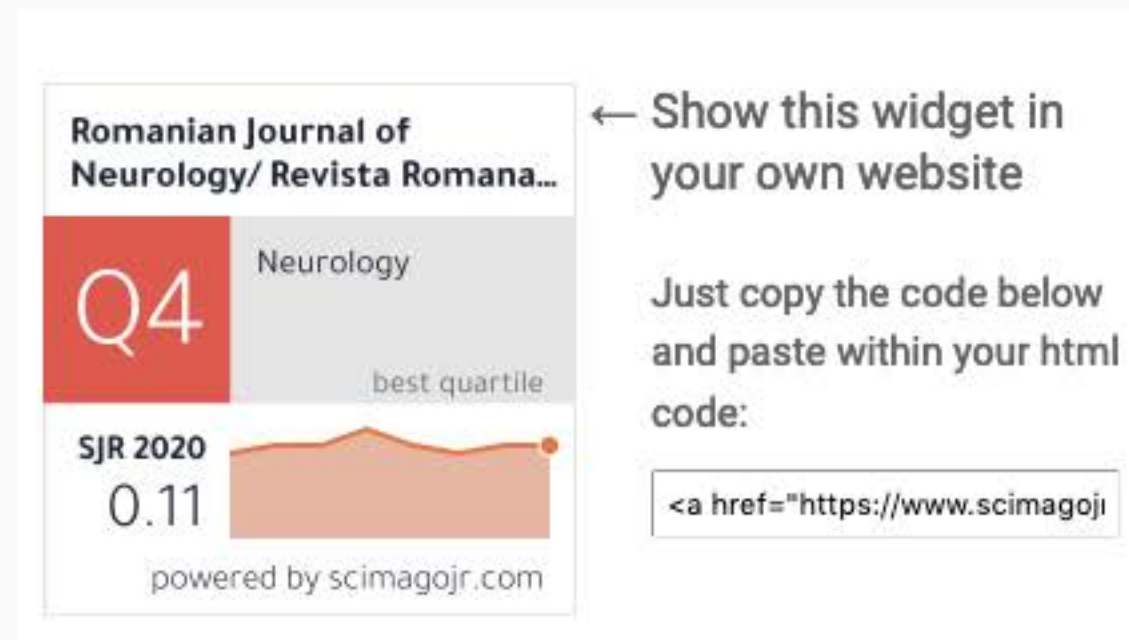
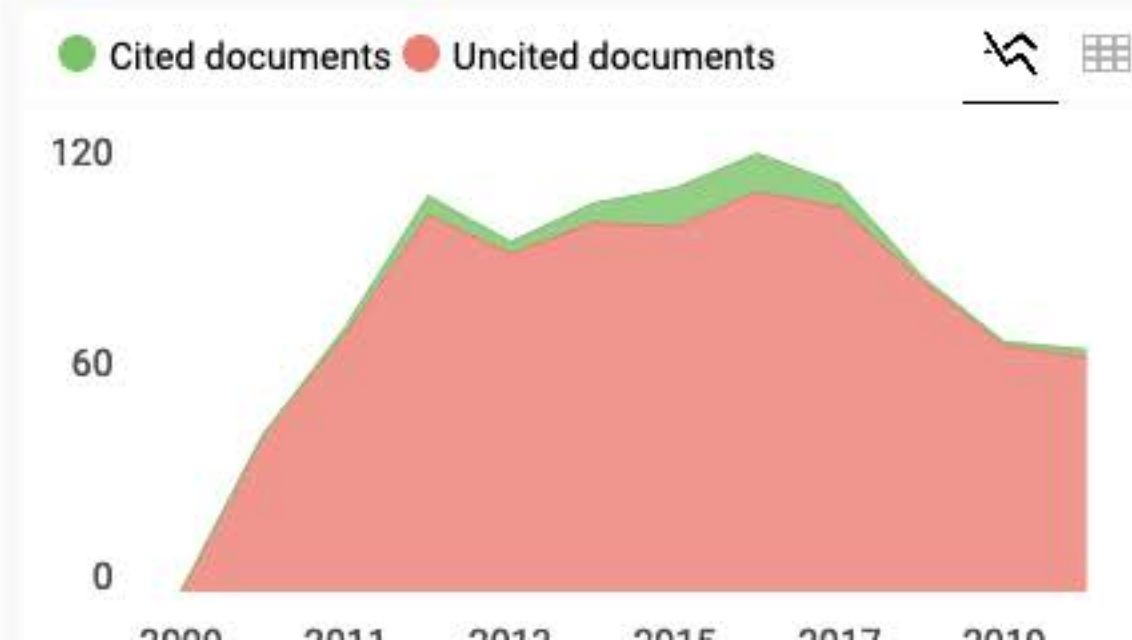
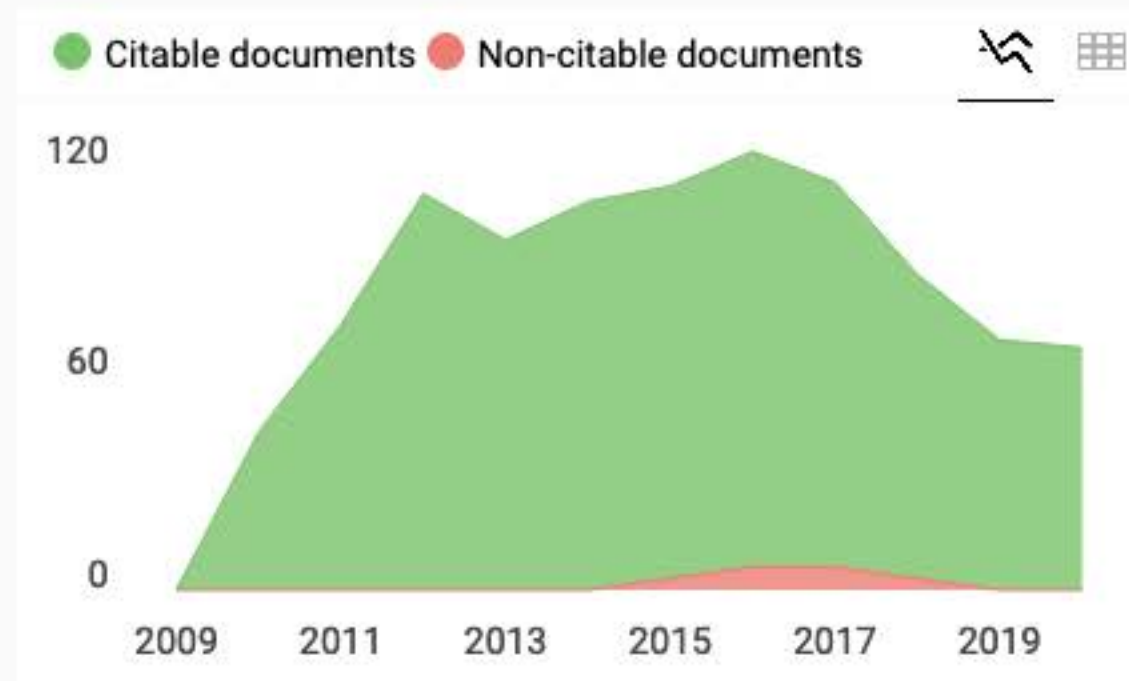
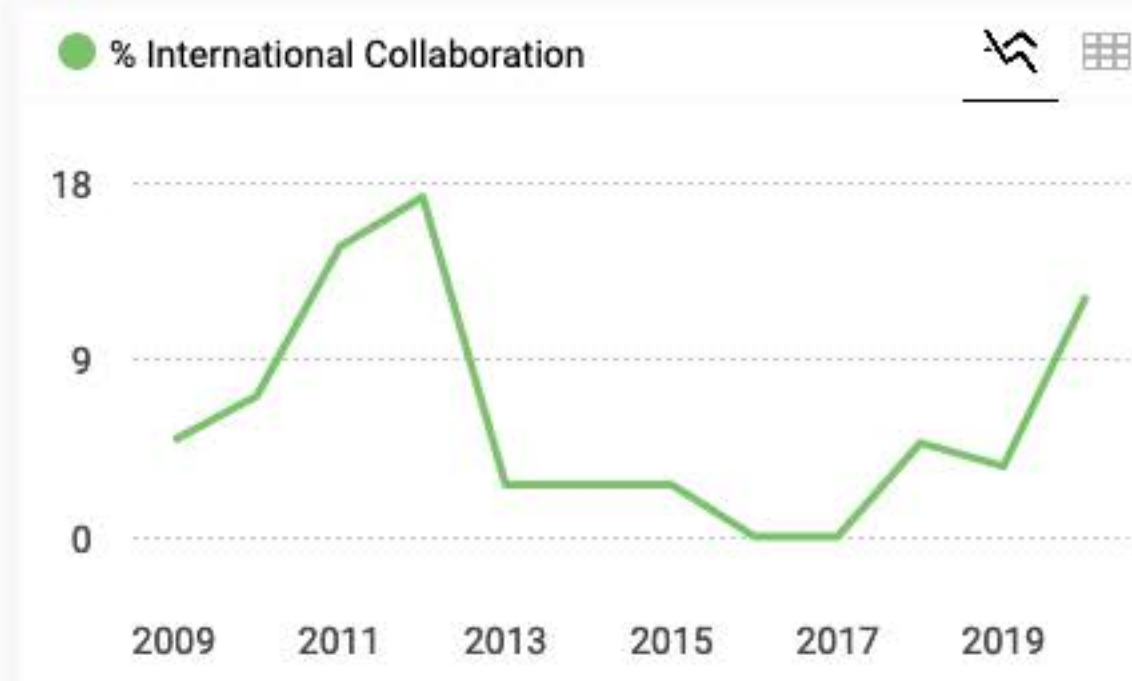
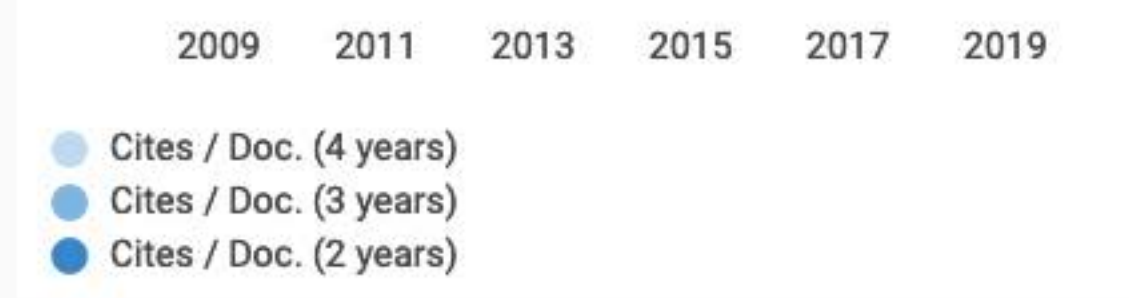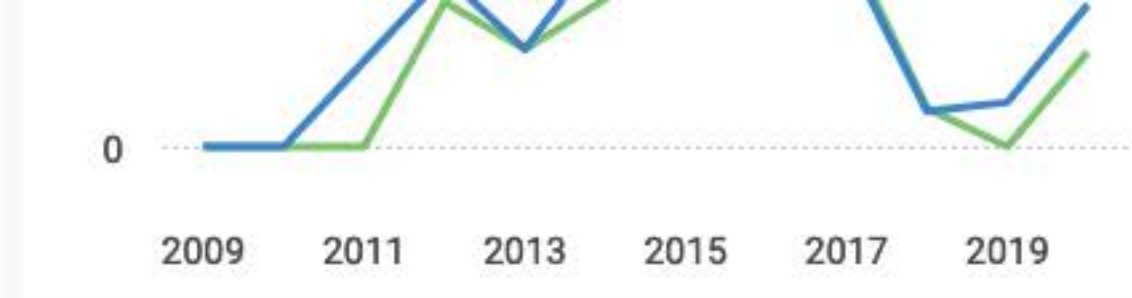<div>COUNTRY</div> <div>Romania</div> <div> Universities and research institutions in Romania</div>	<div>SUBJECT AREA AND CATEGORY</div> <div>Medicine<ul style="list-style-type: none">Neurology (clinical)Neuroscience<ul style="list-style-type: none">Neurology</div>	<div>PUBLISHER</div> <div>Editura Medicala</div>
<div>H-INDEX</div> <div>4</div>	<div>PUBLICATION TYPE</div> <div>Journals</div>	<div>ISSN</div> <div>18438148, 20696094</div>

tojqi.net

OPEN









CONTENTS

REVIEWS

The safety of new oral anticoagulants for ischemic stroke and systemic embolism prevention in females with atrial fibrillation
High serum non-high-density lipoprotein and the risk of ischemic stroke: A systematic review
Genetic epilepsy with febrile seizures plus – an overview
Central post stroke pain: What are the new insights?

ORIGINAL ARTICLES

Diagnostic value of DWI-MRI for the detection of acute plaques in the relapse phase of multiple sclerosis
Risk factors for ischemic stroke in Bulgaria
The prevalence and associated factors of aspirin resistance among prophylactic aspirin users
Effect of mCIMT with and without interval on hand in patient suffering from stroke
Evaluation of effect of epidermal growth factor receptor and vascular endothelial growth factor overexpression in survival of patients with glioblastoma multiforme
A study of using manganese chloride (MnCl₂) solution as an alternative of contrast medium for iodine in computed tomography (CT) imaging
Frequency of cranio-autonomic symptoms in the patients of migraine presenting in an outpatient department of Dow University Hospital: A cross-sectional study
Pediatric traumatic brain injury in Zimbabwe: A prospective cohort study
The effect of multisensory stimulation on weight gain in premature infants admitted to the intensive care unit: A clinical trial study

CASE REPORTS

SARS-CoV-2 in pre-existing autoimmune myasthenia gravis: An institutional experience
Young patient's secondary prevention in ischemic stroke with the percutaneous closure of the patent foramen ovale and postoperative permeabilisation – case report
An arachnoid cyst you don't see every day
Single cervical spinal extramedullary tuberculous lesion in a young female – case report

LETTER TO EDITOR

Lacunar stroke in COVID-19
Tackling Parkinson's disease amid COVID-19 pandemic: Pakistan's perspective
Multifocal motor neuropathy in idiopathic non-cirrhotic portal hypertension



<https://RJN.com.ro>

ISSN 1843-8148
e-ISSN 2069-6094
ISSN-L 1843-8148



9 771843 078006



AMALTEA
Medical Publishing House



AIMS & SCOPE

STANDARDS

EDITORIAL COUNCIL

PEER-REVIEW COUNCIL


EMC | CME

HOW TO

SUBSCRIBE

SELECT ISSUE

Select



ISSN 1843-8148 | e-ISSN 2069-6094

ISSN-L 1843-8148

DOI: 10.37897/RJN

AIMS AND SCOPE

ROMANIAN JOURNAL OF NEUROLOGY | REVISTA ROMÂNĂ DE NEUROLOGIE

Afilire | Affiliation:

Societatea de Neurologie din România | Romanian Society of Neurology

Denumire pentru indexare | Indexing name: Ro J Neurol.

Publisher: Editura Medicală Amaltea - România | Amaltea Medical Publishing House - Romania

Afilire internațională editură | Publisher's international affiliation: Elsevier (2008)

ISSN: 1843-8148

eISSN: 2069-6094

ISSN-L: 1843-8148

Grad CNCS/CNCSIS | CNCS/CNCSIS Rank: Categoria B+ | B+ Category

Cod CNCS/CNCSIS: 768

Indexată BDI | Indexed in international databases (EBSCO, Scirus, Wame)

Frecvența de apariție | Publication Frequency: 4 numere pe an, plus suplimente / 4 issues per year, plus supplements

Creditare Colegiul Medicilor din România (CMR) | Accreditation of College of Romanian Physicians: 10 credite EMC*/abonament | 10 CME* credits/subscription; 80 credite EMC*/articol | 80 CME* credits/paper

* EMC (educație medicală continuă) | CME (continuing medical education)

Revista Română de Neurologie, revista oficială a Societății de Neurologie din România, este fondată în 2001, fiind o publicație științifică de prestigiu care asigură o calitate deosebită din punctul de vedere al conținutului științific, dar

SEARCH

Search Keyword

Search Authors

STANDARDS

Instructions for AUTHORS

Peer-review protocol

Submit article

Submit your article to the journal by using the form here:

Submit

Subscriptions

To receive the **Ro Journal of NEUROLOGY** click here:

SUBSCRIBE





AIMS & SCOPE

STANDARDS

EDITORIAL COUNCIL

PEER-REVIEW COUNCIL

EMC | CME

HOW TO

SUBSCRIBE

SELECT ISSUE

Select



ISSN 1843-8148 | e-ISSN 2069-6094

ISSN-L 1843-8148

DOI: 10.37897/RJN

Editorial Council

in extenso version

Honorary Founding Editor

† Ovidiu Alexandru BAJENARU – *Bucharest, Romania*

Editor-in-Chief

Bogdan Ovidiu POPESCU – *Bucharest, Romania*

Scientific Associate Editor

Dafin Fior MURESANU – *Cluj-Napoca, Romania*

President of Romanian Society of Neurology

Bogdan Ovidiu POPESCU – *Bucharest, Romania*

EDITORIAL BOARD

Florina ANTOCHI – *Bucharest, Romania*

Natan BORNSTEIN – *Tel-Aviv, Israel*

Vivian DRORY – *Tel-Aviv, Israel*

Jelena DRULOVIC – *Belgrade, Serbia*

† Franz GERSTENBRAND – *Vienna, Austria*

Wolfgang GRISOLD – *Vienna, Austria*

Carolina IONETE – *Worcester, USA*

Pavel KALVACH – *Prague, Czech Republic*

Amos KORCZYN – *Tel-Aviv, Israel*

Vladimir KOSTIC – *Belgrade, Serbia*

SEARCH

Search Keyword

Search Authors

STANDARDS

Instructions for AUTHORS

Peer-review protocol

Submit article

Submit your article to the journal by using the form here:

Submit

Subscriptions

To receive the **Ro Journal of NEUROLOGY** click here:

SUBSCRIBE





Indexată BDI | IDB Indexed

DOAJ

DIRECTORY OF
OPEN ACCESS
JOURNALS

EBSCO
HOST

Medline

EBSCO search



Scopus



Crossref

HIGHLIGHTS

Plagiatul – în actualitate

Tema plagiatului este tot mai mult discutată în ultima vreme. Apariția unor programe performante de căutare și identificare a similitudinilor între texte [...]

Committee on Publication Ethics

A forum for responsible and ethical research publishing – Code of Conduct and Best Practice Guidelines for Journal Editors.

Vladimir KOSTIC – *Belgrade, Serbia*

Ioannis MILONAS – *Thessaloniki, Greece*

Ioana MINDRUTA – *Bucharest, Romania*

Cristina PANEA – *Bucharest, Romania*

Cristian FALUP-PECURARIU – *Brasov, Romania*

Lacramioara PERJU-DUMBRAVA – *Cluj-Napoca, Romania*

Daniel PIRICI – *Craiova, Romania*

Zvezdan PIRTOSEK – *Ljubljana, Slovenia*

Constantin POPA – *Bucharest, Romania*

† Cristian Dinu POPESCU – *Iasi, Romania*

Maja RELJA – *Zagreb, Croatia*

Alexandru SERBANESCU – *Bucharest, Romania*

Mihaela SIMU – *Timisoara, Romania*

Aksel SIVA – *Istanbul, Turkey*

Cristina TIU – *Bucharest, Romania*

Emil TOESCU – *Birmingham, UK*

Valeria TUDORICA – *Craiova, Romania*

Laszlo VECSEI – *Szeged, Hungary*

Secretary of Assistant Editors office

Mihai VASILE – *Bucharest, Romania*

Assistant Editors

Laura Cristina CEAFFALAN – *Bucharest, Romania*

Irene DAVIDESCU – *Bucharest, Romania*

Laura DUMITRESCU – *Bucharest, Romania*

Athena Cristina MERGEANI – *Bucharest, Romania*

Florina MOLDOVAN – *Cluj-Napoca, Romania*

Horia NICOLAE – *Bucharest, Romania*

Alexandra OPRISAN – *Bucharest, Romania*

Cecilia ROSCA – *Timisoara, Romania*

Elena Terecoasa – *Bucharest, Romania*

Managing Editor

Mihai-Cristian POPESCU – *Bucharest, Romania*



Partners

MERCK

TEVA



GEDEON RICHTER
NEUROLOGIE





AIMS & SCOPE

STANDARDS

EDITORIAL COUNCIL

PEER-REVIEW COUNCIL

EMC | CME

HOW TO

SUBSCRIBE

SELECT ISSUE

RJN Vol. XX, No. 2, Year 2021



ISSN 1843-8148 | e-ISSN 2069-6094

ISSN-L 1843-8148

DOI: 10.37897/RJN

Indexată BDI | IDB Indexed

CONTENTS

REVIEWS

Citicoline as a suggested novel adjuvant for painful diabetic polyneuropathy

Dico Gunawijaya, I Putu Eka Widyadharma, Ida Ayu Sri Wijayanti

[full text] — Ref: Ro J Neurol. 2021;20(2). DOI: 10.37897/RJN.2021.2.1

What is new in Dravet syndrome?

Lucia M. Sur, Remus Gaga, Gabriel Samasca, Cornel Aldea, Genel Sur, Iulia Lupan

[full text] — Ref: Ro J Neurol. 2021;20(2). DOI: 10.37897/RJN.2021.2.2

Cerebral and systemic endothelial dysfunction in migraine: Current knowledge and perspective

I Made Oka Adnyana, Valentina Tjandra Dewi

[full text] — Ref: Ro J Neurol. 2021;20(2). DOI: 10.37897/RJN.2021.2.3

Effectiveness of interventions in patients with speech disorders. A meta-analysis of experimental studies

Camelia Daniela Cucu, Florinda Golu, Andreea Raluca Adam

[full text] — Ref: Ro J Neurol. 2021;20(2). DOI: 10.37897/RJN.2021.2.4

ORIGINAL ARTICLES

The effectiveness of mirror therapy with repetitions on lower extremity motor recovery, balance and mobility in patients with stroke

Kritika Verma, Jaspreet Kaur, Manoj Malik, Neerja Thukral

[full text] — Ref: Ro J Neurol. 2021;20(2). DOI: 10.37897/RJN.2021.2.5

Volume XX, No. 2, 2021

Current Issue

SEARCH

Search Keyword

Search Authors

STANDARDS

Instructions for AUTHORS

Peer-review protocol

Submit article

Submit your article to the journal by using the form here:

Submit

Subscriptions

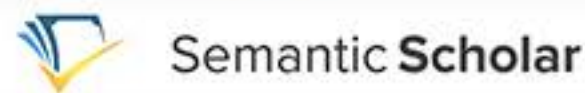To receive the **Ro Journal of NEUROLOGY** click here:

SUBSCRIBE





Similarity Check by iThenticate, world leading professional plagiarism checking system



HIGHLIGHTS

Plagiatur – în actualitate

Tema plagiatului este tot mai mult discutată în ultima vreme. Apariția unor programe performante de căutare și identificare a similitudinilor între texte [...]

Committee on Publication Ethics

A forum for responsible and ethical research publishing – Code of Conduct and Best Practice Guidelines for Journal Editors.

Value of P300 as a screening tool of cognitive impairment in epilepsy: A prospective study from India

Amandeep Singh, Ajoy Kumar Sodani, Dinesh Chouksey, Rahul Jain

[full text] — Ref: Ro J Neurol. 2021;20(2). DOI: 10.37897/RJN.2021.2.6

Trigger factors associated with migraine headache among Northern Iranian population

Negar Gorjizadeh, Saeed Irian, Ansar Karimian, Payam Saadat

[full text] — Ref: Ro J Neurol. 2021;20(2). DOI: 10.37897/RJN.2021.2.7

Proportions and characteristics of patients with brain abscess at Sanglah General Hospital in Denpasar, Bali, Indonesia in 2019-2020

Putu Satyakumara Upadhana, Ni Putu Kostarika Melia Daradila, Anak Agung Bagus Putra Indrakusuma, I Gede Krisna Arim Sadeva, Putri Ayu Wulandari, I Putu Eka Widyadharma

[full text] — Ref: Ro J Neurol. 2021;20(2). DOI: 10.37897/RJN.2021.2.8

Assessment of association of demographic characteristics, diet and disease with haemorrhagic stroke and factors causing stroke leading to cerebral haemorrhage in male patients in Quetta Balochistan, Pakistan

Anila Alam, Musa Bin Bashir, Mirwais Khan, Asad Khan, Safiullah Khan Acahakzai

[full text] — Ref: Ro J Neurol. 2021;20(2). DOI: 10.37897/RJN.2021.2.9

Spectrum of clinical and FDG-PET patterns of patients with frontotemporal dementia (FTD) in a tertiary care hospital

Sundar Shanmugam, P. Philo Hazeena, Vamsi Chalasani, Arindam Ghosh, Shankar Venkatasubramanian, Venkatachalapathy Easwaramoorthy

[full text] — Ref: Ro J Neurol. 2021;20(2). DOI: 10.37897/RJN.2021.2.10

8-year experience with ataxia telangiectasia: A series of 7 cases

Nicole Villagaray-Pacheco, Kelly Franco-Bustamante, Wilmer Córdova-Calderón

[full text] — Ref: Ro J Neurol. 2021;20(2). DOI: 10.37897/RJN.2021.2.11

A retrospective cohort study on the risk factors of gastrointestinal bleeding in acute ischemic stroke patients with atrial fibrillation

Rizaldy Taslim Pinzon, Carmelia Anggraini

[full text] — Ref: Ro J Neurol. 2021;20(2). DOI: 10.37897/RJN.2021.2.12

Efficacy of combined immunotherapy with Propes and Inflamafertin in selective deficiency of NK and NKT cells in children with autism spectrum disorders associated



Partners

MERCK

TEVA



GEDEON RICHTER
NEUROLOGIE



with genetic deficiency of the folate cycle*Dmitry Maltsev, Volodymyr Stefanyshyn**[full text] — Ref: Ro J Neurol. 2021;20(2). DOI: 10.37897/RJN.2021.2.13***Impact of the COVID-19 pandemic on psychological health status during lockdown period: A cross-sectional study***Sonu Punia, Mohini, Shailja Sharma, Varun Singh, Shabnam Joshi**[full text] — Ref: Ro J Neurol. 2021;20(2). DOI: 10.37897/RJN.2021.2.14***Chronic neurological disease as a independent risk factor for death in severe COVID-19 cases***Elena Caires Silveira**[full text] — Ref: Ro J Neurol. 2021;20(2). DOI: 10.37897/RJN.2021.2.15***Knowledge, attitude and implementation of evidence-based practice of physiotherapists in India: A web-based cross-sectional study***Rekha Chaturvedi, Shaveta Khrolia, Vandana Yadav, Meenakshi Bagri, Jyoti**[full text] — Ref: Ro J Neurol. 2021;20(2). DOI: 10.37897/RJN.2021.2.16*

CASE REPORTS

Transient ischemic attack as the initial presentation of Takayasu arteritis in a young woman: A case report*Dren Boshnjaku, Fisnik Jashari, Bujar Gjokolli, Edmond Komoni, Melihate Pushka, Argjend Shala, Vera Kukaj, Nexhmedin Shala**[full text] — Ref: Ro J Neurol. 2021;20(2). DOI: 10.37897/RJN.2021.2.17***A rare case of extradural thoracic spinal chordoma with medullary compression and literature review***A. Ene, I.E. Petre, A.N. Dabu**[full text] — Ref: Ro J Neurol. 2021;20(2). DOI: 10.37897/RJN.2021.2.18***Myasthenia gravis in pregnancy: a rare association with an unpredictable evolution – three cases presentation***Benjilany Aboubakr, Kouach Jaouad**[full text] — Ref: Ro J Neurol. 2021;20(2). DOI: 10.37897/RJN.2021.2.19***Lumbar radiculopathy managed with spinal mobilization with leg movement: A case study**

*A. Ene, I.E. Petre, A.N. Dabu**[full text]* — Ref: Ro J Neurol. 2021;20(2). DOI: 10.37897/RJN.2021.2.18**Myasthenia gravis in pregnancy: a rare association with an unpredictable evolution – three cases presentation***Benjilany Aboubakr, Kouach Jaouad**[full text]* — Ref: Ro J Neurol. 2021;20(2). DOI: 10.37897/RJN.2021.2.19**Lumbar radiculopathy managed with spinal mobilization with leg movement: A case study***Varun Singh, Manoj Malik**[full text]* — Ref: Ro J Neurol. 2021;20(2). DOI: 10.37897/RJN.2021.2.20**The evaluation of unilateral closed-lip schizencephaly on complex MRI sequences***Emrah Doğan**[full text]* — Ref: Ro J Neurol. 2021;20(2). DOI: 10.37897/RJN.2021.2.21**Transverse myelitis following COVID-19 infection. What is the mechanism? A case report and literature review***Babak Alijani, Alia Saberi, Parham Niyasti, Mohamad Haghani Dogahe**[full text]* — Ref: Ro J Neurol. 2021;20(2). DOI: 10.37897/RJN.2021.2.22**The challenging diagnosis of dysferlinopathy – a case report***Claudiu Gabriel Socoliuc, Alexandra Oprişan, Amelia Dobrescu, Emilia Manole, Alexandra Eugenia Bastian**[full text]* — Ref: Ro J Neurol. 2021;20(2). DOI: 10.37897/RJN.2021.2.23**LETTER TO EDITOR****Role of intracranial CSF and brain volume in clinical outcome of stroke patients***B.V. Murlimanju, Rakesh Mishra, Luis Rafael Moscote-Salazar, Amit Agrawal**[full text]* — Ref: Ro J Neurol. 2021;20(2). DOI: 10.37897/RJN.2021.2.24

editor@rjn.com.ro

Subscribe to the Newsletter

Articles from the journal are licensed under a
Creative Commons Attribution 4.0 International License[Terms & Conditions](#)[Open Access Statement](#)

Publisher : AMALTEA Medical Publishing House



PROPORTIONS AND CHARACTERISTICS OF PATIENTS WITH BRAIN ABSCESS AT SANGLAH GENERAL HOSPITAL IN DENPASAR, BALI, INDONESIA IN 2019-2020

Putu Satyakumara Upadhana¹, Ni Putu Kostarika Melia Daradila¹,
Anak Agung Bagus Putra Indrakusuma¹, I Gede Krisna Arim Sadeva¹,
Putri Ayu Wulandari¹, I Putu Eka Widyadharma²

¹*Bachelor of Medicine and Medical Profession Study Program, Faculty of Medicine, Udayana University, Denpasar, Bali, Indonesia,*

²*Departments of Neurology, Faculty of Medicine, Udayana University, Denpasar, Bali, Indonesia*

ABSTRACT

Introduction. A brain abscess is a collection of pus, immune cells, and other materials that are generally caused by bacterial or fungal infection in the brain parenchyma. This disease has a high level of morbidity and mortality, nonetheless, until now there has been no in-depth research on this disease, especially in Bali.

Objective. This study aimed to determine the proportion and characteristics of patients with brain abscess at the Sanglah General Hospital, Denpasar, Bali, Indonesia in 2019-2020.

Material and methods. This study is an observational study with a cross sectional method. A total of 41 patients with brain abscesses recorded in hospital medical records in 2019-2020 were included in this study. Univariate analysis was performed to obtain the characteristics of patients with brain abscesses.

Results. Most of the patients were male (63.4%), aged 20-39 years. The main complaint most often found in patients was decreased consciousness (56.1%), with neurological symptoms in the form of hemiparesis (32.3%). Most of the abscesses were found on the right frontal, right parietal and left parietal with a percentage of 14.06% each. The CT scan results showed a rim contrast enhancement (63.4%), cerebral edema (75.6%), and normal sulcus gyri (51.2%). Up to 50% of patients with a history of surgical procedures underwent a craniotomy. Other disease histories most often found in patients were sinusitis (29.5%), diabetes mellitus (15.3%), and toxoplasmosis (12.5%).

Conclusion. There are varying results of the clinical characteristics of patients with brain abscesses, and indicate the natural course of this disease.

Keywords: brain abscess, patient's characteristics, CT scan

INTRODUCTION

Central nervous system (CNS) infection is one of the main sources of morbidity today. The presence of new, broader spectrum antibiotics as well as improved clinical imaging technology and intensive care facilities has changed the history of previous CNS infection management. It is known that the brain does not have its own immune system but the blood brain barrier is predominantly immune to infection. However, it is not uncommon for these infections to cause serious illness in the body. Brain abscess is one of the serious dis-

eases that affect the CNS (1). A brain abscess is a collection of pus, immune cells, and other materials commonly caused by bacterial or fungal infection in the brain parenchyma. When a part of the brain becomes infected through blood or directly, it becomes swollen and inflamed. Infected brain cells, white blood cells, live and dead bacteria, or fungi collect in this area of the brain. The surrounding tissue will form a mass (abscess) (2-5). Often the source of infection is not found, but the most common source is infection of the lungs and rarely occurs from heart infection. Several factors

Corresponding author:

I Putu Eka Widyadharma

E-mail: eka.widyadharma@unud.ac.id

Article history:

Received: 19 April 2021

Accepted: 19 June 2021

can increase the risk of developing a brain abscess, including a weak immune system (HIV / AIDS patients), a history of chronic diseases such as cancer, taking immunosuppressants (corticosteroids or chemotherapy), and congenital heart disease (2).

Undiagnosed or untreated brain abscess has very high morbidity and mortality. Brain abscess morbidity reaches 46% with a mortality rate of 13.58%. Complications caused by brain abscess include septicemia, neurological deficits, meningitis, ventriculitis, intracranial vascular thrombosis, brain herniation, seizures, and increased intracranial pressure (2,6,7). Brain abscess has a higher prevalence in developing countries than in developed countries. This is due to differences in socio-economic conditions that occur in these countries (8). Indonesia has reported several cases of brain abscess, but there is no definite national data (9). Each region has its own characteristics of patients so that it requires different management.

The need for science encourages research on certain health issues. To determine the characteristics of a patient with a brain abscess, data is needed to describe this.

MATERIAL AND METHODS

This research is a descriptive observational study with a cross sectional approach to determine the proportion and characteristics of patients with brain abscesses at Sanglah General Hospital in 2019-2020. This research was conducted at Sanglah General Hospital Denpasar by taking secondary data from the Medical Record Installation. The population in this study were all patients with brain abscesses who were registered at the Sanglah General Hospital Medical Record Installation, Denpasar, Bali. The sampling technique used in this study was total sampling technique. Subjects taken from the population were those who met the inclusion criteria, namely medical record data that show that the patients had been diagnosed with brain abscess by doctors at Sanglah General Hospital Denpasar in 2019-2020, and were in accordance with the research variables, and did not meet the exclusion criteria in the form of incomplete medical record data of patients with brain abscess disease at Sanglah General Hospital Denpasar in 2019-2020.

This research has received permission from the Research Ethics Commission of Udayana Medical Faculty/Sanglah Hospital Denpasar number 2110/UN14.2.2.VII.14/LT/2020.

RESULTS

Table 1 shows the demographic characteristics of patients. Most of the patients were male (n = 26, 63.4%).

TABLE 1. Demographic characteristics of patients

Sociodemographic Characteristics		N	%
Gender	Male	26	63.4
	Female	15	36.6
Total		41	100.0
Age	20-39 Years	16	39.0
	40-59 Years	16	39.0
	> 60 Years	9	22.0
Total		41	100.0

The main complaints of the patient are shown in Table 2. Most of the patients had the main complaints in the form of decreased consciousness (n = 23, 56.1%), weakness of half of the body (n = 8, 19.5%) and headache (n = 6, 14.6%).

TABLE 2. Main complaints of patients

Main complaints		N	%
Main complaints	Decrease in awareness	23	56.1
	headache	6	14.6
	Hemiparesis	8	19.5
	Seizures	1	2.4
	Vomiting	1	2.4
	Slurred speech	2	4.9
Total		41	100.0

Data regarding the results of vital signs examination on patients can be seen in Table 3. Most of the patients have blood pressure, respiratory rate and pulse rate, and body temperature within normal limits. Patients also have a fairly mild pain intensity.

TABLE 3. Vital signs of patients

Vital signs	Mean	Median
Systolic blood pressure	124.39 mmHg	120.0 mmHg
Diastolic blood pressure	77.68 mmHg	80.00 mmHg
Respiratory rate	21.53x/minute	20.00x/minute
Pulse	84.14x/minute	84.00x/minute
Body temperature	36.79 C	36.50 C
GCS	12.31	14.00
Pain scale	1.34	1.00

Neurological symptoms found in patients are shown in Table 4. Most of the patients had neuro-

logical symptoms in the form of hemiparesis ($n = 33$, 32.3%), 7 nerve paresis ($n = 25$, 24.5%), and Babinski's sign ($n = 15$, 23.0%).

TABLE 4. Neurological symptoms

Neurological symptoms		N	%
Neurological symptoms	Hemiparesis	33	2.3
	Diparesis	3	2.9
	Stiff neck	4	3.9
	Cephalgia	11	10.7
	Nerve paresis 3	1	0.9
	Nerve paresis 6	1	0.9
	Nerve paresis 7	25	24.5
	Nerve paresis 12	8	7.8
	Babinski	15	23.0
	Seizure	1	0.9

Table 5 shows the location of the abscess found in the patient. In general, most abscesses were in the right hemisphere ($n = 38$, 59.4%). Specifically, the abscess locations were found mostly on the right frontal ($n = 9$, 14.06%), right parietal ($n = 9$, 14.06%), and left parietal ($n = 9$, 14.06%).

TABLE 5. Location of patient's brain abscess

Abscess location	N	%
Right temporal	6	9.40
Left temporal	3	4.70
Right frontal	9	14.06
Left frontal	6	9.40
Right occipital	2	3.13
Left occipital	2	3.13
Right parietal	9	14.06
Left parietal	9	14.06
Right cerebellum	2	3.13
Right ventricle	1	1.56
Left ventricle	1	1.56
Left thalamus	1	1.56
Right tempo parietal	4	6.20
Right tempo occipital	1	1.56
Left tempo occipital	1	1.56
Right front occipital	1	1.56
Right frontotemporal	1	1.56
Left frontotemporal	1	1.56
Left frontoparietal	2	3.13
Right temporoparietal occipital	1	1.56
Right front temporoparietal	1	1.56

Results of patients' CT scan of can be seen in Table 6. Most of the patient's CT scan results showed a rim of contrast enhancement ($n = 26$, 63.4%), cerebral edema ($n = 31$, 75.6%), and normal sulcus gyri ($n = 21$, 51.2%). Meanwhile, only a small proportion of patients showed leptomeningeal enhancement ($n = 7$, 17.1%) and a calcification ($n = 2$, 4.8%).

History of surgical procedures in patients is shown in **Table 7**. There were 8 patients with a history of surgical procedures, and 4 of them with a history of craniotomy.

TABLE 6. Other CT scan examination results on patients

Ct scan examination		N	%
Rim contrast enhancement	Exist	26	63.4
	None	15	36.6
Total		41	100.0
Leptomeningeal enhancement	Exist	7	17.1
	None	34	82.9
Total		41	100.0
Edema cerebri	Exist	31	75.6
	None	10	24.4
Total		41	100.0
Scalp	Normal	40	97.5
	Not normal	1	2.5
Total		41	100.0
Sulcus gyri	Normal	21	51.2
	Move closer	16	39.0
	Narrowed	4	9.8
Total		41	100.0
Midline deviation	Exist	14	34.1
	None	27	65.9
Total		41	100.0
Calcification	Exist	2	4.8
	None	39	95.2
Total		41	100.0
Pons	Normal	40	97.5
	Not Normal	1	2.5
Total		41	100.0
Cerebellum	Normal	40	97.5
	Not normal	1	2.5
Total		41	100.0
Calvaria	Normal	41	100.0
	Not normal	0	0.0
Total		41	100.0
Basis cranii	Normal	41	100.0
	Not normal	0	0.0
Total		41	100.0
Herniation	Exist	6	17.1
	None	35	82.9
Total		41	100.0

TABLE 7. History of surgical procedures in patients

Surgical procedures	N	%
Craniotomy	4	50
Vp shunt	1	12.5
Abscess trepanation	1	12.5
Pus aspiration	1	12.5
Resection	1	12.5

Data related to the history of other patients is shown in Table 8. Sinusitis is the most common medical history in patients ($n = 21$, 29.5%), followed by diabetes mellitus ($n = 11$, 15.3%) and toxoplasmosis ($n = 9$, 12.5%).

DISCUSSION

Patients with brain abscess in this study were dominated by men. This is in line with the prevalence data which stated that brain abscess patients

TABLE 8. History of other diseases in patients

Other diseases		N	%
Other diseases	Toxoplasmosis	9	12.5
	HIV	8	11.1
	Diabetes mellitus	11	15.3
	Hydrocephalus	3	4.2
	Meningitis	4	5.5
	Brain tumor	2	2.7
	Kidney failure	2	2.7
	Hypertension	3	4.2
	COVID-19	2	2.7
	SLE	1	1.4
	UTI	1	1.4
	Ear infection	2	2.7
	Heart disease	1	1.4
	TB	2	2.7
	Sinusitis	21	29.5
Total		72	100.0

are more dominant in men than women with a ratio varying between 2:1 and 3:1. In addition, there is no significant relationship between geographic and seasonal differences with the prevalence of brain abscess. Brain abscess accounts for a disproportionate percentage of intracranial lesions in developing countries compared to developed countries (10,11).

The age characteristics in this study are also in line with the data which stated that the age range of brain abscess patients ranges from 24 to 57 years. The average age of onset is higher in developed than developing countries. This relationship is not yet clearly defined, but may be related to reduced immune conditions in the elderly as well as greater life expectancy and lower rates of traumatic brain injury in younger individuals in developed countries (12).

The main complaint most often experienced by patients in this study was a decrease in the level of consciousness by 23 people (56.1%), followed by half-body weakness (hemiplegia), headache, slurred speech, seizures, and vomiting. This clinical manifestation is in accordance with the research conducted by Patel and Clifford, but in that study the most common sign was headache.

The clinical manifestations of brain abscess vary and are not specific depending on the location, size, stage and number of lesions, bacterial malignancy, degree of brain edema, the patient's response to infection, and the patient's age. If the progression of the abscess continued, the complaints would be more clearly seen in the patient. There is a classic triad showing brain abscesses, namely fever, headache, and decreased level of fo-

cal consciousness, but recent reports suggest that this constellation only occurs in a small proportion of cases (5,12,13).

Based on the results of the study, Table 3 shows the data regarding the status of vital signs of Sanglah General Hospital patients, Denpasar for the period 2019-2020 with parameters in the form of mean and mean values. The values for blood pressure (systolic and diastolic), pulse rate, and body temperature are known to be within the normal range. An increase in the respiratory rate from the normal range (18-20x/min) can be caused by an infection-related condition (14). These results are also directly proportional to previous case studies which reported a similar condition in the form of an increase in respiratory rate of 28x/minute, especially in the condition of *Streptococcus sp.* (15). The decrease in the mean GCS is known to be in a state of apathy (12,13). A similar reduction was also found in previous studies where 42% of the total patients had GCS status < 14 (16). Recent retrospective studies also showed similar results, with 48.14% of the total patients having a GCS status < 14 and associated with a poor prognosis (17). The study by Landriel et al. reported a median GCS of 15 patients with the condition that 79.6% of patients were on GCS 14-15 and only two patients had GCS < 8 (18). The study by Zhang et al. reported that 13.33% of patients had GCS < 13 during the admission process of a total of 60 patients (19). The study by Helweg-Larsen et al. reported that 77% of patients had a GCS of 12-15, 10% had a GCS of 8-11, and 9% had a GCS of < 8 of a total of 102 patients (6). There is also another study which reported that 11.53% of the total patients had GCS < 8 (20). Another study also reported altered consciousness and neurological deficits in 43% and 48% of total patients, respectively (21). GCS values are also known to influence the clinical outcome of the intracranial surgery caused by bacterial infection (22). Decreased GCS and mental state are associated with a poor prognosis for bacterial brain abscess (12). Pain assessment has a mean of 1.34 with a susceptible value of 1-10. Pain characteristics are generally localized to the area around the lesion with a gradual or sudden onset. Pain sensation is also generally not decreased with pain-reducing drugs (5).

Based on the results of the study, table 4 shows that the highest neurological symptom experienced

by patients of brain abscess at Sanglah General Hospital Denpasar in 2019 was hemiparesis, which was 33 people (32.3%) while the lowest neurological symptom experienced by patients was seizures by 1 person (0.9%). There is a case report which stated that a man with a brain abscess found evidence of right sided dysarthria and hemiparesis (23). The results of this study are also in line with studies conducted by Chang et al., with the same results, namely that the most common clinical manifestation found is hemiparesis, followed by fever, altered consciousness, headache, septic shock, and the least common is seizure (24). However, the results of this study are not in line with the results obtained by Hsu et al., who stated that the least clinical manifestation found was hemiparesis. This is probably due to differences in the number of patients who were used as subjects, differences in demographics, and locations where the study was conducted (25).

The location of infection in a brain abscess can vary, but the most common intracranial sites are the frontal – parietal, frontal – temporal, cerebellum, occipital and parietal lobes (26). The location of the brain abscess is closely related to the cause of the infection. Autogenic abscesses are more common in the temporal lobe and cerebellum, whereas abscesses due to sinus infections are predominantly frontal (12). Brain abscess is known to occur more frequently in the left hemisphere than in the right hemisphere for which the cause is not clearly defined (26,27).

Based on the results of the study, Table 6 shows the data on the results of CT scans in patients. CT scan can be used for early detection, locale, characteristics, determination of the number, size and stage of the abscess quickly so that it is very helpful in planning treatment and further action. The results of the CT scan of patients with brain abscesses in Sanglah General Hospital in 2019-2020 showed that more cases were not accompanied by a hernia (82.9% of people), this is in line with a previous analysis by Muzumdar et al., of 289 cases of pyogenic abscess in Seth. GS Medical College and King Edward VII Memorial Hospital, Mumbai, India during a period of 7 years (1999-2006) there were 3 out of 289 patients who died came in a coma with transtentorial herniation (28).

Imaging findings depend on the stage of the lesion. Brain abscess cases are common with rim-en-

hancing lesions with either CT or MRI. Rim-enhancing is typically thin (2-7 mm), convex in shape, and has fine outer and inner margins. In this study, more were found of rim contrast enhancement (63.4% of patients). Research by Britt et al. reported that the CT findings in early-stage cerebrum were unevenly elevated and subsequently progressed to rim-enhancing in advanced cerebrum which subsequently formed brain abscesses (36).

In this study, leptomeningeal enhancement was only found in 7 patients (17.1%). Leptomeningeal enhancement is usually followed by meningitis and meningoencephalitis caused by viruses, bacteria, or fungi. Leptomeningeal enhancement is an increase in pia-arachnoid which will then fill the subarachnoid space of the sulcus and water tank and will then describe “gyriform” or “serpentine”. Sulcus gyri in patients in this study were dominated by normal conditions (51.2% of people) (28). The study of Bokhari and Mesfin reported (65%) a change in mental state of lethargy to coma is an indication of the occurrence of cerebral edema and a poor prognosis. CT examination of an advanced abscess shows a progressive decrease in edema and mass due to steroid administration (2).

Based on the results of the study, Table 7 shows the data regarding the history of the management of surgical procedures in patients. Surgical procedures generally aim to reduce pressure (decompression) in the area of the lesion, reduce intracranial pressure, and eradicate the presence of both primary and secondary infection (29). The craniotomy procedure had the highest prevalence found in four patients or by 50% with other procedures, namely VP shunt, abscess trepanation, pus aspiration, and resection each having a prevalence of 12.5%. In previous studies, a craniotomy was generally required for a traumatic brain abscess to remove foreign bodies or residual bone. Craniotomy with excision is generally performed when the abscess does not respond to pus aspiration (29). The study by Tan et al. used a total of 51 cases of brain abscess patients with therapeutic characteristics in the form of craniectomy accompanied by excision (54.9% of patients) and aspiration (45.1% of patients), and results in the form of improved neurological function and better radiological clearance and significant decreased rates of re-surgery ($p < 0.05$) in the craniotomy group compared to aspira-

tion without any significant differences in mortality and morbidity between the two treatment groups (30). Another retrospective study reported that at least 53% of patients with primary brain abscess underwent a craniotomy procedure (5). A recent study by Makwana et al. reported that 72% of patients underwent craniotomy and 28% of patients underwent aspiration (31). Pus aspiration is a safe and relatively easy procedure that generally results in a rapid drop in intracranial pressure while identifying the causal organism. Research by Gadgil et al. reported that 27% of patients receiving open aspiration by excision had the highest prevalence of 67% of patients (16). Research by Zhang et al., at the General Hospital of Tianjin Medical University, during the period 1952-2014, reported that 253 patients received aspiration, 211 excisions, and 92 received both out of a total of 620 patients (32). Previous studies also reported that as many as 60% of patients used the aspiration method (stereotactically guided aspiration) and 30% received craniotomy from a total of 60 patients (19). Another study also showed results similar to stereotactically guided aspiration were accepted in 74.6% of patients, while 25.4% of patients received craniotomy (19). Study by Helweg-Larsen et al. at the Rigshospitalet University Hospital reported that 67% of patients received aspiration, 20% received a craniotomy, and 13% did not receive surgery (antibiotics only) from a total of 102 patients (6).

Based on the results of the study, Table 8 shows that the history of medical treatment and other disease history experienced by brain abscess patients at Sanglah General Hospital Denpasar in 2019-2020 was sinusitis, which was 21 people (29.5%), followed by diabetes mellitus in 11 people (15.3%)

with a history of medical action and other diseases, the lowest was systemic lupus erythematosus (SLE), urinary tract infections (UTI), and heart disease in 1 person (1.4%) each. This is in accordance with previous references which stated that important risk factors for brain abscess are diabetes mellitus, liver cirrhosis, malignancy, malnutrition, and immunosuppression (23,34). The results of this study are also in line with Ong et al., who stated that the most frequently found history of other diseases in brain abscess patients is lung disease, diabetes mellitus, hypertension, and hepatitis (35).

CONCLUSIONS

The proportion of patients with brain abscesses in Sanglah General Hospital in 2019-2020 was 41 people. Characteristics of patients with brain abscesses at Sanglah General Hospital based on socio-demographic data are dominantly male, commonly occurred in the age range < 60 years, the main complaint experienced was a decrease in the level of consciousness, vital signs were mostly included in the normal range, neurological symptoms that often appeared were hemiparesis, followed by nerve paresis 7, and nerve paresis 12, the parietal area both right and left and right frontal area are were most common locations for abscesses, from the results of CT scans Patients often showed rim enhancement and edema cerebri, craniectomy is the most commonly performed surgical procedure for people with brain abscesses. Patients also have a history of other diseases including sinusitis, diabetes mellitus, toxoplasma and HIV.

REFERENCES

1. Muzumdar D. Central nervous system infections and the neurosurgeon: a perspective. *Int J Surg*. 2011;9(2):113-6.
2. Bokhari MR, Mesfin FB. Brain Abscess. [Updated 2020 Jun 30]. In: StatPearls [Internet]. Treasure Island (FL): StatPearls Publishing; 2021. Available at: <https://www.ncbi.nlm.nih.gov/books/NBK441841/>.
3. Chen M, Low DCY, Low SYY, Muzumdar D, Seow WT. Management of brain abscesses: where are we now? *Childs Nerv Syst*. 2018 Oct;34(10):1871-1880.
4. Widdrington JD, Bond H, Schwab U, Price DA, Schmid ML, McCarron B, Chadwick DR, Narayanan M, Williams J, Ong E. Pyogenic brain abscess and subdural empyema: presentation, management, and factors predicting outcome. *Infection*. 2018 Dec;46(6):785-792.
5. Lange N, Berndt M, Jörger AK, Wagner A, Wantia N, Lummel N, Ryang YM, Meyer B, Gempt J. Clinical characteristics and course of primary brain abscess. *Acta Neurochir (Wien)*. 2018 Oct; 160(10):2055-2062.
6. Helweg-Larsen J, Astradsson A, Richhall H, Erdal J, Laursen A, Brennum J. Pyogenic brain abscess, a 15 year survey. *BMC Infect Dis*. 2012 Nov 30;12:332.
7. Chowdhury FH, Haque MR, Sarkar MH, Chowdhury SMNK, Hossain Z, Ranjan S. Brain abscess: surgical experiences of 162 cases. *Neuroimmunol Neuroinflammation* 2015;2:153-161.
8. Nathoo N, Nadvi SS, Narotam PK, van Dellen JR. Brain abscess: management and outcome analysis of a computed tomography era

- experience with 973 patients. *World Neurosurg.* 2011 May-Jun; 75(5-6):716-26.
9. Samatra P. Abses Serebri. In: The 6th Bali Neurology Update 2018 Tropical Disease and Neuropediatric Cases: Revisiting (Re)-Emerging Issues with National Priorities. Udayana University Press; 2018.
 10. Gorji GRS, Rassouli M, Staji H. Prevalence of cerebral toxoplasmosis among slaughtered sheep in Semnan, Iran. *Ann Parasitol.* 2018;64(1):37-42.
 11. Maher G, Beniwal M, Bahubali V, Biswas S, Bevinahalli N, Srinivas D, Siddaiah N. Streptococcus plurianimalium: Emerging Animal Streptococcal Species as Causative Agent of Human Brain Abscess. *World Neurosurg.* 2018 Jul;115:208-212.
 12. Patel K, Clifford DB. Bacterial brain abscess. *Neurohospitalist.* 2014 Oct;4(4):196-204.
 13. Zumla A, Mandell, Douglas, and Bennett's principles and practice of infectious diseases. *Lancet Infect Dis.* 2010 May;10(5):303-4.
 14. Minelli E, Sassun TE, Papi M, Palmieri V, Palermo F, Perini G, Antonelli M, Gianni F, Maulucci G, Ciasca G, De Spirito M. Nanoscale mechanics of brain abscess: An atomic force microscopy study. *Micron.* 2018 Oct;113:34-40.
 15. Belodu R, S N, R R, Kumar R, B A C. A pneumococcal brain abscess: a case report. *J Clin Diagn Res.* 2013 Aug;7(8):1694-5.
 16. Gadgil N, Patel AJ, Gopinath SP. Open craniotomy for brain abscess: A forgotten experience? *Surg Neurol Int.* 2013 Mar 25;4:34.
 17. Asquier-Khati A, Deschanvres C, Boutoille D, Lefebvre M, et al.; Nantes Brain Abscesses study group. Switch from parenteral to oral antibiotics for brain abscesses: a retrospective cohort study of 109 patients. *J Antimicrob Chemother.* 2020 Oct 1;75(10):3062-3066.
 18. Landriel F, Ajler P, Hem S, Bendersky D, Goldschmidt E, Garategui L, Vecchi E, Konsol O, Carrizo A. Supratentorial and infratentorial brain abscesses: surgical treatment, complications and outcomes--a 10-year single-center study. *Acta Neurochir (Wien).* 2012 May;154(5):903-11.
 19. Chiu TH, Haliza G, Lin YH, Hung TH, Hsu JJ, Hsieh TT, Lo LM. A retrospective study on the course and outcome of fetal ventriculomegaly. *Taiwan J Obstet Gynecol.* 2014 Jun;53(2):170-7.
 20. Radoi M, Ciubotaru V, Tataranu L. Brain abscesses: clinical experience and outcome of 52 consecutive cases. *Chirurgia (Bucur).* 2013 Mar-Apr;108(2):215-25.
 21. Brouwer MC, Coutinho JM, van de Beek D. Clinical characteristics and outcome of brain abscess: systematic review and meta-analysis. *Neurology.* 2014 Mar 4;82(9):806-13.
 22. Idowu OE, Majekodunmi AA. Relationship between demography, etiology, level of consciousness, and outcome of surgical intracranial suppurations of bacterial origin in a tropical tertiary center. *Asian J Neurosurg.* 2016 Jan-Mar;11(1):41-5.
 23. Hernandez Jimenez JM, Vahdat K, Serrano Santiago IA, Morales Hernandez MDM, Isache CL, Sands M. Thalamic bacterial abscess presenting with hemiparesis and expressive aphasia. *IDCases.* 2018 Jun 28;13:e00417.
 24. Chang YT, Lu CH, Chuang MJ, Huang CR, Chuang YC, Tsai NW, Chen SF, Chang CC, Chang WN. Supratentorial deep-seated bacterial brain abscess in adults: clinical characteristics and therapeutic outcomes. *Acta Neurol Taiwan.* 2010 Sep;19(3):178-83.
 25. Hsu CW, Lu CH, Chuang MJ, Huang CR, Chuang YC, Tsai NW, Chen SF, Chang CC, Chang WN. Cerebellar bacterial brain abscess: report of eight cases. *Acta Neurol Taiwan.* 2011 Mar;20(1):47-52.
 26. Brook I. Microbiology and treatment of brain abscess. *J Clin Neurosci.* 2017 Apr;38:8-12.
 27. Lu CH, Chang WN, Lin YC, Tsai NW, Liliang PC, Su TM, Rau CS, Tsai YD, Liang CL, Chang CJ, Lee PY, Chang HW, Wu JJ. Bacterial brain abscess: microbiological features, epidemiological trends and therapeutic outcomes. *QJM.* 2002 Aug;95(8):501-9.
 28. Muzumdar D, Jhawar S, Goel A. Brain abscess: an overview. *Int J Surg.* 2011;9(2):136-44.
 29. Alvis Miranda H, Castellar-Leones SM, Elzain MA, Moscote-Salazar LR. Brain abscess: Current management. *J Neurosci Rural Pract.* 2013 Aug;4(Suppl 1):S67-81.
 30. Tan WM, Adnan JS, Mohamad Haspani MS. Treatment outcome of superficial cerebral abscess: an analysis of two surgical methods. *Malays J Med Sci.* 2010 Jan;17(1):23-9.
 31. Makwana M, Merola JP, Bhatti I, Patel CK, Leach PA. Towards improved outcome in children treated surgically for spontaneous intracranial suppuration in South Wales. *Br J Neurosurg.* 2021 Jan 11:1-4.
 32. Zhang Z, Cai X, Li J, Kang X, Wang H, Zhang L, et al. Retrospective analysis of 620 cases of brain abscess in Chinese patients in a single center over a 62-year period. *Acta Neurochir (Wien).* 2016 Apr;158(4):733-739.
 33. Landriel F, Ajler P, Hem S, Bendersky D, Goldschmidt E, Garategui L, Vecchi E, Konsol O, Carrizo A. Supratentorial and infratentorial brain abscesses: surgical treatment, complications and outcomes--a 10-year single-center study. *Acta Neurochir (Wien).* 2012 May;154(5):903-11.
 34. Karageorgiou I, Chandler C, Whyte MB. Silent diabetes mellitus, periodontitis and a new case of thalamic abscess. *BMJ Case Rep.* 2014 Jul 21;2014:bcr2014204654.
 35. Ong CT, Tsai CF, Wong YS, Chen SC. Epidemiology of brain abscess in Taiwan: A 14-year population-based cohort study. *PLoS One.* 2017 May 9;12(5):e0176705.
 36. Britt RH, Enzmann DR, Yeager AS. Neuropathological and computerized tomographic findings in experimental brain abscess. *J Neurosurg.* 1981 Oct;55(4):590-603.